J 54

No. 926/H



THE INSTITUTE OF OPHTHALMOLOGY
LONDON

EX LIBRIS

110
3cd

B4 1



OPHTHALMOLOGY HE367 KNAPP

A

TREATISE

ON

INTRAOCULAR TUMORS.

FROM

ORIGINAL CLINICAL OBSERVATIONS AND ANATOMICAL INVESTIGATIONS.

(WITH ONE CHROMO-LITHOGRAPHIC AND FIFTEEN LITHOGRAPHIC PLATES, CONTAINING VERY MANY FIGURES)

BY

H. KNAPP, M.D.,

LATE PROFESSOR OF OPHTHALMOLOGY, AND SURGEON TO THE OPHTHALMIC HOSPITAL IN HEIDELBERG.

TRANSLATED BY

S. COLE, M.D., OF CHICAGO.

NEW YORK:
WILLIAM WOOD & CO., 61 WALKER STREET.
1869.

Entered according to Act of Congress, in the year 1869. by
WILLIAM WOOD & CO.,
In the Clerk's Office of the District Court of the United States for the Southern District of New York.

The New York Printing Company,
81, 83, *and* 85 *Centre Street*,
New York.

THAL MIC
HOSPITAL

CONTENTS.

PAGE

PREFACE vii

PREFACE TO THE ENGLISH EDITION xi

INTRODUCTION 17

PART 1.

ON GLIOMA (ENCEPHALOID) OF THE RETINA.

SECTION I.

Report of Cases.

CASE I.—Glioma of both retinæ, without extension to the optic nerve. Metastasis to the liver and diploë of the bones of the cranium. 23

CASE II.—Unilateral glioma of the retina, with extension to the optic nerve and cerebrum 51

CASE III.—Glioma without perforation, completely filling the interior of the eye 60

CASE IV.—Unilateral glioma with rupture of the selerotic 61

CASE V.—Bilateral glioma of the retina; on the right side probably congenital, with rupture of the eyeball and proliferous growth into the orbit; beginning glioma on the left side 67

CASE VI.—Eye gliomatously degenerated, with perforation through the cornea. Extension of the glioma to the optic nerve, chiasma, pia mater cerebralis and spinalis, cerebrum and cerebellum, and roots of the spinal nerves 72

CASE VII.—Unilateral glioma with perforation through the cornea; recurrence and lateral extension to the glands 79

SECTION II.

General Description of Glioma of the Retina.

PAGE

I. Pathological anatomy of glioma of the retina..... 86

II. Origin, progress, and termination of retinal glioma..... 88

III. Symptomatology of retinal glioma..... 103

IV. Occurrence of retinal glioma..... 108

V. Diagnosis of glioma of the retina..... 111

VI. Prognosis of glioma of the retina..... 117

VII. Treatment..... 119

PART 2.

SARCOMA OF THE CHOROID.

SECTION I.

Description of Cases.

Case VIII.—Melano-sarcoma of the choroid, ciliary body, and iris..... 125

Case IX.—Melano-sarcoma of the ciliary body and the choroid, with perforation in the ciliary region of the sclerotic..... 135

Case X.—Melano-sarcoma of the choroid and ciliary body, with perforation through the sclerotic. Death one half-year after the extirpation, caused by metastasis to the liver, kidneys, and lungs..... 144

Case XI.—Melanotic glio-sarcoma, with double perforation of the sclerotic..... 154

Case XII.—Melanotic sarcoma, with perforation of the sclerotic; relapses after extirpation. Death caused by metastasis to the internal organs. Autopsy..... 163

Case XIII.—Unpigmented, simple choroidal sarcoma of spindle-shaped cells. Recovery by enucleatio bulbi in the stage of glaucomatous inflammation..... 175

PAGE

Case XIV.—White, vascular (teleangiectatic) sarcoma of the choroid. Recovery after enucleatio bulbi..... 184

Case XV.—Inflammatory fibromatous sarcoma of the choroid; enucleation of the globe; recovery..... 203

SECTION II.

General Description of Choroidal Sarcoma.

I.—*Pathological Anatomy of Choroidal Sarcoma.*

A. Macroscopical condition..... 208

B. Minute structure of developed sarcoma..... 210

C. Varieties of choroidal sarcoma..... 222

D. Origin and development of choroidal sarcoma..... 228

E. Seat and extension of choroidal sarcoma..... 235

II.—*Clinical Description of Choroidal Sarcoma.*

A. Symptoms and progress of choroidal sarcoma..... 240

B. Diagnosis of choroidal sarcoma..... 249

Case XVI.—Detachment of ciliary body and adjoining choroid from sclerotic..... 261

Case XVII.—Detachment of hyaloid membrane from retina..... 269

C. Etiology of sarcoma of the choroid..... 273

D. Prognosis of sarcoma of the choroid..... 275

E. Treatment of choroidal sarcoma..... 283

APPENDIX.

NOTES ON OTHER FORMS OF TUMOR OCCURRING IN THE EYEBALL.

1. Sarcoma carcinomatosum..... 287

2. Sarcoma of the iris..... 289

a. White sarcoma of the iris..... 289

b. Melano-sarcoma of the iris..... 290

PAGE

3. Myo-sarcoma of the ciliary body 291
4. Vascular (teleangiectatic) tumor (angioma) of the iris..... 292
5. Syphilitic tumors (gummata) of the iris..... 293
6. Tubercles of the choroid..... 294
7. Lipomatous tumor of the iris..... 295
8. Cysts in the iris..... 295
9. Simple melanoma (pigment tumor) of the iris..... 298
10. Simple granulation tumors (granuloma)..... 300

Explanation of the figures..... 304

PREFACE.

I HAVE been induced by two reasons to study more minutely the subject of the present treatise: (1) Because the diseases here spoken of are perfeetly harmless and masked in their earliest stages, but on further growth become so horrible and destrnctive to the patient and those about him, that they awaken, of themselves, the highest sympathy of the physician; and (2) because I am convinced that intraocular tumors especially are destined to throw light upon many general questions of fundamental significanee for the theories and therapeutics of tumors in general.

If we endeavor to trace—and this is certainly most important—the primary germs in the development of tumors, there is no place in the whole body more adapted to this than the interior of the eyeball. The retina is the most sensitive interpreter of pathologieal processes. The slightest disturbance of the same drives the anxious patient immediately to the physician, whilst on other portions of the body, even when they are accessible to the senses of sight and toneh (as, for instanee, the mammary gland in women), tumors generally arrive at a considerable size before they beeome manifest to the patient and physieian.

The methods, of late so perfected, of testing the power of sight, and the use of the ophthalmoseope and other physical instruments, whereby we lay the interior of the eye, in perfeet distinetness and considerably magnified, open to our view, permit us not only to make an early diagnosis, but also narrowly to watch the growth of all kinds of pseudoplasmas in the interior of the eye,

which, previous to Helmholtz's immortal discovery, was hidden in deepest darkness.

As regards the *therapeutical* measures, all agree in the assertion that the *curative effect* of operations on tumors is *dependent on the early and complete extirpation.* Both requirements are, at the present day, remarkably well attained by intraocular tumors. The early diagnosis which can be made justifies us in extirpating the eye in the first stage of the neoplasma, whilst the compact and indolent fibrous capsule of the eyeball protects the neighboring soft parts long and effectually; consequently we are enabled to carry out the total extirpation with more certainty here than in any other portion of the body. Furthermore, we at present possess in *Enucleatio bulbi* an innocent procedure when compared to the grave operation formerly praetised, of extirpation of the eyeball together with the adjoining tissues.

Consequently, if we are able to reach a pathologieal proeess in an earlier stage of development, therefore nearer the roots, we prove that science has advaneed a step further. The following pages will show that we are able to remove intraocular tumors not only *nearer the roots* than formerly, but also in many eases *with the roots.*

It must be our task, with united strength, to take up new means and views, and with them pursue the clinieal and anatomical study of intraocular tumors, and to eontinue our investigations with a depth, perseverance, and precision corresponding to the spirit of science at the present day.

It is of importanee constantly to refine the diagnosis of intraocular tumors, to extirpate as soon as possible, to determine the anatomical structure of the tumor in all its relations, and to follow the clinical eourse of the case as long as possible. If, together with all this, we also make preeise and minute memoranda, we will treasure up, in the eourse of years, material enough to decide from exact observations the eontroversy of eenturies:

Do the tumors which we term malignant have an innocent primary stage, that is, are they at first local affections which afterward infect the whole organism, or are their first germs already the products of a (tumor-forming) dyscrasy previously present in the system?

I know of no field which would be more fruitful in yielding strong arguments for the solution of this important question, than the intraocular tumors. It would be a magnificent reward for my labors if the present pages would contribute to incite my colleagues to further and more minute investigation of this subject in which, as in several others, ophthalmology seems destined to lead the other branches of the healing art.

That such observations may prove more advantageous we, of course, are in need of the co-operation of our colleagues in general, especially of practitioners and professional anatomo-pathologists.

I must thankfully acknowledge that I was repeatedly favored by their assistance, as is mentioned at several places in the body of the work; especially were the hours spent in common labor with my excellent colleague and friend, Prof. *J. Arnold*, as pleasant as they were instructive.

H. KNAPP, M.D.

HEIDELBERG, Spring of 1868.

PREFACE TO THE ENGLISH EDITION.

Soon after the completion of the German edition of this book, the 3d part of Vol. XIV. of the "Archiv für Ophthalmologie" was published, and contained some important articles on intra-ocular tumors.

In the first, Dr. *J. Hirschberg* describes the anatomical conditions of eight cases of *Glioma Retinæ*, which he observed in *Von Graefe's* clinique. One of these cases is particularly remarkable, as it exhibits an early stage of development of retinal glioma which originated chiefly in the inner layer of granules.

In the second article, *Von Graefe* gives a very interesting *summary of his extensive experience on Tumors within the Eye.* His highly instructive remarks can be only of the greatest benefit to the reader. I myself was exceedingly gratified to find that the views of the great ophthalmologist of Berlin were more closely allied to mine than I could have anticipated from his former publications, and the discussions in relation to a paper of mine read in the International Congress of Oculists at Paris in the autumn of 1867.

In a third article of the "Arch. f. Ophth." Dr. *Th. Leber* describes a fine specimen of *Cavernous Sarcoma of the Choroid.*

The English translation of the present book has been made by my former pupil, Dr. S. Cole, *of Chicago*, who, at the time I was working at the subject, was a most industrious student of my clinical and didactic lectures at the Ophthalmic Hospital in Heidelberg. He not only saw most of my anatomical prepara-

tions, but observed some of the cases described even during life. He is therefore thoroughly conversant with the subject, a circumstance no less indispensable for a good translator than a perfect knowledge of both languages.

I have availed myself of the very latest literature in making the few additions necessary to complete the subject spoken of in the Appendix. Moreover, I have inserted the histories of two sarcoma cases operated on by *J. W. Hulke* in previous years with favorable results. These notes, which *Dr. Hulke* has kindly given to me, are valuable arguments in regard to the question of the prognosis of choroidal sarcoma.

On my recent voyage through Germany, France, and England to America, I received the impression everywhere that great attention is now paid to the subject of intraocular tumors. Thus it is to be expected that many a question, actually beyond the reach of individual effort, will soon be settled by persistent and combined labor.

H. KNAPP, M.D.

New York, April, 1869.

INTRODUCTION.

As tumors in general have at all periods fixed the attention of the thinking members of our profession, *Intraocular* Tumors claim the closest scrutiny of oculists, especially of those who, in the practical pursuit of their specialty, never lose sight of its connection with General Medicine. How many ties indissolubly bind Ophthalmology to General Medicine and Surgery, can scarcely be better demonstrated than by the history of *Tumors* encountered in and about the eye.

Although our organ of vision, with the immediate neighboring parts, furnishes a favorable ground for the growth of the most different forms of tumors, the variety of these in the globe itself proves, on close inspection, to be rather limited. Certainly, if we examine the long lists which, in ancient and modern literature, are devoted to the names of Ocular Tumors, we feel disposed to believe in a great variety. Yet the cause of this does not lie so much in the subject itself as in the diversity of its conception by different writers. For many years have I been engaged in observing and collecting the appropriate cases which had presented themselves rather frequently amongst the clinical material at my disposal,

and if I were to rely only upon the results which I have obtained from my *own* observation, ocular tumors would hardly admit of more than two varieties, viz.: *Glioma*, originating in the *retina;* and *Sarcoma*, proceeding from the *choroid*, and being in part *unpigmented* and in part *melanotic*.

When of long duration, especially in recidives after extirpation and in metastases, *glioma* may become sarcomatous and perhaps carcinomatous, and primary *sarcoma* may also become carcinomatous. Of these two types of tumor I have clinically observed and anatomically examined a number of cases, of which I shall first give a detailed report and then draw a general picture of the disease, both of glioma and sarcoma, to which the several cases will furnish the foundation and confirmation.

In the description of disease there is no other test for correctness than the observation of cases. The truer to nature and the more careful this is, the more distinct will be the picture of the disease, the clearer will be our comprehension of processes of morbid activity, and the more certain and useful our treatment. The researches before us are the results of my own experience during the last five years. All the cases of intraocular tumor which I operated and observed in this interval are comprised in them. I do not presume that all the forms really occurring are represented by the fifteen cases thus collected, still they form (as the attentive reader will no doubt discover) a series not altogether incomplete or disconnected; so that I felt justified in venturing beyond the separate observations, and in giving a general descrip-

tion from these groups of morbid processes. In so doing, I have not neglected to refer to medical literature, partly in order to fill deficiencies, and partly to strengthen ancient experience by more modern research and more exact investigation, and in part also to correct error. The last, however, will not form a conspicuous feature of this treatise; for wherever I recognized a former description as undoubtedly erroneous, especially when the more correct was substituted from another quarter, I have in general simply ignored it, in order not to add a refutation of my own. Since, in my practice, only glioma and sarcoma have occurred as intraocular tumors, and since I purpose to draw conclusions from my own material alone, the description of the researches under consideration is limited to these two groups of disease. That other varieties of tumor (especially carcinoma) may arise in the eye, I am far from denying; nevertheless I may add that in the more detailed descriptions contained in medical literature, to the present date, I did not find any convincing instance. Only a few brief remarks of *Virchow* confirm the existence of true carcinoma in the eyeball. My conception and description proceed from a purely anatomical stand-point, and seek their model in the excellent and classical investigations of *Virchow*. If the theoretical views of this eminent investigator, as well as those of all others, are peculiar and subjected to the change of time, certainly his analyses and descriptions of actual forms of disease have an imperishable worth, for they are perfectly true to nature. Science, as it progresses, will at some future day go

beyond the discoveries of *Virchow*, but will not overthrow his positive results; on the contrary, will employ them as foundations for future developments. Science does not lean for support upon *one* name, but is carried by hundreds. If I only mention *Virchow* in this connection, it is not from disregard to the many other earlier and contemporary investigators, but I merely intend to show that I consider him the person whose profound and extensive works have advanced and enriched our knowledge of pathological occurrences more than those of any other observer before him. Aside from this, everybody knows how reformatory his views of the processes of the organism have acted upon the medicine of the present day. In how much his classical work "On Morbid Tumors" has impelled me to make the following detailed observations, I can no longer affirm; still, for the manner and way of examination, it was decisive and authoritative. I have adopted the nomenclature of *Virchow* (despite a few innovations, which perhaps will not outlive the next ten years), because I consider it more precise and explicit than any before it. Thus, the word carcinoma is employed only in its pure anatomical signification and limitation, and not to the extent in which it is used by so many practitioners, who make the idea of cancer identical with malignancy.

Most examples of intraocular cancer which are mentioned in medical literature, particularly the English, I could comprise without trouble under glioma and sarcoma, and wherever I was not successful, the description was so deficient that *no other* explanation could be given.

I am prepared to see these views meet with opposition, but I can only be pleased if they induce my colleagues to correct them by more exact investigations.

Finally, I wish to remark that I have purposely abstained from indulging in theoretical speculations, alluring as they were in many instances.

I did not here assign myself the task of assisting in the solution of fundamental problems, but of studying a subject of great practical importance as carefully as the limitation of my material, time, and abilities would allow me.

Part 1.

ON GLIOMA (ENCEPHALOID) OF THE RETINA.

SECTION I.

REPORTS OF CASES.

Case I.—*Glioma of both Retinæ, without extension to the Optic Nerve. Metastasis to the Liver, Lungs, and Diploë of the Bones of the Cranium.*

On the 4th of November, 1865, there was brought to my clinique a child of eighteen weeks, named Barbara Kob, of Heppenheim, whose right eye was totally blind, and whose left still retained so much power of vision as to follow the light in all directions. In the pupil of the right eye, the parents had already, soon after the birth of the child, observed a yellowish, glimmering reflection, which during the latter weeks had grown duller, the sclerotic at the same time becoming covered with blood-vessels of considerable size. At the time of her introduction to the clinique I found the *anterior chamber* of the right eye very shallow, the *iris* of a dirty gray color, and the *pupil* oval, wide, and rigid. Behind the transparent lens, and apparently close to its posterior surface, there appeared, by reflected light, a fundus of a dull yellow color.

This eye was not manifestly enlarged, more tense than normal, free from pain on touch, and perfectly movable. Over the sclerotic there passed an increased number of thickened and tortuous blood-vessels of a dark red color.

The eye, after being enucleated and opened, was laid in Müller's fluid (Potass. Bichromat. 2 to 3 grammes, Sod. Sulphat. 1 gramme, Aq. destill. 100 grammes), and examined long after, but in a perfectly preserved and nicely hardened condition. For this examination only one-half was employed ; the other, completely untouched, being added to my collection.

Macroscopical Examination.

The globe of the eye, vertically divided exactly through the middle of the optic nerve, was 19 Mm. in breadth and 20 Mm. in depth. Close on the normal *sclerotic* rested the apparently normal *choroid;* the *lens* and *iris* being crowded forward toward the cornea. The *optic nerve* did not present any remarkable change, but the *retina*, in nearly its entire extent, was detached, yet in such a manner that its attachments to the ora serrata and optic nerve were still preserved. The retina itself was pushed toward the axis of the eye until the internal surface of one side lay in contact with that of the other, so that the interior of the globe was divided into two symmetrical halves by a duplicated, vertical, retinal septum (Fig. 1, a). From its attachment to the ora serrata, the retina was crowded so far forward that it rested on the ciliary processes and the posterior surface of the lens (Fig. 1, b). With a needle it could be raised without offering

resistance. The two adjoining sides of the retina which together formed the upright septum (a) could, without difficulty and uninjured, be separated from each other. On the retina itself, two circumscribed tumors were situated, one (c) of the size of a pea, the other (d) of a bean. Their intimate connection with, and direct transition into, the retina rendered it evident that they proceeded from the retinal tissue itself, and especially from the outer layers, for the adjacent internal surfaces were even, smooth, and firm. The substance of the tumors was in most places soft and granular, although in others, as for instance, throughout the entire extent of the smaller (c), situated on the inner side, it was tough and glassy. On the temporal side of the *corona ciliaris* still a third, smaller tumor (about the size of a lentil), completely independent of the others, was seated (Fig. 1, e). This one also sprang from the external surface of the retina, for the forward-looking internal surface could be lifted smoothly from the zonula. The free surface of the larger tumor was rough and granular, yielding on pressure, and appeared to be composed only of the proliferous elements of the growth. The surfaces of the other tumors were smooth, unyielding, and seemingly covered with a thin membrane. Of the second largest the summit alone was softened, yellowish, and granular, as if the tumor had been macerated at this point. By turning it aside several others, of the size of millet and hemp seeds, and projecting from the encircling retina, could be brought to view. The space *between the choroid* and *the dislocated, tumor-beset retina was filled with a watery*,

slightly opaque fluid, which I had neglected to examine at the time of opening the eyeball.

On the remaining portions of the globe no change could be discovered.

Microscopical Examination.

The *optic nerve*, in its external appearance, presented nothing striking. Its shape and size were normal, from the place of its passage through the sclerotic to where it had been divided, 5 Mm. posteriorly. I made many longitudinal and transverse sections, but found everything in a healthy condition. The bundles of nerve-fibres were encompassed by a very abundant network of vessels, still richly filled with blood-globules. The intervening connective tissue, proceeding from the sheath of the optic nerve, was dense, and disposed in broad bands in the vicinity of the globe; further removed it became scarce, and arranged in slender strips, which were filled almost completely by the traversing blood-vessels, precisely as in the normal optic nerve. The *retina*, which was pressed forward from its retained attachment to the ora serrata, so far as to cover the ciliary processes and the posterior surface of the capsule of the lens, could plainly be recognized as such in its new position. Still, not a single section through it presented normal, conditions. The changes occurring here are represented in Fig. 2. The *limitans interna* (li) was normal, or only slightly thickened. The *stratum nervosum*, or fibrous layer (f), presented a few nerve-fibres in several places; in most, however, it was impossible to assert their existence. Their place was oc-

cupied by *small accumulated cells or granules, which were dotted in their interior and partly provided with manifest nuclei.* In the stratum gangliosum (gl) lay isolated, larger rounded cells, with large nuclei, which represented preserved ganglia, and whose interstices were filled with the small, round, dotted cells previously alluded to. On the *limitans interna*, thick-set and delicate filaments were inserted perpendicular to its surface. Several of these forced their way in a winding direction through the small cells. These filaments are to be regarded as the preserved radiating fibres of the retina (Fig. 2, f). The *gray or molecular* layer (gr) was considerably shrunken and very uniformly and minutely dotted. On this layer a few of the round elements of the granular layer had intruded, and had, in several places (a), pierced the gray layer itself, protruding into the ganglionic and fibrous layers. The two *granular* layers (ik, ak) were greatly enlarged, mostly at the expense of the intergranular layer (zk), which latter was dotted in its appearance, and contracted to a narrow, but everywhere plainly recognizable strip. In the *granular* layers, round dotted elements, differing in no manner from the normal granules, were situated; these did not lie very densely together, a small interspace, filled with a fine granular substance, separating the different granules. The radiating fibres, however, were but sparingly supplied in most places in the granular layers. In the *internal* they were almost entirely absent, and in the *external* only traces of their former presence were discoverable. The *limitans externa* (le) was preserved; the same can

be said of the columnar layer (st), whose elements, however, appeared more or less mutilated. In other places (Fig. 3, b^1) the whole retina had become granularly degenerated. Only its internal portion was bounded by a delicate fibrous membrane (Fig. 3, d) (*limitans interna*). Its entire thickness, however, was taken up by granules, which lay side by side as in the granular layers. The *limitans externa* was wanting in some places, and appeared again in others (Fig. 3, le) normally preserved. Near this completely degenerated retina, and situated upon the preserved limitans externa, a thin layer, corresponding to the columnar (Fig. 3, st), and composed wholly of larger and smaller granules and nuclei, could be seen. The result of this examination, therefore, demonstrated an increased growth of the *strata granulosa* at the expense of the other retinal layers. The intervening filamentous or intergranular layer was most of all reduced in size. This excessive increase of the granular layers manifested itself, in several places, by degrees, so that in the length of less than a millimeter their thickness was doubled (Fig. 4, ik and ak), whilst the fibrous and ganglionic (Fig. 4, a) layers were not remarkably thickened. In other places the augmented growth was more of a boss-like nature (Fig. 3, aa) ; the enlarged granular layers increased suddenly from double to five times their original size, and in this manner formed small elevations with bases twice the width of their height. On the bases of many of these smaller growths the several retinal layers were recognizable, though changed (Fig. 3). Between the external granular layer itself and the growth there

was a darker stripe, but of such an appearance that a direct transition of homogeneous elements from the external granular layer to the tumor could everywhere be observed. In other tumors the introgranular layer was demonstrable only at its border; and at their bases the molecular and fibrous layers were visible as two pretty narrow bands. But in the middle of the elevation the arrangement of the granules in rows diminished more and more until they lay in disorder near and above each other. This disposition was the *only* one in the larger tumors, and could be regarded as nothing else than an enlargement of their smaller neighbors, just described. On thinner sections (Fig. 3, a) the round cells had become dislocated from the elementary matter, and this, therefore, appeared in the hardened preparation as a finely granulated network, whose meshes were formed by the displacement of the cells; but wherever they were still present the elementary matter became less distinct than the round elements.

The investigation of the several forms of the growths afforded a *correct insight into the development of the whole degenerated mass. The originally diffuse hyperplasy of the granules* (Fig. 4) attains in different places an excessive development, *whereby the smaller and larger tumors* (Fig. 3, a), *which were either entirely devoid of retinal elements, or provided with them only at their bases*, originate.

Of the easily detached *choroid*, transverse sections were made, and thus a striking and marked *atrophy* of its tissue was rendered evident. Only the single

layer of the pigment epithelium (Fig. 5, aa) was preserved, it being from 8 to 10 μ* in thickness. The transverse sections of the other layers, on specimens from the region of the equator (Fig. 5, bb) of the globe, measured 14 μ,* so that the epithelial layer constituted one-third of the entire thickness of the choroid. The stroma contained neither pigmented nor unpigmented stellate cells, but was a homogeneous streaked membrane, only here and there traversed by blood-vessels (c), which latter were recognizable more by means of their contents, the well-preserved blood globules, than by their walls or coats. Moreover, the parallel striated structure was studded with fine points, which, lying side by side, were arranged in rows and small patches. I presume that these were only the transverse sections of filaments running in other directions.

In other places, transverse sections brought exceedingly remarkable relations of the choroid to view, viz.: in wholly circumscribed clusters, small, round, dotted cells (Fig. 6, a), which in no wise changed either the epithelium or the remains of the choroid, had accumulated between the raised epithelium and the shrunken choroid (ch) manifestly degenerated to connective tissue. I generally found that also on the external surface of the pigment epithelium, a few of the small cells had gathered (Fig. 6, b).

I then excised large pieces of the choroid, and spread them horizontally upon the object-glass, so that the pigmentary layer looked upward (Fig. 7). I now found in

* μ=(micra, micromillimeter)=0.001 mm.

several places a partial deficiency of the pigmentary layer, disposed in patches, as *Schweigger** also has observed and sketched. He explains this as follows: that in these places the rough tumor had pressed upon the choroid, and thereby caused the absorption of the epithelial layer. But I cannot consider this as merely an atrophy from pressure, for, firstly, the spots were present in several places where the tumor was widely separated from the choroid by a fluid; secondly, all the white spots were occupied by accumulations of glioma cells (Fig. 7, abc). Some of these were very small (Fig. 7, a), others considerably larger (bc); on many it could plainly be seen, in surface preparations, that the accumulation of cells extended further under the semitransparent epithelial covering (Fig. 7, d), a fact which I am unable to show so conclusively in a surface sketch as it presented itself to me with the assistance of the microscope.

In other places there lay on the inner surface of the choroid extensive layers of glioma cells, which had displaced the pigment cells and crowded them together into irregular rows. The picture under the microscope was (the comparison may appear extravagant to the reader) not unlike a glacier with moraines.

The *choroidal tissue* presented itself in different conditions throughout this process. In most places where proliferous collections of the small round cells had become deposited, the blood-vessels were dilated and replete with blood-globules, impacted in a manner such as I have only seen in the neighborhood of pyæmic infarcta.

* Archiv. für Ophthal. Vol. VI., pp. 324–332.

The stroma was only very sparely present, of a clearly striped quality, and in it were scattered a few small, round elements. In other places the blood-vessels had completely disappeared, and of the choroid only a narrow, connective tissue-like strip remained, as is represented in Fig. 6, ch.

The encroachment of the glioma on the choroid happened in such a manner that the cells invaded its tissue from the clusters which lay upon the epithelium, and then spread in all directions. By this process the affected choroidal tissue was absorbed, though not in circumscribed spots, as was the case with the sclerotic; for thinner and thicker rows of cells, which also here resembled ears of maize, penetrated between the fibrous choroidal tissue and the larger blood-vessels. These soon disappeared, as also the intervening bundles of filaments, so that the choroid appeared as an irregularly thick band of pure gliomatous tissue, altogether analogous to the similarly degenerated retina. The basement membrane of the choroid was not to be found in many places, especially in transverse sections. In preparations torn by needles, however, it presented itself as a perfectly clear, vitreous membrane.

The choroid, thus degenerated, now increased in thickness also, and formed low broad elevations, which (not in this eye, but in most of those which I have examined) usually led to extensive gliomatous deposits between the choroid and the sclerotic. This process can also be regarded as follows: that the pseudoplasma perforates the choroid and then continues to increase be-

tween the sclerotic and the choroid, which it detaches. In this wise the ciliary processes and the iris become separated from the sclerotic, and thereby an easy access for the pseudoplasma to the anterior chamber is prepared.

The *iris* of this eye was found in a condition of simple but very advanced atrophy (Fig. 8). Blood-vessels were scarcely yet indicated. The pigmentary layer (u) was normal, and in transverse sections about as thick as the iris stroma (ir) itself. This latter, in its most anterior layers (e), presented thickly-seated cells, most of which contained large nuclei (epithelium ?) ; in its centre, as far as the pigmentary layer, a parallel arrangement of fibres, with a limited number of scattered lymphoid cells.

The *ciliary body* was atrophied (Fig. 9) in like manner. The *ciliary muscle* (mc) was still recognizable, and, indeed, in transverse sections there could yet be seen externally and posteriorly the radiating (r), anteriorly and internally the circular (c) disposition of its elements.

The predominance of connective tissue over the muscular fibre-cells was plainly evident. The *ciliary processes* (pr) were very much attenuated, yet this atrophy was limited to the stroma encircled by pigment, which appeared as a narrow line. The outer investing membrane was not missing and but slightly shrunken. The zone of Zinn (zz) passed over it in fibrillæ very distinctly separated, and with it the ciliary processes and also a portion of the muscle were drawn far forward, which, indeed, was but a simple consequence of the crystalline being pushed toward the cornea. In the zone of Zinn a collection of small nuclear elements, with uniformly dotted interiors, was situated.

The *crystalline*, the *cornea*, and the *sclerotic* exhibited no morbid change.

The *other eye* of this child presented in its interior the same, though less advanced, disease. The eyeball was in constant motion, especially in an upward direction. Nevertheless, it followed the light held before it very well in every direction. It was doubtful whether there was an increased tension of the globe. The anterior chamber was slightly shallower than is usual for a suckling in the first months, on account of the normal-looking iris being carried forward. The pupil movable, though sluggish, and perfectly dilatable by the use of atropine. Even with the naked eye the *lower two-thirds of the fundus are seen glistening, of a whitish yellow color*, and pushed forward. This prominent mass is traversed by many red stripes and is sharply limited at its superior border. The translucent refracting media afforded by reflected light, and better still by aid of the ophthalmoscope, a clear insight into the interior of the eye, and permitted a perfect recognition of the details of the fundus. I have made a drawing of it (Plate I., Fig. A) as it appeared in the upright ophthalmoscopic image. The upper part of the fundus of the eye was normal in the whole of its extent, as well in color as in the ramifications of the retinal vessels. All the vessels, however, appeared cut off by the upper circular boundary of a yellowish intumescence. This projected very notably over the healthy fundus, so that it gradually sloped from the centre toward the border. Its surface was smooth, only very slightly uneven, glistening feebly, and

of a marked dark yellow color. On it the typical ramifications of the retinal vessels could with certainty be recognized; yet it was not possible to discover the papilla in any portion of the fundus. In one place the blood-vessels met, yet this was less in a point than in a short curve from which the regular ramifications of the vessels originated. Although some appeared of a light, others of a dark red, in many instances it was still doubtful whether they represented arteries or veins. On both sides the raised yellow surface passed gradually into the normal red fundus; inferiorly, however, it extended beyond the range of the ophthalmoscopic field of vision. On this dark yellow surface there still appeared, internally and superiorly, a *semiglobular oval mass of a light whitish yellow* color. Its surface was dull and granular, at the centre entirely free of blood-vessels—a few short, dark vessels creeping over the border. The *retinal* vessels disappeared at its margin.

How is this ophthalmoscopic picture to be explained?

The key to it is furnished in the anatomical condition of the other eye. The retina is gliomatously degenerated in its lower two-thirds, but in different degrees, and, indeed, in such a manner that on the darker yellow surface only its outer layers participate in the process which, in analogy to the other eye, must be considered a hyperplasy of the granular layers, and especially of the external. The limitans interna, stratum nervosum, and molecular layer are still so normal that in them the blood continues to circulate in the preserved vessels. The retina is possibly already detached from the choroid in this entire space,

for its surface lies anterior to the still normal retinal level, a circumstance which may nevertheless be attributed to a thickening of its outer layers. The region of the papilla lies at the central vascular arch. The formation of this ophthalmoscopic picture can be explained as follows: that the retina, being raised from two sides, applied itself with the limitans interna of one side adjoining that of the other; consequently the vessels were also raised, so that the first central division at the lamina cribrosa was concealed, but the subsequent subdivisions now approached each other over the papilla, and then, regularly radiating, continued their course toward the periphery. The *white raised mass*, however, is a true gliomatous tumor, in which all the layers of the retina, and also the blood-vessels, are destroyed. The rough surface even induces the supposition that an ulceration is imminent; but I must remind the reader that in the glioma clusters of the other eye the ulceration was not on the inner but on the outer surface of the retina. Still, one observation alone does not suffice by far for the deduction of a rule.

Further remarks on the condition of both eyes of this little patient will be given in the general division of this paper (Part I., Section 2).

The child was free from general and cerebral troubles, looked healthy, and had a good appetite. The enucleation of the eye first described healed without suppuration or inflammation, and the child was dismissed from the hospital six days afterward.

I saw the child again two years later, in the beginning of July, 1867. It looked healthy, had devel-

oped regularly, could walk and speak as well as could be expected from a blind child of its age. *A local recidive in the right orbit had not ensued.* The lids, conjunctiva, and the portions of the orbital cavity still remaining, were perfectly normal. In the other eye, however, the disease had progressed essentially. The whole eyeball was now manifestly filled by the pseudoplasma, for in the anterior chamber nothing could be seen but a mass of a dirty yellow color, with a shade of red. The cornea itself was flattened, hazy, and traversed by blood-vessels. The conjunctiva and episclera were somewhat injected, principally with venous blood. The globe tense (T. Bowman), and painful when touched. The eyeball, however, was not yet enlarged and did not protrude; neither was it limited in its motion.

On the 12th of December, 1867, the child was again brought to my clinique, and, indeed, in a most pitiable condition. It was emaciated, pale, had but little appetite, temperature of the skin rather high, and a pulse of 110 to 120 in the minute.

Ten weeks ago the eye began to grow larger, the lids became swollen, the eyeball perforated, a reddish spongy mass sprouted from it, distended the lids, ulcerated, and secreted a dirty reddish juice. Six to seven weeks ago (pretty much at the same time), tumors, constantly increasing in size, formed in different places on the cranium.

Stat. præs. (see Fig. 10). Out of the left orbital cavity a cylindric tumor with an irregular anterior surface vegetated, having a transverse diameter of 65 mm., a vertical of 75 mm., and an antero-posterior of 55 mm.

The eyelids gird its base as a belt 5 to 15 mm. in breadth. The tumor is of a reddish color, soft and spongy; its surface covered with grayish-black crusts, which are imbued with a yellowish viscous juice. This exudes from the tumor abundantly. Hæmorrhages were also frequent occurrences.

Six subcutaneous, soft, almost fluctuating intumescences, rather sharply circumscribed, and separated from each other, are situated on the cranium. No impressions nor sharp edges can be felt on the cranial bones. The integument covering the tumors is tense, shining, white, and traversed by many thick, tortuous, bluish-red vessels. On the left temple there is a tumor 45 mm. in length and 30 mm. in breadth, apparently unconnected with the tumor vegetating from the orbit, described above; another, the size of a walnut, is seated on the angle of the lower jaw; one of the size of a hen's egg occupies the left half of the forehead; another of equal size is situated on the right temple, constricted superiorly, and, attaining the size of a goose's egg, reaches the mesial line of the vault of the cranium; opposite it, in the centre of the left parietal bone, the last isolated intumescence, of the size of a walnut, is found. All of these tumors increased in size with remarkable rapidity. A puncture of the intumescence located in the right temple with an exploring trocar evacuated a small quantity of a bloody mass, in which yellowish delicate portions floated. They were immediately brought under the microscope, and proved to be colorless, semi-transparent round elements, finely granular and the size of white

blood globules. They were intimately united by an amorphous cement, so that only here and there one of them floated in the fluid. It was a typical glioma tissue, such as we have already described in the *retinal* tumors of the other eye of this child.

The little patient was put upon nutritious diet. The tumor, from which a great quantity of offensive juice exuded, was attentively cleansed and covered with lint, which was moistened alternately in chlorate of lime and hypermanganate of potassa. In this manner we were successful in correcting the stench from the ulcerating orbital tumor. Chlorine water (30 grammes of calcaria hyperchlorosa to 180 grammes of water, for moistening the lint) was most effectual, but when continued for a longer period excoriated the skin; consequently a solution of like concentration of hypermanganate of potassa was alternately employed.

The child emaciated visibly, became very anæmic, and the tumors grew with remarkable rapidity; without either vomiting, twitching of the muscles, paralysis, or any symptom of pain or coma indicating a participation of the brain in the morbid process. After the tumors had acquired from two to three times their size at the time of admission to the hospital, the child died from exhaustion, on the 27th of December, 1867.

The autopsy was made in my presence, by Prof. J. Arnold of Heidelberg, and the entire specimen presented to the Pathological Institute of that city. Prof. J. Arnold had the kindness to undertake the minute examination and description of the changes in

the corpse (with the exception of the orbital tumor). I can embody his description, so kindly placed at my disposal, in this work with the more pleasure, inasmuch as I assisted in the examination, and observed with him all the minutiæ of this highly interesting case.

Post-mortem examination. Slight rigidness, the corpse greatly emaciated, integument white, subcutaneous adipose tissue atrophied, muscles well developed but pale. The cranial portion of the head is considerably larger, the enlargement being irregular, and caused by larger and smaller prominences (Fig. 11). The integument of the head is very much thickened, its subcutaneous cellular tissue infiltrated with serum. After the removal of the scalp it becomes evident that the increase in the size of the cranium is owing to the presence of several large tumors, which are in no wise connected to the skin, and only one of which adheres to it.

The tumors present the following conditions relative to their seat, extent, and relations to the neighboring parts. On the left frontal bone a tumor (Figs. 11 and 12, a) is seated, extending to the right somewhat beyond the mesial line, its diameter at the base 7, its greatest thickness 2 centimetres. It is semispherical in shape. Its surface is clothed with periosteum, which is thicker, and infiltrated in this place. It is of very soft consistence, and when cut a creamy fluid mixed with blood flows out, whilst a very soft, marrowy tissue, here and there very vascular and rather regularly arranged, remains. Toward the interior the tumor encroaches upon the bones—indeed, in one place (about the size of a five-cent piece) the bone

had been absorbed, the pseudoplasma being now separated from the cavity of the cranium only by the dura mater (Fig. 12, b).

A second larger, more spherical tumor, having a diameter at its base of 7½, and a greatest thickness of 3½ centimetres, occupies the left temporal region (Figs. 11 and 12, c). It extends *posteriorly* to the anterior wall of the meatus auditorius externus, *anteriorly* to the outer commissure of the left eye, *superiorly* to 3 centimetres inferior and anterior to the left parietal eminence, *inferiorly* to the alveolar process of the superior maxillary bone. Toward the interior it projects considerably into the anterior half of the middle and into the posterior third of the anterior cranial fossæ (Fig. 12, d). The portions of bone situated in these places seem to have been entirely absorbed as the tumor developed. The separation of the pseudoplasma from the cranial cavity is effected by the dura mater, which in a place about the size of a five-cent piece nearest to the body of the sphenoid bone (Fig. 12, e) also seems to be infiltrated with a marrowy substance, so that a perforation might have been looked for in a short time.

In the right temporal region a tumor (Fig. 11, f) is situated, which substantially bears the same relations as the one just described, only extends somewhat further posteriorly and superiorly, but intrudes, in like manner, into the middle and anterior cranial fossæ (Fig. 12, ih). The dura mater covering the inner surface is unaffected.

To the superior border of this tumor another (Figs. 11

and 12, g) is attached so closely that the separation is only indicated by a slight furrow, reaching posteriorly almost to the right parietal eminence, and extending to the mesial line of the vault of the cranium. The diameter at its base is 9, its greatest thickness 4 ctm. Toward the interior it also projects into the cranial cavity (Fig. 12, h), and is clothed by the dura mater, which in this place appears tuberous, and to be carried before the tumor.

The place of the right parietal eminence is also occupied by a tumor, 7 ctm. in diameter, continuous posteriorly as far as the lambdoidal suture, and separated anteriorly from the posterior border of the tumor last described by a narrow rim.

A small tumor, measuring only three ctm. at its base, is situated on the left parietal eminence, and also invades the interior.

Aside from these, there are three other smaller tumors present, one of which projects slightly, externally and internally, whilst *the other two are situated chiefly in the diploë and are still enclosed, both externally and internally, in bone.*

The dura mater is strongly injected in those places where tumors are situated; otherwise not essentially changed. In the longitudinal sinus a consistent coagulum is found adhering to its coats; the small venous trunks leading into the sinus are also obstructed by older thrombi. On the right side the coagulum is continued from the sinus longitudinalis into the sinus transversus, which is choked by a coagulum throughout its

entire course. The cavity of the cranium appears narrowed by the tumors projecting into it through the anterior and middle fossæ and the vault. The *pia mater* is somewhat injected here and there. The *brain* is normal in size, and appears somewhat flattened in those places where the dura mater was pushed into the cranial cavity. The lateral ventricles contain clear serum. The substance of the brain is œdematous and anæmic; only in two places on the parietal lobes, near the longitudinal sinus, there are two larger herds with punctate extravasations. Cerebellum, pons, medulla oblongata, and corpora quadrigemina are normal. The optic nerves appear somewhat flatter and thinner than usual.

Before the left orbit there lies a marrowy tumor of the size of a middle-sized apple, its surface partly excoriated and in part covered by dried crusts (Fig. 11, k), and continuous with the contents of the orbit by means of a thick peduncle which completely filled the widened palpebral fissure. After removing the roof of the orbit, before which the tumor lay, the contents of the orbit with the tumor appear as one mass, the posterior portion of which is situated in the orbital cavity, its surface covered by the periosteum, and so sharply defined on all sides that it would be easy to enucleate the whole. Whilst the inner, upper, and lower walls of the orbit manifest normal conditions, the outer wall is almost completely wanting, and in its place a soft mass is found enveloped in a membrane of connective tissue, which, upon more minute examination, proved to be a portion of the tumor lying in the left temporal region. This encroaches not only on the

middle and posterior divisions of the anterior cranial fossa, but also on the orbit, through the outer wall of which it had burst (Fig. 13, t gl kn). But just as it is covered with dura mater in the cranial cavity (Fig. 13, dm) it is clothed by the periosteum here (Fig. 13, pe), which does not appear perforated in any place, and thus effectually separates the tumor from the contents of the orbital cavity. The outer bony wall of the orbit is also wanting to an extent of several lines. The superior wall is also incomplete (Fig. 13, dek).

The description of the condition of the contents of the orbit and of the tumor anterior to it will be given hereafter.

In the right orbital cavity lies a cicatricial mass surrounded by fat. The roof, floor, and inner wall are also normal, but the outer wall is perforated to a greater extent by a tumor situated in the right temporal region, its surface having a covering of connective tissue, and thus being separated from the contents of the orbital cavity.

The cervical glands are much swollen.

Conditions of larynx, trachea, and œsophagus normal.

The articulations of the costal cartilages, with the anterior extremities of the ribs and the extremities of the long bones, are considerably thickened. In the pericardium clear serum. The endocardium and the valves of the heart manifest no abnormality. The muscular elements are of medium thickness and very pale.

In both lungs the lower lobes are found in a state of

hypostasis and atelectasis. Circumscribed extravasations are interspersed in many places throughout the spleen. The cortical substance of both kidneys is pale, discolored, and here and there somewhat yellowish; the medullary portion normal.

Near the edge of the *right lobe of the liver a large tumor and a number of smaller ones were* situated. They were white in color and of *a medullary composition*, the larger one containing many blood-vessels and small extravasations. In the left lobe also a large medullary tumor is situated, which has in part undergone caseous metamorphosis. The glands around the portal veins are enlarged. In the intestinal canal no anomaly worthy of mention.

The microscopic investigation of the tumors of the skull disclosed their structure of numerous roundish cells with large brilliant nuclei. The latter fill the greater part of the cell-body, which can only be distinguished by a very narrow peripheral outline. The entire formation is very delicate, and doubtlessly bears the characteristics of the cells found in glioma. They are in a fresh state, imbedded in a very soft, almost homogeneous intercellular substance, which when hardened appears finely fibrous. Though the cellular elements are very abundant, the intercellular substance is in general very scant; only in a few places becoming somewhat more abundant. The relation of the cells to the intercellular substance is variable, inasmuch as the former are in some places closely adherent to the latter, and in others their connection ap-

pears to be a mere contiguity. In no place, however, are the characteristics of carcinoma present; in other words, the pseudoplasma bears most decidedly the stamp of a multicellular glioma.

This is the general structure of the cranial tumors; but a few parts manifest variations not altogether unimportant. Thus, principally, numerous places are found in which the intercellular substance is chiefly myxomatous. The cells then lie densely accumulated in a very soft tissue, or, on the other hand, may have been destroyed by the mode of myxomatous softening, and the glioma-tissue have been replaced by a more mucous mass.

All the tumors are very rich in blood-vessels, and in all portions vascular spaces can be found partly filled with blood and in part collapsed; they are of variable size, but generally rather wide. In consequence of this abundance of vessels on the one hand, and on account of the soft consistence of the tumor on the other, hæmorrhages have occurred in many spots, most frequently and to a particularly great extent in those portions of the tumor which had undergone myxomatous softening.

In regard to the development of the *tumors of the cranium*, we may assume that their *origin was derived from the diploëtic substance* and not from the soft parts covering the bones, for the smallest of these tumors had perforated neither the outer nor the inner table of the cranial vault, whilst some of the others had pierced either through the outer or the inner table alone. The dura mater internally and the periosteum external-

ly participated so slightly in the process of new formation that they only acted as limiting membranes of the pseudoplasma.

In what part of the osseous tissue the latter originated can be ascertained from sections of pieces deprived of their lime by the action of chromic acid. In the sections of bone around the tumor, the diploëtic spaces already appear larger, more vascular, and filled with numerous young cells. The nearer we approach the tumors themselves the wider the cancelli become, and the more numerous the vessels and young cells contained in them, whilst the bridges of bone bounding the interspaces constantly grow narrower. The osseous tissue disappears in the same proportion as the filling of the cancelli bounded by it advances. The disappearance of the bony tissue is inaugurated by a loosening of the intercellular substance and terminates in complete softening. A participation of the bone-corpuscles thus disengaged in the process of new formation, which takes place in the cancelli of the diploë, cannot be demonstrated; this process appears to go on exclusively in the marrow of the bone. Consequently the marrow must be designated as the place of development of the youngest gliomatous tumors forming in the bones of the cranium.

Whilst the tumors of the cranium, in consideration of their peculiar structure, might be designated as glioma, those of the *liver* presented more of the characteristics of *glio-sarcoma*. Certainly here also cells which resemble those of gliomatous tissue were present, but most of them had the characteristics of cells as they are found

in glio-sarcoma. They were somewhat larger than those in the cranial tumors, i. e., had a larger cell-body, and the cells and nuclei contained a distinctly granular substance. In many places we were successful in demonstrating the transition of the glioma to the glio-sarcoma cells.

These tumors also were very vascular, and in every section broad utricles were encountered, cut transversely, longitudinally, and obliquely, upon whose walls the cells were pretty regularly arranged. Hæmorrhagic spots also were demonstrable.

At the periphery the tumors were surrounded by a zone of connective tissue in a process of active proliferation: in a state of interstitial hyperplasy, which extended rather far into the apparently healthy tissue of the liver.

For examination of the contents of the orbit a triangular piece was excised from the frontal bone; its horizontal plate, forming the roof of the orbital cavity and being perfectly preserved, was removed at the same time. Over the foramen opticum, the superior (anterior) root of the lesser wing of the sphenoid (Fig. 13, bk) was removed, and thus the optic nerve and the ophthalmic artery were exposed. The latter was uninjured in texture, but appeared of larger calibre. The optic nerve (Fig. 13, no) was somewhat thinner than usual, regularly enclosed in its fibrous sheath, and could easily be followed to the sclerotic, in the vicinity of which it scarcely became any thicker. The transverse section, after it had been freed from its sheath, measured 1.5 mm. The mass (Fig. 13, gle) of pseudoplasma had pushed the degenerated eye forward, and therefore the optic nerve had become stretched

throughout its entire course, and measured 60 mm. from the foramen opticum to the sclerotic.

All the contents of the orbit were enclosed by the uninjured periorbita. The levator palpebræ superioris (Fig. 13, lps) had, as all the other muscles of the eye, retained its insertion into the fibrous ring at the apex of the orbital cavity. It was normal in its course, and attached by an aponeurosis much wider than usual to the upper lid, which was expanded to its utmost capacity by the tumor. Under it lay the rectus superior (mrs), which was raised in its course by the tumor as it encroached upon the orbit. Its tendon was widened, perforated by the pseudoplasma, and from it there radiated several white fibrous trabécules through the soft mass toward the sclerotic. The bellies of the recti, internus and externus, were very much enlarged, and thus gave these muscles a membranous appearance. The fibrillæ of the muscles proved, on microscopical examination, to be attenuated, without deposits of foreign elements in them or in the connective tissue between them (perimysium internum).

The fatty cellular tissue of the orbit was still normal in several places at the apex of the pyramid, but more anteriorly interspersed with small dotted granules (glioma-cells) which penetrated into the adipose and connective tissue in rows and clusters, and which had supplanted this tissue more anteriorly, with the exception of occasional fibrous cords. Through the abundant accumulations of granules there passed a net-work of the preserved, tortuous, well-defined, and elastic fibres of the

orbital cavity. The optic nerve in its entire course through the orbit was of a uniform structure, differing from the normal only in as much as the fasciculi were in part attenuated, and here and there interspersed with molecules of fat.

After having followed the optic nerve to the sclerotic, I made a section through the whole anterior part of the tumor. Its transverse diameter was 70 mm.; and its antero-posterior, from the hindermost portion of the sclerotic to the apex of the pseudoplasma, was 43 mm.

The entire anterior portion lying exteriorly to the orbit, as well as the neighboring portions within it (gle), appeared as a uniform, soft, marrowy mass, almost diffluent in many places, and which comprised, besides the optic nerve and the muscles above mentioned, the thickened capsule of the sclerotic, perforated anteriorly (Fig. 13, scl). The rupture had manifestly occurred in the cornea, for the tissue of the sclerotic could still be distinctly recognized by its toughness and white lustre, and was demonstrated as such by the microscope, under which it appeared macerated but not degenerated. In the sclerotic, the degenerated contents of the globe were situated. In the centre the compressed choroid (Fig. 13, ch) could be distinguished by its black color. It enveloped a granular, caseous, yellowish mass, the degenerated retina (Fig. 13, re). External to it there lay, surrounded by the sclerotic (Fig. 13, gl), a thick layer of pulpy marrow, which was continuous with the extraocular tumor. To the external surface of the sclerotic the pseudoplasma was closely and indissolubly attached, and was traversed

by a number of fibrous strings coming from the sclerotic. The sclerotic passed directly into the outer sheath of the optic nerve. The lamina cribrosa presented itself as a dense fibrous web, into which the optic nerve entered apparently unchanged, but also disappeared in it, since the internal surface of the lamina cribrosa, as also of the whole sclerotic, was limited by a homogeneous granular medullary mass. The interior of the globe was a uniform accumulation of small round cells lying closely together, only in the shreds of the choroid remains of pigmented cells were preserved. Of the other portions of the contents of the globe nothing more could be discovered.

CASE II.—*Unilateral Glioma of the Retina with Extension to the Optic Nerve and Cerebrum.*

Jacob Schnell's little boy, æt. 4, of Hainstadt, near Wimpfen; descended from healthy parents. Already a year ago, a yellow, shining streak, spreading slowly, and becoming more distinct and approaching the level of the pupil, was observed in the depth of the left eye. The boy never complained of pain either in the eye or head; was in general in very good health until about four weeks ago, when the eye began to increase in size, and frequent headache and vomiting, the latter especially after meals, instituted themselves.

Stat. præs. The boy presented himself at my clinique Jan. 2, 1867; appeared robust, though during the last

four weeks he had become considerably emaciated and irritable; besides, he complained of frequent headache, nausea, vomiting, and dulness, and slept more than usual. The enlarged eyeball was traversed by thickened episcleral veins, was pushed forward from 8 to 10 mm., and was exceedingly tense (T. Bowman). The transparent cornea was almost completely insensible, the anterior chamber shallow, the iris apparently atrophied, and several black synechiæ were on the softened margin of the pupil, the latter being white, fixed, and oval. The lens was transparent, but behind it a dirty yellow mass could be seen filling the entire anterior portion of the vitreous. It had a dull, rather smooth surface, which appeared covered by a veil-like opacity.

The disease was pronounced a *glioma* of the retina; and an extension to the optic nerve and the brain was assumed, on account of the enlargement and projection of the eye, and because its posterior cavity was completely filled by the tumor, and finally, on account of the presence of cerebral symptoms.

Prognosis pessima. Treatment: enucleatio bulbi.

Anatomical Examination of the Eyeball.

The eye, enlarged in every direction, was laid immediately after the enucleation in Müller's fluid and opened for fresh examination three hours afterward.*

* Obs.—I prefer to open eyes with tumors and, when possible, all others on the day of their extirpation and to examine them, at least superficially. This will necessarily occupy one or several hours. If the eye lies for a lon-

The measurements of the globe (Fig. 14) were as follows: Transverse and perpendicular diameter 24 mm. each, longitudinal 25½ mm. Thus, the globe of this lad of four years was, in all its dimensions, from 2 to 3 mm. larger than a medium-sized adult eye. The optic nerve also was thickened to about three times its normal size. Its transverse section was oval and of unequal thickness, in such a manner that near the eyeball it had 5 and 6 mm., somewhat posteriorly 6½ and 8 mm. as the smallest

ger period in a fluid which hardens it, no good conclusion about the process which takes place in the living eye can be drawn, for the vessels disappear, the color becomes completely changed, and no opinion can be formed of the density of the several parts, since, through coagulation of the fluid constituents, and hardening of the morphological elements, the several parts acquire an appearance altogether different from the living tissues. Thus, for instance, the normal vitreous concretes into a gelatinous brown mass, after it has been lying for a long time in Müller's fluid. If a superficial examination has been made on the first day, the specimen can be laid in the hardening fluid, and the accurate investigation be undertaken at a suitable time. If all oculists made it a duty to examine all enucleated eyes at their disposal as accurately as their time and ability permit, and then to communicate the results in their professional journals, we should be better informed of the morbid changes of the eye, and even a *Virchow* (in different places of his standard work on *Morbid Tumors*) would not be obliged to complain of the scarcity of material for the investigation of this subject. Every publication respecting a post-mortem appearance, not altogether too frequent in its occurrence, is valuable, and will introduce no errors into science, so long as physicians make it their duty to describe faithfully and true to nature only what they have distinctly seen, and can defend themselves against every criticism. Even if the microscopical examination of an important case should be wanting, an accurate description of the relations visible to the naked eye can be of the greatest utility. At the very worst, it will surely increase the statistics. Since no man's abilities are of so high an order as to attain perfection, we must, while working, remember the old English saying, "If we cannot do the best, we must do the best we can."

and largest diameters of the elliptical surface of its transverse section. Close to its exit from the cranium it again became thinner.

Macroscopical Examination immediately after the Extirpation.

The *sclerotic*, which was very nicely enucleated from Tenon's capsule, showed no abnormality on its exterior. There was neither gap nor spot nor anything else visible which might possibly lead to the conviction of the existence of a perforation or of an outer mass of the foreign growth. The eyeball was divided into an anterior and posterior half by means of an equatorial section. At the time of the incision, already a large quantity of watery, yellowish fluid escaped, which showed under the microscope very small round corpuscles, collections of fat granules, suspended in a watery fluid; in short, it appeared like watery pus. This fluid had collected between the choroid and the degenerated retina (Fig. 14, e). *The centre of the vitreous was occupied by a cord, springing from the optic nerve by a narrow pedicle which gradually enlarged as it advanced* (Fig. 14, n), *and applied itself to the ciliary body.* Its surface was slightly uneven, of a white color somewhat approaching the yellow, beset with many fine light-red points, and traversed by simple and branching red lines (blood-vessels). The consistence was that of a soft cheesy pulp, which had scarcely firmness enough to offer resistance to the cut of the scissors. The appearance of the cut-surface was pre-

cisely like that of the surface itself; cheesy, on account of the numerous white clusters which lay close together in a transparent, slightly adhesive, and completely soft connecting mass. *Under the microscope it manifested itself as a collection of small round cells which lay partly close together, partly separated by a small quantity of homogeneous vitreous basement substance.* The transverse section had neither in the centre nor on the border nor elsewhere a membranous composition, nor any other than that of a white caseous pulp.

On the choroid lay in a few places a delicate, transparent, white membrane which could easily be removed (adherent pus-cells ?). In the posterior part of the eye the choroid was considerably thickened, harder, and surrounded the pedicle of the pseudoplasma (Fig. 14, aa) as a perforated disc. The pigment was defective on the surface of this thickened mass, as also on the whole of the internal surface of the choroid, and was entirely wanting in many places, so that the *choroid* appeared spotted of a dull white color (pigment atrophy through maceration). *The tissue of the choroid was remarkably thin and soft*, and could be removed without the least resistance from the yellowish-white inner surface of the sclerotic, so that no traces of the supra-choroidea were visible (atrophy of the choroid in all its layers).

I then made a longitudinal section through each half of the globe, in such a manner that it ran through the middle of the tumor, as also of the optic nerve, the lens, and the cornea. This produced the appearance represented in the drawing of the longitudinal section (Fig. 14).

The *optic nerve* (o) presented a uniform cut-surface, moderately tough and lardaceous, and continuing as far as the funnel-shaped choroidal opening, where it underwent a marked compression. There it also became converted into the white cheesy mass (n) just described. *The sheath of the optic nerve* was greatly attenuated as though it had become dilated by its tumefied contents, an assumption which is confirmed not only by the excessive firmness of the nerve, but also because the contents projected over the transverse cut by $\frac{1}{2}$–1 mm. This substance of the optic nerve had lost the beautiful white lustre of the normal optic nerve, and appeared everywhere gray, glassy, lardaceous, and slightly translucent.

Of entirely similar appearance and density, only somewhat less hard, was the previously mentioned disc-like thickening of the posterior portion of the *choroid* (Fig. 14, a). It was of a gray color, glassy, semitransparent, like boiled bacon. Only the edge, which was directed forwards, was softer. The transverse section did not appear uniform, its posterior portion being speckled with whitish-yellow points which exactly resembled the cheesy little lumps of pseudoplasma, while blackish-brown dots were scattered in the internal and marginal layer. This intumescence acquired its greatest thickness in the vicinity of the axis of the eye, where it became rounded, and then gradually more and more pointed as it approached the equator, in such a manner that it passed directly into the attenuated choroid. It could easily be lifted from the sclerotic, not being attached to it by any connective tissue, but the choroid which constituted its di-

rect continuation detached itself with it. The pigment layer of the choroid was continued as a fine line on the internal surface of the cake-like intumescence.

Anteriorly, the caseous pseudoplasma was loosely joined to the ciliary body in its whole extent, and could be separated from it without tearing its tissue, by pulling gently. Even the perfectly preserved pigment layer of the ciliary processes remained unchanged upon it.

Still, between the posterior surface of the crystalline and the anterior border of the tumor, there was a small interval (v) containing a viscous, translucent fluid, from which delicate shreds (remains of the vitreous) could be removed with the forceps. This it was which, in the living eye, caused the anterior portion of the tumor to appear covered with a veil-like opacity. Nevertheless the remains of the vitreous did not penetrate, funnel-like as usual, to the centre of the degenerated retina, but clothed the posterior surface of the crystalline as a narrow layer which became slightly broader at the posterior pole of the lens.

On the ciliary muscle, lens, iris, anterior chamber and cornea, nothing abnormal was discoverable by the naked eye.

Microscopic Examination.

On the portion which must be regarded as *degenerated retina* the subsequent examination also showed nothing remarkable further than what the previous examination had already brought to light; namely, a manifest, *vascular glioma-mass.*

The optic nerve was degenerated in exactly the same way. Large masses of small cells had accumulated in it and had caused its tissue to disappear almost completely, only a few remnants of the bundles of nerve-fibres being preserved. These lay scattered in the luxuriant cellular mass. *The extension of the glioma to the choroid* was full of interest. In most places the several layers of the choroid could still be demonstrated, although the scarcity of blood-vessels made an atrophy evident. *Superficial accumulations of glioma-cells* (Fig. 15, a) were very numerous, raising the epithelium and spreading between them and the resisting basement membrane (Fig. 15, gl).

The several layers of the tissue beneath were not so pure as in the normal condition. The stellate cells made way for more spindle-shaped and filamentous elements containing numerous nuclei. The vessels were full of blood in a few places, wanting in some, and in others again pretty regularly arranged.

Aside from the small glioma clusters, there were also, especially in the region of the ciliary body, extensive tracts where the glioma-cells vegetated exuberantly in the epithelium and the deeper layers of the choroid.

The thickened zone of the choroid, however, which surrounded the optic nerve, and whose degeneration could be recognized even with the naked eye, proved to be the most changed. In the fresh condition it was gray and transparent, and of an entirely different appearance from the neighboring gliomatously degenerated retina, so that one might suspect the existence of a compound tumor. This,

however, was not the case. The entire mass again proved to be pure gliomatous tissue which had spread in every direction from the border of the optic nerve regularly on the choroid. In the vicinity of the optic nerve only a few shreds of the preserved pigmented stroma-cells floated in the ocean of small round cells. The further one progressed toward the equator of the eye the more remains of choroidal tissue could be found between the glioma-cells. The point of transition showed very plainly the fusion of the choroidal stroma by the action of the pseudoplasma. Anterior to this boundary, vessels were seen only in small numbers; they had wasted away before reaching it. The small round cells penetrated in rows and heaps into the fibrous choroidal tissue, and became more and more thick and broad, by which process the resemblance to ears of maize was again most plainly produced, and continued to incorporate in themselves the separated elements of the fundamental tissue, until at last nothing thereof remained. The proliferous mass did not reach the outer surface of the choroid of this eye; the sclerotic also was perfectly unaffected.

The progress of the affection was such, that the wound left by the enucleation healed without suppuration, and caused no change in the health of the patient. At the expiration of ten days he was dismissed; from this time the cerebral symptoms gradually increased in intensity. The dulness and apathy of the child became especially more marked, and it died in a comatose condition about three or four weeks after the operation.

The permission to make an autopsy was not granted.

Case III.—*Glioma without Perforation, completely filling the Interior of the Eye.*

[The preparation of this eye, hardened in spirits, I found in my collection without any particulars, so that I do not know to which case it belongs. Consequently I can only communicate the anatomical examination.]

The interior of the eye (Fig. 16) was completely filled by the pseudoplasma, and all the parts, with the exception of the lens, were pushed from their place and so degenerated that it was almost impossible to recognize them. Of the *retina*, there were no traces left. The *choroid* (Fig. 16, ch) was crowded inward and reduced to a number of narrower and broader strips which were still recognizable by their black color. Under the microscope it proved to be partly atrophied to connective tissue and partly occupied and degenerated by glioma masses. A portion of it (Fig. 16, c) grated on being cut, and under the microscope manifested *calcareous glioma clusters*, which were situated in the shrunken choroidal tissue. They harmonized perfectly in appearance and relations with those of Cases V. and VI.

The *ciliary body* (Fig. 16, Co. C) still presented preserved pigment-cells, but was also for the most part atrophied, so that parallel strips of connective tissue encompassed the heaps of colored cells. Blood-vessels were very scantily supplied. The shape of the ciliary process was not distinguishable. The *ciliary muscle* (Fig 16, m) was atrophied, but still contained muscular elements in

both longitudinal and transverse fasciculi. Between them lay strips of connective tissue filled with nuclei or granules. In different places, however, the pseudoplasma of small cells penetrated it and caused the complete destruction of both the connective tissue and the muscular elements. The pigmentary epithelial layer of the ciliary body was loosened; the pigment of many cells had collected in irregular balls, and the whole was filled with *fat globules*, scattered about or lying together in heaps. The space between the lens and the compressed choroid, as well as that between the choroid and sclerotic, contained a white granular mass, which under the microscope presented the pure gliomatous composition, and nothing else. The mass which filled the anterior chamber was of identical formation. The *optic nerve* was full of small degenerated cells.

CASE IV.—*Unilateral Glioma with Rupture of the Sclerotic.*

Alois Kugler, of Flehingen, $2\frac{1}{2}$ years old, of healthy appearance; always had been healthy and of healthy parentage. About $1\frac{1}{2}$ years ago the family physician, Dr. Rossknecht, noticed a white reflection in the pupil when the child faced the light, and the eye, otherwise of perfectly normal appearance, proved to be totally blind. In this condition it remained unchanged 14 months, then became encircled by a red ring, protruded, secreted a watery fluid, then improved somewhat, and three weeks

ago again became inflamed. On the outer portion of the sclerotic a reddish-white tumor, which fell off in a few days, manifested itself; besides an ulcer of the cornea instituted itself, with a suppurating base and an intense opacity of the whole cornea. In this condition the patient presented herself the first time. The eye was markedly enlarged, the conjunctiva injected; through the corneal opacity neither iris nor pupil to be seen. Ten days later the little patient was brought back for operation.

Status præsens. The eye projecting about 4 to 5‴; lids strongly stretched, reddish; conjunctiva bluish-red and swollen; inferiorly and externally a thick globular eminence in the sclerotic. On the cornea a large ulcer with suppurating base; the cornea very opaque; iris and lens touching the cornea; iris of a dirty gray color, with margin slightly jagged. By focal illumination through the cornea the contents of the globe shine with a dirty yellow reflection.

At the time of extirpation it was shown that the inner, upper, and outer portions of the globe were unaffected, but inferiorly a tumor was situated upon the sclerotic, which itself was about the size of a child's eye. The globe and the tumor were enucleated with forceps, strabismus hooks, and scissors, from their sound receptacle; then the optic nerve was divided close to the globe, and as it became evident, on taction, that it was greatly thickened further posteriorly, another larger piece of the same was cut out of the orbit.

The enucleated eye was immediately examined.

The *external tumor* (Fig. 18, k) was enclosed in

fibrous tissue, and when divided presented itself as a reddish-gray, soft, marrowish substance. Superficially it had a somewhat firmer consistence, but the interior was of a pappy softness and fluid in a few places. The enveloping membrane was here and there of a bluish dark red, and under the microscope there appeared old extravasations in it, and black *pigment lumps* and *clusters* (Fig. 17, a), manifestly originating from former extravasations. Precisely similar dark figures could be discovered in the substance of the outer tumor itself. This was in all parts of a homogeneous structure; where the mass still appeared semitransparent and lardaceous, it was composed of moderately large round cells lying close upon each other, each containing a large nucleus (Fig. 17, b). These cells appeared as discs with a homogeneous, transparent interior, representing the nucleus surrounded by a narrow, brighter ring (protoplasma).

On most softer places, the cells were smaller, plainly dotted, and wholly similar to the ordinary glioma-cells or the retinal granules; but, aside from these, a multitude of free smaller granules were also seen (Fig. 17, c); a considerable quantity of fat could be found in it, as well in scattered granules (Fig. 17, d) as in spheres (d′), and in the interior of the glioma-cells (d″). Thereby, both the luxuriant growth (at b) and the decay (c, d, d′, d″) were illustrated. The globe was laid open by a longitudinal section (Fig. 18), which intersected the middle of the tumor, situated below the middle of the optic nerve and cornea. The *sclerotic* revealed no point

of rupture in this section, and was not much changed in color, but, in the neighborhood of the optic nerve, was thickened, and, more anteriorly, somewhat attenuated; still, neither of these to any considerable degree. Under the microscope the most of its tissue appeared normal; yet in several places it was manifestly changed. Wherever clusters of small round cells (Fig. 19, a) were situated upon the surface of the sclerotic, the cells grew into its otherwise normal tissue, so that it disappeared before them—became dissolved—without its cells or fibres participating in the vegetating process. Consequently, it was an invasion of the sclerotic by glioma-cells (Fig. 19, b). The preparation was rendered transparent by acetic acid, and, by changing the adjustment, a thin layer of scleral tissue could be seen over the penetrating glioma clusters, proving conclusively that the cells did not merely by accident acquire their position on the preparation. This condition was again discovered, in many other sections, to be the usual process for the extension of glioma to the tissue of the sclerotic. *It directly demonstrates the manner in which perforation of the eyeball by the tumor takes place.*

The optic nerve (Fig. 18, e) *was completely degenerated external to the eye and in the sclero-choroidal canal;* connective tissue and nerve had disappeared, and were replaced by glioma tissue, in which amorphous basement substance was present in considerable quantities between the small cells. Only very rarely could I perceive preserved remnants of bundles of nerve-fibres.

The *interior of the eye* was filled with a soft, granular,

yellowish mass, which in its posterior portion (Fig. 18, d) was of a purer yellow and entirely opaque, more anteriorly (Fig. 18, a) somewhat paler, and richly supplied with blood-vessels. It consisted of pure glioma tissue traversed by numerous vessels full of blood-globules. Nevertheless, in the paler portions several yellowish cheesy lumps (Fig. 18, l) were situated. They revealed under the microscope a great abundance of fat granules lying promiscuously in its substance.

The *choroid* (Fig. 18, b) did not line the entire inner surface of the sclerotic, but had disappeared in some places, and in others was greatly attenuated. Its peculiar structure was nowhere recognizable. In the places where it was least changed the swollen pigment cells, which had assumed figures entirely irregular, lay scattered *in a fibrous tissue containing numerous small cells.* These small cells resembled glioma-cells, or retinal granules; but I could not regard them as their immediate offspring, since they did not occur in clusters in a scanty, amorphous matrix, but were scattered in a fibrous tissue as in parenchymatous and suppurative choroiditis. The same condition has been represented in Fig. 21. I believe that they arise from the unpigmented stellate cells in an inflammatory state, or from the round lymphoid cells interspersing the choroidal tissue. They might also, according to the views of Cohnheim, be considered as emigrated white blood-corpuscles. In some places the pigment cells had accumulated. This does not prove an increase of pigment, for the choroid was crumpled and to a considerable extent displaced the proliferous mass.

Very much fat was continually added to the cellular elements. In parts where the choroid was more markedly changed, the round cells approached nearer to each other; in others the fibrous tissue became thicker, and still in others the pure glioma structure was full of shreds of the brown, pigmented stroma cells of the choroid. Blood-vessels were present in all the places last mentioned, yet the ramifications peculiar to the *choroidal* vessels could not be recognized, as they resembled those of newly organized glioma tissue. *Consequently the choroid had become degenerated and its disappearance effected, partly by inflammatory processes and partly by the extension of the glioma.*

Between choroid and sclerotic there was a pale yellow layer of glioma from 3 to 4 mm. in thickness (Fig. 18, m), and containing numerous vessels. It reached from the optic nerve to the origin of the iris, and had separated the ciliary body from its attachments. Between it and the outer tumor (Fig. 18, k) ran the sclerotic, upon which the gliomatous mass encroached, as described above.

The *lens* and *iris* were crowded on the cornea, the former being normal, the latter atrophied.

The wound in the orbit, left by the operation, cicatrized and became invested with connective tissue soon after; so that, at the end of the first week, the little patient was dismissed from the hospital.

Two months afterward he was brought back with a local recidive; for a reddish medullary tumor, about the size of a child's fist, projected from the orbit. An ope-

rative procedure I deemed unadvisable, and therefore abstained from further treatment. Four weeks afterward the father informed me of the boy's death, adding at the same time that the tumor had grown to about double its former size. An autopsy was not made.

The whole disease was a primary glioma of the retina, which, after perforating the globe, had assumed the characteristics of glio-sarcoma in its external portions, and probably had forced its way, through the degenerated optic nerve and the fissura orbitalis superior, to the brain, and thus induced the fatal termination.

CASE V.—*Bilateral Glioma of the Retina; on the right side probably congenital, with rupture of the eyeball and proliferous growth into the orbit; beginning on the left side.*

Mich. Gramlich's little boy, of Oestringen, was brought to my clinique when 2 years old, in a healthy and well-nourished condition, on the 25th of Oct., 1862. According to the statement of the father, a peculiar bright reflection was seen in the right eye immediately after birth, resembling a cat's eye. The child did not learn to see with this eye, which continued unchanged outwardly until a few months before its presentation at the clinique, when it became very much swollen and a tumor vegetated from it.

Stat. præs. Lids considerably tumefied; somewhat reddened. Eye protruding and degenerated, cancer-like;

cornea only with difficulty still to be recognized. Internally and superiorly a soft pseudoplasma has grown into the orbit.

I performed the operation of *extirpation* of the globe, together with the tumor and the neighboring orbital tissues. These were not all in a process of degeneration as yet; the oblique muscles, and the lachrymal gland especially, were entirely normal.

The specimen was preserved in alcohol, examined at a later period, and again at present, in a perfect and hardened state.

Anatomical Examination.

The eye, considerably enlarged in all its dimensions (Fig. 20), presented superiorly, inferiorly, and posteriorly a very extensive rough tumor, which did not envelop, but reached as far as the optic nerve. A longitudinal section through the tumor showed the interior of the eye filled with a fine granular mass, in which the displaced crystalline (Fig. 20, le), and the lacerated and wrinkled choroid (Fig. 20, ch) were imbedded. There were no traces of the iris and ciliary body. Internally the choroid was bounded by a black pigmented layer of green, translucent, thick-set granules (Fig. 20, ca), which grated like sand on being cut. In the longitudinal section the *optic nerve* had retained its fibrous striæ (Fig. 20, no), did not appear abnormal, and was supported for a short distance by the dilated sclerotic. The *outer tumor* in every part had the same finely granulated appearance as the mass which filled the globe. Under the microscope

it, as well as the contents of the eyeball, revealed a pure *glioma mass* with blood-vessels.

On the *optic nerve I made very many longitudinal and transverse sections, and was considerably surprised to find it entirely normal.* The quantity and size of the bundles of nerve-fibres and the enveloping vascular connective tissue appeared entirely as in the normal optic nerve. But the neighboring *scleral tissue* was loosened by thick-set glioma-cells, which crowded in like ears of maize between the longitudinal fasciculi. Consequently there must have been a rupture somewhere, although I could not discover any on numerous sections.

At the end of the optic nerve and the beginning of the choroid, a narrow, beautifully yellow line (Fig. 20, g. and g_1) ran transversely through the soft pseudoplasma Under the microscope it showed, in a few places, a structure of parallel fibres in which small cells and larger accumulations of nuclei, with round and elongated contours of beautifully yellow color, were imbedded. The coloring matter filled not only the nuclei of the cellular productions, but also their homogeneous protoplasma, so that it was manifestly dissolved in and connected with the cellular elements. In general, these small yellow elements were situated in the pure pseudoplasma of small cells in such a manner that they were closely packed in macroscopically visible lines, but were also scattered in their vicinity. Very many of the glioma-cells themselves were of a yellow color. Aside from these, many small granules of a *deep yellow* were disseminated throughout the mass, giving the impression of

their having escaped from the cellular elements. Near these yellow productions, *dark, reddish, brown, and even black granules* could be discovered, resembling the yellow exactly in form. All this gives rise to the presumption that the coloring matter here found proceeds from that of the blood after hæmorrhages, which in glioma are not rare, and, indeed, in Case VI. were present in great quantity.

The *choroid*, as in the other cases, proved to be changed in the most different degrees to connective tissue. The blood-vessels were few, here and there easy to distinguish (Fig. 21, v). The stroma (Fig. 21, str) had lost all of the stellate cells, as well the pigmented, which usually are very resistant, as the unpigmented. Round and irregularly black accumulations of pigment were scattered throughout the tissue in great number, and internally (Fig. 21, p) so densely that the pigmentary epithelial layer could still be recognized upon it. From the surfaces, both of sclerotic and retina, the thick-set glioma-cells (Fig. 21, gl, gl) pressed upon the tissue and penetrated it in many places.

Sections through the sandy layer (Fig. 20, ca) manifested an extraordinary abundance of *calcareous glioma clusters*. These were recognizable at first sight by their shining, bottle-green color (Fig. 21, ca), somewhat less transparent than the non-calcareous clusters, and, indeed, had precisely the same appearance. It was remarkable that they nearly all lay imbedded in choroidal tissue; only exceptionally were calcareous spots to be seen in the general glioma mass, and when present they were

always in the vicinity of the choroid. In the outer tumors I never could discover any. The calcareous infiltration was so fine that the granules could not be seen with the ordinary magnifying powers. The structure of the glioma, with its cells and intercellular substance, remained unchanged in the petrifying process, and when the calcareous deposits were dissolved out by acids, they again assumed in color, transparency, and shape entirely the appearance of non-calcareous clusters. Acids extracted the calx without the liberation of gases; consequently it must have been in combination with phosphoric acid.

The *crystalline* showed nothing abnormal under the microscope, although it was enclosed in the pseudoplasma; a substantiation of the great power of resistance of its capsule.

Progress of the Disease.

The wound left by the extirpation healed with very little suppuration, and so slight a fever that the little patient could be dismissed in eleven days. But on examination of the other eye there appeared, in the depths of the pupil, externally and superiorly, a light-yellow reflection (*Beer's amaurotic* cat's-eye). The pupil was moderately dilated, displaced somewhat in an upward direction, and still slightly movable. With the ophthalmoscope a yellow mass could be discovered in the fundus of the eye, upon which only a few of the retinal vessels were still to be seen.

Of the course and termination of the malady, the child's father writes to me as follows: "When I arrived

home the eye was healed, as you had seen; but after the expiration of four weeks it became inflamed, and the flesh grew out from it as large as a child's fist. This growth had pushed the child's nose to one side, and had bled severely several times. In this state we kept it until the 10th of January, 1863, when the Almighty called it to himself."

Case VI.—*Eye gliomatously degenerated, with Perforation through the Cornea.*

On my visit to Würzburg (March, 1867) I had the opportunity, through the kindness of Prof. Von Recklinghausen, of examining the left eye of a boy, æt. 2½, after it had been hardened in spirits for two weeks. The assistant at the surgical clinique, Dr. Stengel, kindly communicated to me that four or five months previous to the extirpation (7th of March, 1867) by Prof. Sinhart, nothing unusual had been observed in the eye by the parents. At that time it began to appear opaque, then became red, protruded, and bled frequently. Before the extirpation the presence of exophthalmos, and of a soft, reddish intumescence, situated upon the globe and bleeding easily, was confirmed.

Prof. Von Recklinghausen separated the globe and the tumor by a longitudinal section, and in an examination immediately afterward proved the remarkable displacement of the contents of the globe, and also a calcareous spot near the sclerotic, adding that the round cells

of the pseudoplasma appeared very large to him for glioma-cells on the fresh specimen.

When I examined the globe it was very much hardened, and appeared in the form represented in Fig. 22. The several parts were not recognizable on first inspection, so that it required the aid of the microscope to establish the identity of some. The relations represented in Fig. 22 presented themselves, without doubt, in the following manner: the sclerotic (Scl) uninterruptedly enveloped the posterior portion of the globe, and continued its course as usual in the sheath of the optic nerve. The mass enclosed by the sclerotic was a soft, here and there greenish matter, in several places (a a) of a reddish color; only in one place (b) there lay a whitish-yellow, granular, and hard substance about the size of a pea, which grated on being cut, and felt like fine grains of sand in a soft cement.

In the degenerated contents of the globe, the choroid (Ch) could be recognized as a black, undulating line, $\frac{1}{4}$ to 2 mm. in width. It was evident that it was compressed in different directions, and therefore presented toward the surface oblique and semitransverse, instead of truly transverse sections. On one side lay the crystalline (le), almost entirely enclosed in the ciliary body and iris; the cornea (Co) at its side, and separated from it by a layer of pseudoplasma. Exactly opposite to the optic nerve there was a wide opening in the choroid and the sclerotic, the latter terminating in a point in the surrounding pseudoplasma. In the vicinity of the entrance of the optic nerve, the choroid was divided; but it is evident that the defect only represented the choroidal aperture

after having been separated from the sclerotic. Of the retina, vitreous and aqueous humors, there was nothing to be seen. I also sought in vain for the ciliary muscle.

The microscopical examination revealed the whole pseudoplasma, internal and external to the choroid, as a pure glioma. Cells, from once to twice the size of the blood-globules, were seen tolerably close together, so that an amorphous connecting substance could be discovered, especially with the binocular microscope. This instrument separated the several elements distinctly and stereoscopically in less fine sections, and permitted the substance in which they were imbedded to be recognized better as such. The perforating mass (m) on the outer side of the sclerotic consisted entirely of the same elements. Remnants of blood-vessels were to be seen abundantly in the pseudoplasma, both interior and exterior to the capsule of the eye. Numerous red spots were discovered beside them, in which the glioma elements were stained by the dissolved coloring matter of the blood, and were also mixed with mutilated blood-globules.

The choroid was completely destitute of its peculiar structure, and degenerated to connective tissue (Fig. 23, str). In the delicate, parallel-striped tissue the fusiform figures and elongated, irregular, black pigment spots were distinct, whilst from both sides the proliferous glioma-cells approached and penetrated it (Fig. 23, gl, gli). Near by, *calcareous glioma clusters*, having the same characteristics as those of the preceding case, were situated.

Three months afterward, Prof. Von Recklinghausen had the kindness to send to me a report of the autopsy made on the 24th of June, 1867, $3\frac{1}{2}$ months after the operation.

Of the report, especially interesting in regard to the brain and spinal cord, I extract the following:

Brain.—Dura mater tense; cerebrum bulging very considerably. On the convexities of the *pia mater*, small, white, miliary, medullary spots, to the left spread out to larger patches, several $\frac{1}{2}''$ in diameter, confluent, the larger ones on the branches of the fissure of Sylvius. The blood-vessels of the *pia mater* are concealed by them. Several of these patches are very vascular in their centres. The left border of the brain is almost entirely occupied by extravasations, and near it a yellowish œdematous infiltration of the *pia*. In the sinuses, lumps of coagulated blood. The *olfactory* nerves transformed into a reddish, very white, medullary, fragile mass, which is continued as far back as the posterior surface of the *dorsum ephippii* and penetrates into the bones. On the posterior surface of the *clivus Blumenbachii* this reddish-white, medullary mass is still present upon the nerves, especially on the right trigeminus. The dura mater covering the *Gasserian ganglion* bulges considerably. The right auditory, facial, vagus, and glosso-pharyngeal nerves are of a similar texture. On the base of the cerebrum this mass is still continuous with the nerve trunks, and indeed the two *trigemini* increase to large tumefactions, concealing the *pons*. The *pia mater* of the pons also contains similar infiltrations. The *optic commissure*

is completely enveloped in the mass. Medullary, very vascular tumors enclosed in this apoplectic pia mater are seated on the superior and inferior surfaces of the cerebellum. The *velum interpositum* is tough, and contains an abundance of medullary clusters. From it a similar infiltration proceeds toward the left choroid plexus. Aside from these, similar tumors exist in the substance of the third ventricle, in the roof of the fourth, imbedded in the cerebellum; on the floor of the third, to the left, a slightly hæmorrhagic tumor, projecting from the crus cerebelli. The brain itself very soft, anæmic, but no deposits in the substance of the hemispheres. Central ganglia unaffected.

Spinal Canal.—Inferior portion of dura mater bulging and very tense; in the lumbar region it was opened, and in this place a very great quantity of medullary substance protrudes. The *cauda equina*, as far as the coccyx, consists of a very thick, soft mass; here, external to the dura, a reddish medullary tissue, which is continuous with the nerve roots through the intervertebral foramina; nothing abnormal on the lumbar plexus. The dura adheres to the pia mater to a very great extent. Only as far as the fourth cervical vertebra are the surfaces of the pia mater and spinal cord normal. In the remainder, as far as the cauda equina, white-reddish or hæmorrhagic medullary ridges conceal the spinal cord; the roots of the nerves are alone visible. They form an unbroken lamina with transverse ridges and smooth surfaces. These ridges are missing in the lumbar portions, and here the spinal cord glistens through the yellowish,

œdematous pia mater. The same appearances are presented for a short distance on the anterior surface of the dorsal portion of the spinal cord. In the cervical and upper dorsal portions of the spinal marrow, this medullary mass is aggregated, particularly upon the roots of the nerves, for only a few medullary, vascular patches cover the median fissure; only a few clusters in the upper portion of the cauda equina, so that it is easy to separate the roots of the nerves; the termination of the cauda equina changed into a thick lump, consisting of a medullary tissue, and the roots of the nerves traversing it. In the upper dorsal portion the spinal cord is strongly compressed from before backward. The posterior columns attenuated, and of an orange-yellow color. The gray substance red and congested. In the middle of the dorsal portion, *the transverse section of the spinal cord itself is angular, trapezoidal* (Fig. 24, m), the entire cord, with its membranes, 15 mm. in breadth and 10 mm. in height. The cord itself, easily separable (Fig. 24, m), is driven forward anteriorly 9 mm., posteriorly 6 mm. in breadth, and measures 4 mm. from before backward. More than the whole posterior half, and considerable portions of both sides of the transverse section (Fig. 24, tu), are occupied by the medullary pseudoplasma.

Eyes and Optic Nerves.—The *left* eye is missing (extirpated on the 7th of March, 1867). Left upper eyelid distended, fissura palpebrarum pushed downward. A cicatricial tissue is seen in it, and a whitish medullary mass under it. The medullary mass is not conveyed by

the *right* optic nerve through the foramen opticum. *The right optic nerve and eye* normal.

The changes in the *remaining portions of the body* were unimportant. We will, however, mention the costal cartilages as rachitic; the right lung adhering throughout, on the left a few bands of adhesion; lymphatic glands of the neck pale, rather large, not distinctly marrowy; liver rather large, otherwise normal.

The *anatomical diagnosis* was: *Glioma of the optic nerve, the pia mater, cerebrum, cerebellum, and spinal cord.*

The *whole disease* was primarily a glioma of the left retina, which had spread along the optic nerve to the chiasma, and then to the right optic nerve and both optic tracts, the roots of the olfactory and other cranial nerves, to the pia mater of the brain and spinal cord to a very great extent; then had continued onward to the peripheral layers of the brain, the ependyma ventriculorum and the neighboring substance of the cerebrum, in like manner to the spinal marrow, especially upon its posterior columns, and finally had attacked the roots of the spinal nerves. *Metastases of glioma*, as in our first case, were not present, but we may assume that the course and termination of Cases II., IV., and V., in which the autopsies are wanting, were similar to those here described.

I cannot be too thankful to Prof. V. Recklinghausen for these observations, which, in addition to their intrinsic merits, form an important verification of the foregoing clinical conclusions.

CASE VII.—*Unilateral Glioma with Perforation through the Cornea; Recidive and Lateral Extension to the Glands.*

Albrecht Steinmann's little boy, of Sinsheim, æt. 2½, presented himself at my clinique Dec. 28th, 1867. The boy was perfectly healthy until the beginning of March of the same year, when he had an attack of scarlatina, complicated with inflammation of the lungs. Eight days later, the mother noticed a yellow reflection in the pupil of the right eye, which was perfectly normal in its external appearance. However, when its power of vision was more carefully tested, it proved to be blind. Already a few days later it suddenly became inflamed; the upper lid was swollen and hung without power of motion; the globe itself became very red and protruded; a great quantity of tears and mucous fluid escaped from the opening of the lids. The child was very restless and irritable. Eight days later, the eye ruptured, emptied itself of its contents, and at the expiration of from two to three weeks, had shrunk to a small, white stump, free from irritation. It remained in this state three months, then became inflamed anew, swollen, ruptured, closed, and contracted again. The inflammatory symptoms diminished, but did not again entirely disappear, as was the case after the first perforation. After a few weeks an exacerbation and subsequent remission of the symptoms recurred, and thus several others, until a fortnight ago the eye enlarged rapidly and projected from the

palpebral aperture in the form of a fungoid, soft, reddish, and easily-bleeding tumor.

In this state the little patient presented himself. His general appearance is that of a perfectly healthy person. The upper lid of the right eye is still somewhat tumefied. The tumor projecting from the palpebral aperture is of the size of a large walnut. Posteriorly, it is continuous, without any discoverable demarcation, with the reddened and swollen tissue of the conjunctiva.

It was pronounced a glioma, and extirpated the next day. After having secured the upper lid, the conjunctiva was incised for a short distance and the sclerotic brought to view. I then enucleated this, posteriorly, from its capsule, removing a broad ring of the tissue which covered it anteriorly and surrounded the tumor. As, on examination, we could not discover any diseased portion remaining, and as the hæmorrhage had ceased, a simple compress of lint was applied.

The eye was then divided from before backward (Fig. 25). The fibrous capsule, moderately distended, had been perforated at the cornea in such a manner that there was left only a ring of the latter from 1 to 2 mm. in breadth (Fig. 25, co). The encephaloid, whitish-red mass which completely filled the interior of the sclerotic, projected through the opening. Its posterior portion was whitish; its anterior and extraocular reddish, and here and there (Fig. 25, hh_1) colored of a dark red by recent hæmorrhages. Of the inner membranes of the eye there could only be recognized a small remnant of the choroid, or rather of the *lamina fusca*. This encompassed the en-

cephaloid as a delicate blackish membrane (Fig. 25, ch) and could not be separated from it easily, but from the sclerotic, excepting at both ends of the optic nerve (Fig. 25, mm_1), where the encephaloid, in about 2 or 3 mm. of thickness and 8 mm. of length, became tougher and glassy, and was more closely connected with the sclerotic. The black encircling membrane was also less distinct upon this portion.

The microscopical examination revealed small cells similar to the retinal granules, with a transparent intercellular substance in the entire intra and extra ocular encephaloid. The cells were finely dotted, and, either with or without reacting agents, nuclei could partly be recognized, which in general were very large. The posterior tougher layer surrounding the optic nerve was entirely of the same structure, so that the denser composition of the connecting substance could not be distinguished by any outward sign. The black membrane adjacent to the sclerotic was composed of delicate fibres and large, frequently mutilated, jagged pigment cells, upon which the small elements of the neoplasma accumulated.

This, therefore, was another pure *glioma*, which must have proceeded from the retina and destroyed the internal elements of the eye, and afterwards the cornea. The posterior, tougher portion is very similar to the condition we found in Case II., to which the present case can be regarded as a later stage. It was remarkable in the course of this disease that all symptoms of irritation should disappear, and that the eye should remain shrunken three months after the first perforation. It is probable that

the lens, and perhaps the greater part of the degenerated contents of the globe, were then discharged, and that the remainder only in three months again accumulated to such a quantity that the capsule again became extended, irritated, and ruptured. I can easily conceive that after perforation a complete discharge of the contents of the globe may take place, and a long interval ensue during which the stump remains free from irritation, and, consequently a cure by the powers of nature may for a time be simulated. In a case communicated by *Sichel*, and which will be described later, a cure by perforation and subsequent atrophy of the globe is asserted to have been permanent.

The wound healed rapidly, and the boy was dismissed from the hospital 7 days after the operation; his orbit being lined with pure conjunctival tissue.

On the 13th of March, 1868, he presented himself again; the lids were widely separated by a lardaceous mass, which was everywhere covered by healthy, though very congested conjunctiva. In the region of the parotid a soft, subcutaneous, roundish tumor, not quite the size of a hen's egg. It had been observed already at the time of the first operation, harder and movable, and about the size of a bean, and had been regarded as a swollen lymphatic gland. In the submaxillary region a number of smaller, hard, movable clusters of about the size of a bean could be felt, and were probably swollen lymphatic glands. The boy still appeared fresh and rosy, had a good appetite, slept well, but was very irritable.

On the 14th of March, 1868, I extirpated the entire or-

bital tumor. In no place had it grown to the periosteum, and therefore it could be perfectly enucleated with facility. It was of anatomical interest to me, for I did not intend to remove the lymphatic glands which had already become attached and degenerated, and therefore did not expect a local annihilation of the disease. Nevertheless, I thought that the extensive orbital tumor, after its perforation, would in a short time be, and perhaps even now was, a very burdensome and frightful malady to the boy himself, and to his relatives, and that it would be most advisable to keep it within bounds for a short interval, until the generalization of the affection, which had already begun, should put an end to the life of the little patient.

The extirpated tumor was the size of a goose's egg, appeared white and lardaceous, was soft but not diffluent. A white glutinous juice could be expressed and scraped off. Still there were tougher tissues in it which offered considerable resistance, so that it no longer was the white medullary mass in all portions, as at the time of the first operation, but from its microscopical appearance might have been considered a carcinoma: its consistence, lardaceous and tough, yielding a glutinous juice on pressure, and a fibrous stroma remaining. A few tough, white, fibrous bands divided the whole mass into lobules, and may be considered remnants of the connective tissue of the orbit, which had become compressed by the sprouting masses. But under the microscope the tumor revealed itself as a perfectly pure glioma, peculiar only in an extraordinary abundance of blood-vessels. The cells were

small, refracting light strongly, finely and uniformly granulated, and having an envelope of protoplasma scarcely discernible. The intercellular substance hyaline and rather abundant. The blood-vessels constituted a broad web of large canals, whose walls plainly manifested a longitudinal direction of fibres. Wherever they were empty the transverse section disclosed an areolar arrangement similar to carcinoma. But that vessels alone were present could be recognized with certainty upon the fresh specimen; for the textures similar to connective tissue, and devoid of blood, passed directly into the vascular system of canals, which presented the same reticulated arrangement into round and polygonal fields, coming to view the more distinctly the more easily the vessels were discernible by their contents, the yellowish blood-globules. From the larger anastomosing vascular canals there proceeded smaller ones, with homogeneous coats traversing the tissue in every direction. Besides, the difference in the structure of the cellular elements was clearly demonstrated, for in no place did they assume the character of epithelium, but without exception bore the characteristics of retinal granules. The blood-vessels, in this case, formed a frame-work which rendered the mass more consistent than is usual in ordinary glioma, and which, like cancer, permitted the cellular elements to be expressed and scraped off as a thick juice, whilst the blood-vessels themselves offered considerable resistance.

At the time of the operation severe hemorrhage set in, which was easily controlled by plugging the orbit with tinder. I removed this the next day, cleansed the wound

by injection, and bandaged it with lint. As no after-bleeding ensued during the three days following, and the wound granulated nicely, I dismissed the boy from the hospital, at the same time informing the father of the unavoidable and probably speedy termination.

SECTION II.

GENERAL DESCRIPTION OF GLIOMA OF THE RETINA.

The seven cases above described are, indeed, but a limited number, and will not by far exhaust the various phenomena of this disease. Nevertheless, they contain so much of the important and noteworthy, that I cannot omit gathering them into a general description of glioma of the retina. Although the single cases are the principal sources of information, their collection serves to demonstrate the connection and dependence of the various symptoms. I believe I am the more justified in undertaking this, inasmuch as in the description of glioma there is much to be completed; and as no author that I can find in medical literature has examined more closely, and described seven cases from his own observation.

I.—*Pathological Anatomy of Glioma of the Retina.*

The *appearance* of these tumors is very nearly that of a soft, brain-like marrow, which, according to the greater or lesser quantity of blood it contains, is more or less reddish-gray or reddish-yellow. Here and there places also appear tolerably pale, vitreous, or lardaceous—a great homogeneousness of the cellular and connecting substances then being present. As soon, however, as

fatty, calcareous, or other changes set in, the appearance assumes another character. By *fatty* degeneration, for instance, the mass often is of a fluid consistence, and a dirty white-yellow color, so that abscesses appear to be present in it, a circumstance which easily leads to mistakes, on account of the resemblance of the cellular elements of glioma to the pus-corpuscles, especially in a state of fatty degeneration. True fluid intercellular substance, however, as it is in pus, will be found very rarely, but the several groups of the glioma elements are joined by a more compact cement of basement substance. The *consummated or perfected glioma*, in our cases, always manifested the same structure, described by *Virchow* as soft glioma. In a fresh state, fine, granular, or amorphous basement substance, in which small round cells lay embedded at short intervals. The appearance of the microscopical image *Virchow* very aptly compares to ears of maize. The young cells, when fresh, are very near the size of lymph-corpuscles (Fig. 17, b), and have a large nucleus, provided with one or several nucleoli, or are without any. The nucleus is encircled by a narrow ring of protoplasma, without an observable cell wall. When we examine the preparations hardened in alcohol, or Müller's fluid, the cells appear smaller, the nucleus is not to be distinguished from the ring of protoplasma, so that the cells now look like nuclei, or like the granules of the hardened retina. The attempt to demonstrate the proliferation is difficult, since the single cells have altogether the same appearance.

The *intercellular substance* I always found to be homo-

geneous in a fresh state; when hardened it becomes finely dotted, or fibrous. In thicker preparations it appears, comparatively to the cells, to decrease in volume, but in thinner sections of the hardened preparation, when part of the granules fall out, the intercellular substance then appears as a fibrous network (example in Fig. 3, a_1). But also in thicker sections the position of the granules in a not inconsiderable basement-substance can be beautifully brought to view with a binocular microscope, magnifying 200–300 diameters, whilst with the monocular the granules seem to lie closely together, or over each other, and compressed into one plane; with the binocular instrument the preparation stands out in relief, and the position of the round elements before and behind each other, as well as the intervening connecting substance, comes plainly to view. The image resembles, in miniature, the mineralogical specimen of the so-called "*nagelfluc*" or breccia, a conglomerate mass of chalk and silex, which are connected by a granular cement of the nature of sandstone. Aside from these elements, which could *always* be found, blood-vessels alone were present in the tumor, of variable size and number, at first still belonging to the old retinal vessels, later being of new formation.

II.—*Origin, Progress, and Termination of Retinal Glioma.*

Of the origin and progress of encephaloid of the retina, the above cases present a series as beautiful

as can be obtained by collecting all the material furnished to medical literature from the most different sources, to which *they*, however, contribute not an inconsiderable number of new and interesting data. The cases are arranged in such a manner that they form a series of the different stages of development. A few were traced through all these stages. Case I., for instance, offers the best illustration of glioma of the retina till now on record.

In the unextirpated eye of the first case we find the retina, under the typical symptoms of Beer's amaurotic cat's-eye, degenerated to a great extent in its posterior position, and, in consequence thereof, pushed anterior to the posterior focal surface of the eye. The blood-vessels of the internal retinal layers and the level of the inner surface were not markedly changed. In the inverted image this surface could still be seen distinctly (Plate I., ophthalmoscopic drawing); it was only necessary to hold the lens farther from the examined eye. But a homogeneous mass, of granular appearance, yellowish-white color, and semi-globular, projected considerably over this surface. Although I could plainly see the preserved inner surface of the degenerated retina in the erect image, with relaxed accommodation, by means of ophthalmoscopic ocular glasses of 24″ to 18″ positive focal distance, it was necessary to employ glasses of 12″ to 10″ focal distance to accommodate for the summit of the oval mass. Consequently, we infer that the retina was thicker by 0.4 to 0.6 mm., whilst the tumor was 0.8 to 1.0 mm. in thickness, and 3 mm. in breadth, and 4 in length. The

latter dimensions could be fixed by a comparison with the apparent size of the optic disc. (Of the manner of determining the thickness of a tumor, see below, page 104.) This slight advance of the fundus of the eye proves that the retina was not yet separated from the choroid in the primary stage of this affection. Another cause of it is the projection of the glioma into the vitreous, whilst the examination of the other eye showed that the glioma clusters develop on the external surface. Since, however, their extension was impossible in an external direction through the choroid and the resisting sclerotic, they were forced to progress internally. Thereby the inner layers of the retina had, of necessity, to suffer and to degenerate, which was confirmed by the absence of the normal smoothness of the surface and the destruction of the retinal blood-vessels. How long a period may elapse before the retina becomes separated from the choroid by serous effusion (hydrops choroidis internus) is not to be deduced from an examination of the cases before us.

In the other, extirpated, eye of the same patient (Fig. 1), we find the retina totally detached and beset with a number of larger and smaller glioma clusters, which all arise from the outer layers, since we see the limitans interna and the neighboring retinal layers still preserved. The origin of the whole morbid process can be demonstrated to be a proliferous growth of the retinal granules, as *Charles Robin** first described minutely. He men-

* Article Myéloeyte in the Dictionnaire de Médecine of Nysten, 1855, and *Sichel* Iconographie Ophthalmologique, page 584: 1852-1859, etc.

tions one case, upon which *Schweigger** and *Rindfleisch*,† each with one case, followed, having the same views; then *Virchow*,‡ in a general description of retinal tumors, from his own observation and that of others, without detailed cases. The similarity of the elements of the tumor to the retinal granules, led these investigators to the conclusion that this growth was produced by a hypergenesis of the retinal granules. None, however, could follow step by step the development of the hyperplasy so well as was shown in *our* first case. They had cases before them in which nearly all of the retinal elements had already been destroyed, and where the layers of the retina could no longer be recognized. In our first case, however, the origin of the pseudoplasma in a hypergenesis of the retinal granules was proved most clearly. The retina, though everywhere detached, preserved more or less perfectly its different layers, as well in the neighborhood of the ora serrata and the intact optic nerve as also in a few places on the equator. Near the ora serrata this was most evident (Fig. 2). The radiating fibres appear hypertrophied, a circumstance which *Schweigger* also notices, but the granular layers are hypertrophied most, and, indeed, at the expense of the intergranular layer, which is reduced to a very narrow dotted band (Henle's external granular—molecular—layer) by the intruding proliferous granules. The retinal layers, including the columnar, are preserved. The granules, how-

* Archiv. für Ophthal., Vol. vi. 2, page 324: 1860.
† Zehender's Klin. Monatsblätter, page 341: 1863.
‡ Krankhafte Geschwülste, Vol. ii. 18. Lecture, 1864.

ever, encroach upon them (Fig. 2. a), at first, in very limited number, then in such masses that they displace all the retinal layers (Fig. 3. b,b_1). The hyperplasy of the granular layers occurs as well in diffuse form by gradual thickening of the layers (Fig. 4), as in the form of circumscribed tumors (Fig. 3. aa_1) arising from the outer granular layer through simple multiplication of its elements. Such tumors may attain a considerable size—as in Fig. 3—without the layers of the retina, upon which they rest, having been destroyed. After some time this destruction also happens. The limitans interna and the radiating fibres offer the longest resistance. The retinal vessels are annihilated by the formation of the tumor and are replaced by new ones, whilst in diffuse hyperplasies the original retinal blood-vessels remain, as is demonstrated by the ophthalmoscopic image of the unextirpated eye (Plate I). As the disease progresses, the retina disappears in the pseudoplasma without leaving any traces; the tumor producing nothing but the blood-vessels and the glioma-cells (Myélocytes of *Robin*), and their amorphous connecting substance. The tumors now vegetate in the space filled with fluid between the detached retina and the macroscopally normal choroid until they arrive at the latter. The microscopical examination of this and the succeeding case (Fig. 14) proved that the choroid is attacked before the glioma clusters come in contact with it. The changes occurring in the choroid are partly of inflammatory character: transmutation into connective tissue, partly consequences of this inflammation, and of the increased intra-ocular pressure: an atrophy of its tissue,

always present in different degrees, and to which the pigmentary epithelial layer and the vitreous offer the longest resistance (Figs. 5, 6, and 15). In the same manner the stroma of the iris atrophies, the uvea remaining preserved (Fig. 8). The same process can be demonstrated in the ciliary body (Fig. 9).

The extension of the glioma to the choroid is exceedingly remarkable. It takes place in two different ways: by immediate contact and by dissemination of germs. Wherever glioma of the retina touches the choroid, the glioma cells grow into it, causing inflammatory softening with destruction of its specific structure, especially of the anastomosing stellate cells and the blood-vessels (Figs. 21, 15, 23, 9, 8, 6, 5). This immediate transition is to be seen most extensively in the neighborhood of the optic nerve, where the thickened choroid encircles the pedicle of the goblet-shaped, detached, and degenerated retina, as in Cases II. and VII. (Fig. 14. aa, and Fig. 25. mm_1). The glioma-cells vegetate into the choroid, destroying its tissue, with the exception of the pigment-cells, which offer a longer resistance, and are found more or less mutilated and scattered in the mass of round cells. Although this invasion of the choroidal tissue by the pseudoplasma can be distinctly recognized, we find in no place that the original choroidal cells enter into a vegetating process which converts them into glioma-cells. Their increase in number always takes place by self-generation. Like relations are mentioned by *Virchow* alone in a single case (Krankhafte Geschwülste, vol. ii., p. 161, observation). "The marrowy mass filled the en-

tire posterior chamber. A hydropical cavity [as in our second case, Fig. 14. ee] was not present. The intumescence everywhere presented a dense accumulation of cells, mostly round, the largest of which scarcely surpassed the colorless blood-globules in size, but were supplied with relatively large single or double nuclei. In the immediate neighborhood of the optic nerve entrance the otherwise normal choroid (Was it examined microscopically, and not designated as normal by the evidence of the naked eye alone? Author.) was swollen to a layer, about $1\frac{1}{2}'''$ in its greatest thickness, of gray transparent appearance; a very dense proliferation of analogous small cells, mostly round, existed here and between them; in a few places, pigmented elements of the original tissue were still preserved. Sclerotic and optic nerve normal." This description applies exactly to our second and seventh cases, so far as the transition of the glioma to the choroid is concerned; but in these the encroachment seems to have been more extended, since it not only touched the apex of the funnel-shaped retina from one side alone as a simple layer, but encircled it as a thickened disc.

The extension of glioma of the retina by means of disseminated germs could be demonstrated in Cases I. and II. The second case is only doubtfully conclusive, for the tumor may be supposed to have been in direct contact with the choroid before its detachment, after which some portions of it may have remained attached to, and developed on the choroid. The same may be affirmed of one-half of the eye of Case I., but cannot remain valid for the other half. The degeneration of this retina manifested

itself in separate circumscribed clusters, which in their early stages were provided with a smooth covering, not only on the surface facing the vitreous but also on their choroidal surface. They ulcerate in more advanced stages only. This ulceration probably occurred in all the clusters of the eye of Case I. (Fig. 1) no sooner than the retina had already become detached from the choroid by sub-retinal effusion. This was evidently the case in the small clusters (Fig. 1. c) on the inner side, for the largest of these was rough only on a limited portion of the surface, whilst all the others, situated laterally and being smaller, were provided with a smooth covering, the retina being everywhere removed from the choroid as far as possible. From the surface of the ulcerating tumor small microscopical particles may become detached, fall through the sub-retinal effusion upon the inner surface of the choroid, and take root there as germs capable of growth. This development of the most diminutive glioma accumulations I could demonstrate most distinctly in most places of the otherwise normal appearing choroid of the 1st and 2d cases. When the clusters became larger, the choroid acquired a spotted yellow and boss-like appearance, even to the naked eye. Microscopically the development of the diminutive glioma-clusters appeared as before described, and as represented in Figs. 6 and 7. An accumulation of glioma-cells—perhaps a single cell may suffice—fall upon the pigment layer of the choroid, multiply there; some of them penetrate the epithelial layer, and arrive between it and the basement membrane.

Here a long resistance is offered, and therefore they vegetate between the basement membrane and the epithelium, which latter they raise and displace (Fig. 15). The stroma of the choroid, also becoming irritated, undergoes an inflammatory change and is atrophied. Whilst the stellate cells get rarer, those of a more lymphoid character appear in greater quantity, and are disseminated through a substance arranged in parallel striæ. *Cohnheim* * considers these lymphoid cells, which develop in greater or less abundance near the stellate in every healthy choroid, as migrating cells, in analogy to the structure of the cornea. They do not remarkably differ in form from the retinal granules, or from the glioma-cells; still they do not assist in the extension of glioma through the choroid, for, although double nuclei and multiplication of these cells could be discovered, they were, as in choroiditis, constantly in fusiform spaces and in fibrous intercellular substance, never in accumulated, hilly, or maize-like clusters, in which a homogeneous intercellular substance supports the round elements, which is so characteristic of glioma, especially under the stereoscopic microscope.

The glioma-cells are self-generative even after they have penetrated into the choroid. This invasion does not proceed merely from the side, as we have seen it from the natural transverse section of the choroid at the choroidal opening departing from the optic nerve, but also from the inner surface. After the disseminated germs have reached a higher grade of development, the base

* Virchow's Arch., xxxix, 1, p. 49, etc.

ment membrane gives way (Fig. 15) and the mass vegetates into the stroma of the choroid, spreads in breadth and depth, thus ruptures the choroid, and then continues to proliferate in the loose suprachoroidal connective tissue between the choroid and the sclerotic. Thus the former becomes separated from the latter and displaced toward the axis of the eye, undergoing many alterations and disfigurations, but its shreds always remaining recognizable as a black line, the pigment never becoming entirely destroyed. The description by *Rindfleisch* of the case of *Horner*,* in which, together with complete gliomatous degeneration of the retina, a small glioma-cluster had developed in the suprachoroidal tissue, the choroid remaining perfectly sound, I cannot at all explain mechanically if I do not accept a migration of cells through the choroid, or if infecting juices proceeding from the primary tumor did not cause the production of a secondary, somewhat remote cluster. That a minute investigation might have disclosed passages of glioma-cells through the choroid, propagating the pseudoplasma, can only be advanced with reserve, if we consider the well-known exactness of the author. Here, also, a very instructive case of *Graefe's* must be added, although otherwise interpreted: "*A cancerous deposit in the interior of the eye, its primary seat between sclerotic and choroid*" (Archiv für Ophthal., vol. ii., part 1, p. 214). A boy, ten years of age, became blind with symptoms of detachment of the retina. At a later period, yellow, lustrous reflection; exophthalmus produced by a medul-

* Zehender's Klinische Monatsblätter, 1863, p. 341, etc.

lary episcleral tumor. The vitreous chamber filled with a white-yellowish pulp. The retina could be demonstrated only in the vicinity of the optic nerve and ora serrata, becoming lost in the pulpy mass and being degenerated to small cells (elements like those of the granular layers). The choroid atrophied; between it and the sclerotic, abundant deposit of the same white-yellowish medullary mass. A perforation of the sclerotic was not found.

The proliferation of the glioma continues in the suprachoroidal tissue, pushes the ciliary body from the outer surface of the ciliary muscle toward the axis of the globe, detaches it from the sclerotic together with the attachments of the iris, and thus reaches the anterior chamber. This happens first on one side, so that the pseudoplasma is found touching the posterior surface of the cornea in one half of the cornea, whilst in the other the atrophied iris reclines upon it, as was to be seen later in the unextirpated eye of Case I., the ophthalmoscopic drawing of which was taken two years ago. As the disease progresses, the entire iris and the crystalline become displaced toward the centre of the eye, which then is completely filled with the encephaloid, as is substantiated by the cases following. In the interior of the eye all the tissues are destroyed in the homogeneous glioma degeneration, with the exception of the choroid pigment and the crystalline. The tissue of the latter was found intact, although its shape was altered by pressure and its position changed by the destruction of its suspensory ligament (Fig. 20. le). How-

ever, before the pseudoplasma penetrates into the anterior chamber, it fills the posterior space of the eye completely, and crowds the lens and iris forward, until they lie in contact with the cornea (Fig. 18. f).

Nevertheless, the process is not arrested after the interior of the eye is completely filled. *Two ways are open for the exit of the pseudoplasma*,—the *optic nerve* and the *fibrous capsule* of the eye. The latter, for a long time, is an obstacle to the progress of the growth, but finally is also ruptured, either through the cornea or the sclerotic (Cases IV., V., VI., and VII., Figs. 18, 20, 22, 25). The glioma-cells produce a parenchymatous inflammation, with distention and softening, then penetrate into its stroma, separating and absorbing the bundles of connective tissue (Fig. 19). Arrived at the outer surface of the capsule of the eye, the growth vegetates rapidly, attacks the tissues round about, ulcerates, crowds the lids asunder and the globe forward, at the same time penetrating into the depths of the orbit. The further proliferation is then only limited by its decay or by the death of the patient, which is caused less frequently by the failure of the vital forces consequent to the local difficulty than by the development of glioma in the brain, spinal cord, diploë of the cranial bones, and other organs (Cases I., II., and VI.). *Dalrymple* (Pathol. of the Human Eye, London, 1852) mentions one instance, where "a cerebriform tumor was situated in the arm, destroying nearly two inches of the humerus." The changes in the brain and spinal marrow may be regarded partly as direct extension of the retinal glioma, and partly as metastases.

Extension to the lymphatic glands occurred in Case VII. Metastases to the diploë of the cranial bones, with very large tumors beneath the scalp, were described in Case I. and illustrated by Figs. 10, 11, and 12. In the same case metastases to the liver were also present.

The extension of the glioma through the optic nerve sometimes takes place before the interior of the eye is filled with it (Case II.), and continues its growth through the optic commissure. A beautiful instance of the latter,—namely, extension to the brain and spinal marrow, where it was confined especially to the pia mater,—is furnished by Case VI. The glioma-cells first penetrate into the space filled with connective tissue and blood-vessels, between the bundles of nerve-fibres, and then spread in the shape of lumps and ears of maize. The connective tissue and blood-vessels are destroyed by them, and afterward all the fibres of the optic nerve, so that the sheath of the nerve is filled with the glioma mass alone. The optic nerve, when completely degenerated, swells from two to four times its original thickness (Cases II. and VI.). This increase in bulk is not a regular one; but a number of constrictions and protuberances are found in accordance to the resistance,—of longer or shorter duration,—which the pseudoplasma encounters. The constriction is constant at the sclerotic aperture, where the optic nerve is naturally thinnest.

It is remarkable that the eyeball can be filled with glioma masses for a long period (Case III., Fig. 16), or that enormous proliferation can occur externally without the optic nerve being attacked (Cases IV., V., and VI.,

Figs. 18, 20, 25). Both varieties of extension, as well through the capsule of the eye as through the optic nerve, we found in Case VI. (Fig. 22).

In the further progress of encephaloid of the retina, retrogressive metamorphoses set in. There were three varieties of these observed in our cases: fatty, calcareous, and pigmentary infiltration.

The fatty degeneration appeared as a finely granulated infiltration of fat in the encephaloid cells of the amorphous intercellular substance, and as accumulated heaps (Fig. 17. d″, d, d′). The fatty spots were also distinguishable, microscopically, from the light red, transparent, and luxuriantly-vegetating places, by a lighter white color.

The calcareous degeneration (Fig. 21. ca) appeared microscopically as transparent whitish or greenish spots, which were always found in the vicinity of the choroid, never at a distance from it in the remaining encephaloid, or even in the clusters external to the globe. Under the microscope they proved to be glioma clusters, full of finely divided calcareous deposits, which had accumulated in the cells and in the intercellular substance. By acids they could be extracted, without the formation of gases, and the appearance of a non-calcareous glioma cluster was reproduced. Their reaction was that of phosphate of lime. *Charles Robin* was the first to describe both of these degenerations—the fatty and the calcareous.

The pigmentary degeneration from hemorrhage could be demonstrated in the interior of the eye as yellow, and

in the outer portions of the tumor as black, coloring matter. Hemorrhages are very common in glioma, especially in the rapidly vegetating portions exterior to the globe. Since no proliferation or metastasis of the pigment-cells of the choroid is found in glioma, as in melano-sarcoma, the black coloring matter of the outer portions of the tumor can have no other origin than from extravasated blood. It is in form finely granular, or amorphous, and is either in connection with the cells or disseminated singly, or in heaps throughout the intercellular substance (Fig. a).

This production of retrogressive metamorphoses, especially fatty degeneration, leads to the supposition that the growth of the formation, which takes place only through multiplication of its own elements, might be exhausted; a stationary stage, an atrophy, be arrived at which might lead to a spontaneous cure, although never to a restoration of function. *Sichel** asserts that he has seen encephaloid of the retina atrophy. The degeneration thus wholly disappeared by a process of absorption, and no recidive had ensued for ten years. In his collection he also has the eyes of a child, in which he recognized the encephaloid of both retinæ immediately after birth. At first the disease progressed with equal rapidity in both eyes; afterward one ruptured, and became atrophied; the other developed to a very voluminous tumor, and after death, which followed at the expiration of one year, it presented in the autopsy all the signs of an encephaloid in its last stage. On the other hand, the

* Iconographie Ophthalmologique, p. 573.

shrunken eye, first mentioned, manifested no traces of encephaloid. It would be of great importance if this observation were confirmed by others. Temporary atrophy, after rupture of the cornea and apparent cure of the glioma of the retina, were observed in Case VII.; a local recidive set in three months afterward; the globe again enlarged, and an immense and fatal glioma developed.

III.—*Symptomatology of Glioma of the Retina.*

I agree with *Mackenzie* and *Sichel* in dividing the course of glioma of the retina into three stages, but have adopted different boundaries from those of the above-mentioned highly meritorious ophthalmologists.

The first stage produces no change of form or tension in the eye. In the fundus there can be seen by the aid of artificial reflected light, or even with the naked eye alone, if the face of the patient be turned toward the window, a white or more frequently yellow reflection, mostly always of metallic lustre, which *Beer* has designated *the amaurotic cat's-eye.* The examination is easier and more exact, if the pupil be dilated with atropine. If now the degeneration is still diffuse, or if the several clusters are small, the retinal vessels can be recognized with the ophthalmoscope, as well as the more or less boss-like surface, which is smooth, as long as the internal layers are intact and tightly covered by the limitans. This is a necessary condition for its *lustre*, the *color* depending upon the amount of blood contained, and the

coloration of the subjacent parts which mingle the direct rays from the surface with diffuse colored light. The lustre diminishes the more the surface becomes granular and rough, which occurs when the clusters project and ulcerate internally. These relations are illustrated in the ophthalmoscopic image of the non-extirpated eye of Case I. (Plate I.). By examination of the upright image, with relaxed accommodation, and with different grades of the weakest convex glasses, the position of the degeneration in regard to the posterior focal surface of the eye, —or, in other words, the thickness of the tumor,—can be computed. In an emmetropic eye, an emmetropic, and even an ametropic examiner, with compensating glasses can, with relaxed accommodation, obtain an exact upright image of the fundus of the eye. If a tumor rises on the ocular fundus, the rays from its surface leave the cornea with a divergence, increasing as the tumor becomes thicker. If the examiner now keeps his accommodation relaxed, he must make the divergent rays proceeding from the tumor parallel, by placing convex glasses behind the ophthalmoscope. *The strongest convex glass, with which the surface of the tumor is distinctly visible, determines the divergence of the recurrent rays.* If we assume an inverse course of the rays, and allow a bundle of parallel rays to fall upon the auxiliary convex lens, it meets the cornea with a convergence determined by the focal distance of the lens, and the rays are collected upon the surface of the tumor in the examined eye. The virtual focus (p, Fig. 70) of the rays falling upon the eye, and made convergent by the convex lens, and their

real focus (t, Fig. 70) upon the surface of the tumor in the eye, are two conjugate focal points of the dioptric system in the examined eye. Let, in Fig. 70, the focal distance of the auxiliary lens be f_1=op=hp, disregarding the small quantity oh, being the distance of the lens from the principal plane of the eye; let, moreover, f_2=ht be the focal length of the refracted rays the focal point of which lies on the surface of the tumor. Knowing the principal focal lengths of the eye, F_1 and F_2, by physiological inquiry, and f_2 by ophthalmoscopic examination of the diseased eye, we can determine f_1 by making use of the general formula

$$\frac{F_1}{f_1} + \frac{F_2}{f_2} = 1.$$

For F_1 and F_2 I insert the values derived from my own measurements on the living eye (Arch. f. Ophthalmol., vi., 2, p. 40), viz.: $F_1 = 14$ mm., and $F_2 = 18.5$ mm. After having found f_2 we subtract its value from that of F_2, and in the remainder have the thickness of the tumor, and, consequently, the projection from the posterior focal plane of the eye which, in the emmetropic eye, corresponds to the columnar layer. In order to make this method practicable for all without calculation, I have determined the distance of the second focal point (t) from the retina for the ordinary spectacle glasses which are to be placed behind the ophthalmoscope. It corresponds to the shortening of the axis of the eye in equivalent grades of hyperopia; therefore, for the sake of brevity, I shall make the thickness of the tumor equal to the shortening of the axis of the eye, and

the number of the convex auxiliary glass to the corresponding grade of hyperopia (H).

H. = $\frac{1}{5}$	shortening of the	axis of	the eye	= 1.8 mm.
" = $\frac{1}{6}$	"	"	"	= 1.5 "
" = $\frac{1}{7}$	"	"	"	= 1.3 "
" = $\frac{1}{8}$	"	"	"	= 1.2 "
" = $\frac{1}{9}$	"	"	"	= 1.1 "
" = $\frac{1}{10}$	"	"	"	= 1.0 "
" = $\frac{1}{11}$	"	"	"	= 0.9 "
" = $\frac{1}{12}$	"	"	"	= 0.8 "
" = $\frac{1}{14}$	"	"	"	= 0.7 "
" = $\frac{1}{16}$	"	"	"	= 0.6 "
" = $\frac{1}{18}$	"	"	"	= 0.52 "
" = $\frac{1}{20}$	"	"	"	= 0.45 "
" = $\frac{1}{24}$	"	"	"	= 0.4 "
" = $\frac{1}{30}$	"	"	"	= 0.32 "
" = $\frac{1}{40}$	"	"	"	= 0.24 "
" = $\frac{1}{50}$	"	"	"	= 0.19 "

(1 Paris inch being equal to 27 mm.)

If *hyperopic eyes* are affected with intraocular tumors, the grade of shortening of the ocular axis corresponding to the hyperopia is to be subtracted from the thickness of the tumor, whilst in the *myopic*, a corresponding addition is to be made, in order to obtain the real thickness of the tumor or plastic exudation.

Should the pseudoplasma extend further forward, its shape and position can be demonstrated by examination with reflected light. For this I recommend direct rays of the sun, employing a convex lens or the ophthalmoscope as the means of illumination. The purest and most distinct view is obtained when, by means of a heliostate

in a dark room, the direct rays of the sun are thrown into the interior of the eye with a convex lens or with the ophthalmoscope. The image is best seen in relief by aid of a binocular ophthalmoscope, which can be employed for examination both of upright and inverted images, the latter with especial advantage by means of strong convex lenses before the eye. If this be held at a considerable distance from the examined eye, an inverted image both of the fundus of the eye and the iris is obtained, and consequently the distance of the former from the pupillary level can be estimated. As long as the pseudoplasma remains small, only a portion of the fundus will be occupied by it and have the specified characteristics, the other portion appearing as usual and retaining the power of vision. The defect in the field of vision can be determined if the patient is of sufficient intelligence.

The refracting media remain clear for a long period in retinal glioma; even the vitreous becomes opaque only after a long interval.

We *may begin the second stage of the malady when the tension of the eye is increased by rapid growth of the tumor.* Then also *the first symptoms of irritation and inflammation begin.* The lens and iris are carried forward toward the cornea; the pupil becomes dilated, sluggish, oval, and immovable; the iris dirty, faded, and atrophied. The episcleral vessels are tortuous and distended; the lens and anterior chamber become cloudy; the tumor penetrates into the latter; the cornea becomes vascular, opaque, and softened; the conjunctiva

and eyelids grow red and tumefied. Then pain in the eye and its vicinity sets in as in glaucoma. These inflammatory symptoms may exacerbate periodically and remit, but after every attack the eye is somewhat worse. It now becomes *enlarged and projects* on account of the attenuation and dilatation of the sclerocorneal capsule.

Now begins the third stage, in which the pseudoplasma passes beyond the limits of the interior of the globe, either by extension through the optic nerve to the chiasma and the brain, in which case blindness of both eyes and symptoms of tumor of the cerebrum—viz., irritability, headache, twitching of the muscles, vomiting, and sopor—institute themselves; or by *perforation of the cornea or sclerotic*, after which the growth, for a longer or shorter period, vegetates beneath the conjunctiva in the orbit, but then matures and ulcerates. Ultimately, sloughing of the whole pseudoplasma and shrinking of the globe follow, whereof, however, I know of only one case related by Sichel. Mostly the pseudoplasma now develops more rapidly, attacks the surrounding tissue, and appears as a white mass, vegetating luxuriantly, bleeding frequently and freely, forming tumors on the cheek, nose, and forehead, and causes death by exhaustion, if simultaneous invasion of the cranium, probably the more usual occurrence, does not induce the fatal result under symptoms of paralysis and coma.

IV.—*Occurrence of Retinal Glioma.*

Encephaloid of the retina may be congenital, as our first and fifth cases demonstrate. In Case V. it was noticed by the parents immediately after birth, and in

Case I. the parents had also remarked it in the first weeks; and considering the slow growth of glioma in its first stage, we may assume that the degeneration, which in the child of eighteen weeks had produced tumors so considerable in size, must have had a longer existence than the brief period of the patient's life. It has also been observed early in life by other physicians. *Mackenzie*, for instance, records one of the ninth week, in which the parents asserted that they had noticed the yellow reflection in the pupil already in the fifth week.

All the cases above described relate to *children* under five years of age. Medical literature contains cases which refer to adults, but none of them appear to me to be indubitably the affection here described. All physicians of large experience agree that encephaloid of the retina occurs much more frequently in childhood than in adult age.

Occasionally, glioma of the retina appears *simultaneously in both eyes*, as was seen in both our congenital cases (I. and V.). In both, this circumstance is worthy of mention, that the optic nerve of the more diseased eye was found healthy after the enucleation of the globe —undeniable evidence that the malady had not spread from one nerve-trunk along the chiasma to the other, and the retina of the other eye—but, as the section of the first substantiated, had developed as a primary and independent disease in both retinæ. Hence, an exaggerated impulse to the development in the interstitial tissue of both retinæ was present already in fœtal life, and had manifested itself partly as diffuse, partly as

circumscribed (tumor-forming) hyperplasy of the retinal granules.

That the encephaloid is *hereditary* has not been remarked, and *could only* be demonstrated in a case where an individual afflicted with an encephaloid, and cured, either by atrophy or operation, survived and had descendants. No such case is on record, and no observation that this degeneration had occurred in any of the ancestors is reported. However, there are several very remarkable examples known, where different children of the same parents suffered from encephaloid of the eye. *Lerche** relates that of a family of seven children, four were attacked by this disease; and *Sichel*† describes and sketches cases, where in one family four children out of five died of encephaloid. *Von Graefe* also (Archiv für Ophthal., x. 1, p. 220) relates that a girl of three years had been operated on for soft sarcoma whose sister died six to eight years previously, likewise in childhood, of a very luxuriant cancer of the eye. It strikes me that boys chiefly (six of our seven cases) are subject to retinal fungus, and I should wish to direct the attention of my professional brethren to it.

In relation to the immediate or remote *causes* of glioma of the retina, nothing is positively known. Trauma is mentioned as a cause; still, none of the observations are exact. Wherever *trauma* is indisputable, as in a case of *Sichel's*, the diagnosis is more than doubtful; and when the diagnosis is positive, the trauma

* Vermischte Abhandlung aus der Gebiete der Heilkunde.

† Iconographie, pp. 574 to 581.

appears to be purely accidental. If we search for it, we will not be at a loss to find in children a fall or a blow as the cause, especially as this affection never manifests itself externally in its early stage. Scrofulous constitution is also advanced as predisposing; this, however, is not confirmed by my own observations.

V.—*Diagnosis of Glioma of the Retina.*

The differential diagnosis of glioma of the retina has, indeed, as that of all other tumors, its difficulties during the lifetime of the patient; still, I should think it hardly possible to make an error, if an early and attentive examination be bestowed upon it.

Firstly, I consider glioma of the retina a disease of childhood, if not exclusively, at least in the great majority of cases. All well-described and positively reliable cases in medical literature refer to children. The two cases of glioma, or glio-sarcoma, in adults, of which *Von Graefe* makes mention in his Archives of Ophthalmology (1866, vol. xii., part 2, p. 239 to 244), cannot be substantiated. In the second of these cases the autopsy was not made, and the first I, supported by a case observed by me in its origin, and upon which an early enucleation was performed, consider from the beginning as a choroidal sarcoma. It proved in an autopsy, undertaken by *Iwanoff* * at a later period, to be a sarcoma. Hereafter I shall discuss this important case more minutely under the differential diagnosis of

* A. Mooren, Ophthalmiatrische Beobachtungen, pp. 35 to 40. Berlin: Hirschwald. 1867.

choroidal sarcoma. I do not wish to say that glioma of the retina does not occur in adults; for this, the number of cases we have observed is much too limited. Nevertheless, it must awaken our suspicions that until now we have no positive case occurring in an adult.

Glioma cannot be mistaken for other tumors of the *retina*, since they appear never to occur. There are in my collection eighteen intraocular tumors which I had observed during lifetime; seven are glioma of the retina, and the remainder sarcoma of the choroid. I am far from wishing to generalize deductions from these cases. My search in medical literature confirms as far as the diagnosis can be formed from the descriptions of the cases and not from the names given to them. The easiest *to mistake* is glioma of the retina for *unpigmented sarcoma* of the choroid. To this is added that they occur also in early childhood. The last person in whom I observed a white sarcoma of the choroid, was a boy of six years—all the others were considerably older. The sarcomata of aged people were invariably melanotic. Inexplicable to me is a remark of *Mooren*, in his Ophthalmiatrische Beobachtungen (p. 34), according to which he affirms to have observed melanotic tumors more frequently in children than in adults. Unfortunately, he gives neither a description of the disease nor the results of post-mortem examinations of this ocular affection, which is well worthy of our attention. The diagnosis of melanotic sarcoma is not particularly difficult. Aside from the age of the patient, glioma of the retina can also be distinguished from a white sarcoma of the choroid most

always by its *ophthalmoscopic image.* 1st. The former, in its early stages, is invariably of a *vivid, often metallic and gold-yellow lustre,* which I could not discover in sarcoma of the choroid, which always appears dull white or feebly yellowish in color. The reason of this difference is, that in glioma the posterior portion of the retina becomes expanded, stretching the limitans interna tightly and without *small wrinkles* over the inner layers, and thus causes upon it a brilliant reflection of light; whilst, in sarcoma of the choroid, the retina is either detached, and in this case appears of a dull gray or blue color, or clothes the pseudoplasma in irregular folds and wrinkles, a condition not adapted to a brilliant reflection of light. 2d. In the early stages of glioma the characteristic ramifications of the retinal vessels, and these alone, can be recognized on its surface; whilst in sarcoma of the choroid an altogether irregular branching of the vessels—new formations—and numerous extravasations are seen. Consequently, the ramifications of the retinal vessels and their peculiar characteristics become entirely obliterated. I deduce these symptoms from cases of my own observation in which the diagnosis was confirmed by post-mortem examinations. 3d. Glioma of the retina begins either as an extended surface degeneration, or as a formation of numerous small clusters, which coalesce soon after and spread rapidly from the optic nerve entrance to the ora serrata; whilst white sarcoma of the choroid appears, from the beginning, as a single round or oval intumescence of considerable size, which remains circumscribed for a long time, so that it is still surrounded on all sides by the sen-

sitive retina. I watched a circumscribed scotoma in the field of vision in a sarcoma of the choroid for months, whilst *early* defects extending to the periphery must accompany retinal glioma.

In later stages, when total blindness and detachment of the retina have ensued in both, glioma distinguishes itself by a manifest yellow or ochre-yellow color, which commences close behind the lens; whilst sarcoma appears of a dull white or generally whitish-gray, and if pigmentation has occurred, of a dirty gray and grayish-black, dotted in some cases. The detached retina is rigid in glioma, movable in sarcoma when not adherent to it, in which case it still allows the blood-vessels and color of the tumor to be seen through its tissue.

For the study of these peculiarities I repeatedly recommend the employment of direct sunlight, which is best accomplished by means of a heliostate in a dark room. Many a valuable discovery will, without doubt, be made with it. If, for instance, we are able to determine by a differential diagnosis whether an eye is blind by a malicious growth or by one with a tendency to become so, or, on the other hand, by a morbid process harmless to the general organism, our treatment, dependent on the definite solution of this question, may rescue life.

There is a large number of morbid changes in the eye, non-inflammatory and inflammatory in their nature, *which may be mistaken*, now and then, *for glioma or sarcoma. The former, the non-inflammatory, especially the simple detachment of the retina*, can scarcely be taken for retinal glioma, since the movableness and dull grayish-blue

color distinguish them sufficiently from the diffuse and partial, yellow shining, dense, and nodular gliomatous degeneration of the retina. Where only a portion of the latter is attacked by the degeneration, and the remainder detached as usual, the yellow mass will invariably be seen shining through, if we make use of very strong illumination. We may add that simple detachment of the retina consequent to the well-known diseases of the fundus, sclero-choroiditis posterior, other choroidal difficulties, and opacities of the vitreous, according to our knowledge, was *never* observed in children; glioma of the retina *only* in children.

In certain cases, as *Alfred Graefe** has demonstrated, the distinction must be very difficult between glioma and cysticercus, with the thickening of the retina dependent on it. I should wish to state that in glioma the characteristic blood-vessels of the retina are preserved, whilst they disappear in other hyperplasies. *Alfred Graefe* asserts that, in his case of cysticercus, the advanced fundus glistened opal-like, but that the retinal vessels were not to be seen in their peculiar ramifications. In the great majority of cases, the progress of the disease and the characteristic features of both affections will enable us to make a positive diagnosis.

Of the various consequences of *inflammatory* processes in the interior of the eye, suppurative choroiditis, after cerebro-spinal meningitis, as we had abundant opportunities for observing in our epidemic of last years, is most likely to be mistaken for retinal glioma. Nev-

* Zehender's klin. Monatsbl., 1863, pp. 231–244.

ertheless, this error cannot be persisted in, if a minute examination be made. The fundus pushed forward by accumulations of pus, which cover the inner surface of the choroid like a capsule, and are bounded by the the retina, which is changed by suppuration, but still continuous in its tissue, reflects light very strongly after the absorption of pupillary and vitreous opacities, but is not yellow and glistening, but white and dull. Blood-vessels can be seen on it only exceptionally, and then do not correspond to the ramifications of the retinal vessels. Though belonging to them, they may be new formations, as are found frequently in the purulent membranes which originate in the ciliary body and extend behind the lens. In this and other inflammatory processes, we are additionally guarded from mistakes, to which the first impression of the condition left by the inflammation might lead, by the history of the case, and the constant results of inflammation, viz.: small grayish-brown synechiæ, the iris often pushed forward, and the globe smaller and of diminished tension. A case (*Lancet*, 1854) of a child of five months with chronic iritis, proves that mistakes may happen even to very experienced oculists, by disregarding the history and the complex of symptoms. The pupil gradually acquired a yellowish color, which induced *Messrs. Dixon, Critchett, and Bowman* to assert the presence of an encephaloid in its primary stage. The extirpated eye, examined by *Clarke*, did not show any trace of carcinoma, but made it evident that the yellowish discoloration of the pupil was due to inflammatory

products deposited around the capsule of the lens. That we, now that physical diagnosis and pathological anatomy of diseases of the eye are better understood, are less liable to make erroneous diagnoses, especially if we are able to appreciate the tension of the globe, is evident as well in this as in other branches of ophthalmology.

VI.—*Prognosis of Glioma of the Retina.*

The prognosis of retinal glioma is not of a consolatory nature. In well-established cases, the results have been, probably without exception, of a fatal character. After perforation, rapid extension of the pseudoplasma and death from exhaustion or hemorrhage. In other cases, extension to the brain, or simultaneous development of cerebral glioma, before the local affection has reached a high degree of development, and fatal termination under cerebral symptoms, as in our second case. Earlier or later, appearance of local relapses and consequent death, as in Cases IV. and V. The prognosis, therefore, must be set as very unfavorable.

Nevertheless, the disease cannot be condemned as entirely hopeless. The anatomical facts, first acquired by *Ch. Robin*, and then so lucidly described by *R. Virchow*, demonstrate that the proliferation of a circumscribed layer of tissue is not necessarily a malignant process, as is the case with veritable cancerous growths consisting of a stroma of connective tissue, containing epithelial cells in its areolæ. To this, the consolatory

fact is added, that the vegetation of the retinal granules occurs in an organ admirably closed by a very dense fibrous capsule. Thus, for a long interval, an effectual obstacle is set to its extension to the neighboring parts, for we find that the only outlet from this inclosing capsule, the optic nerve, does not at all frequently become encroached upon by the pseudoplasma, and generally only at a very late period. That glioma germs, however, easily become disseminated in the tissues adjacent to the retina, and then develop to similar new, homogeneous vegetations, the case of *Horner-Rindfleisch*, and our own first and second cases, give anatomical evidence. The direct transition to the choroid is also anatomically demonstrated by our cases, Schweigger's, and that of *Virchow*. That and how the sclerotic is attacked, is also shown in our cases (see Fig. 19); and numerous other observations prove that the cornea and sclerotic are perforated by the pseudoplasma. Particularly instructive is the case communicated and drawn by *Szokalski* in *Zehender's klinischen Monatsblättern* of 1865, pp. 396 to 404. Retrogressive metamorphoses, especially fatty and calcareous, which I found anatomically, as also *Robin* and *Virchow*, are advanced by the last-named investigator as evidences of the arrest and involution, and consequently the exhaustion and destruction, of the pseudoplasma. This conclusion is substantiated by several observations in which the amaurotic cat's-eye passed over into a permanent and innocuous atrophy. The above-mentioned case of *Sichel* furnished convincing proof, by the dissection of the other

eye, that it really referred to an encephaloid of the retina. Temporary *atrophy* (lasting three months) was observed in our Case VII., which terminated fatally at a later period; likewise by *Von Graefe* (Arch. f. Ophthal., x., 1, pp. 216–218), on both eyes of a child. *That the malignancy of glioma of the retina is entirely local in its first stages, the first of our cases*, in which the retina and choroid alone were attacked,—the optic nerve and orbital tissues, on the other hand, being entirely unaffected,—bears evidence. Two years and a half after the operation, the child died from extension of the pseudoplasma situated in the other, less diseased, retina. That in the orbital cavity of the extirpated eye no symptom of a relapse was present two years and a half later, has, according to my information, not been observed as yet, and is certainly worthy of notice. Had I extirpated the other eye at the same time, the life of the child might possibly have been saved. The virus had certainly not yet been absorbed from the right retina into the general economy, for symptoms of generalization appeared only after the left non-extirpated eye had passed through all the stages of the disease.

VII.—*Treatment.*

The foregoing remarks afford many a deduction and hint for the treatment. *Should a unilateral glioma of the retina be recognized early, I consider the enucleation of the globe decidedly indicated, especially if the entire*

retina is not yet attacked. Since the proliferation proceeds from the retina, and not from the optic nerve, and disseminates germs capable of development only later, outside of the capsule of the eye, the simple enucleation will be sufficient, and will remove with the affected eye all the roots of this evil, fatal by its generalization. It will be prudent not to divide the optic nerve near the sclerotic, but to remove a longer portion, even if its cut surface appears perfectly normal. I consider this more rational than hoping for the highly uncertain atrophy. *If increased tension and inflammation, consequently the second stage, are already present, I advise a complete extirpation of the eye, together with the contents of the orbit;* for the enucleations of the globe from Tenon's capsule, until now performed in this stage, have all been followed in a very short time by local relapses—a proof that the glioma germs were already disseminated in the orbit. The danger of consequent meningitis from this more extended operation, especially if we consider that it is undertaken in children, is indeed greater than in simple enucleation; and even after this comparatively simple procedure, in one case (*Horner's*) there ensued a fatal meningitis. If the optic nerve be found degenerated as far back as its entrance into the cranium, we, guided by our present knowledge of this disease, should not indulge in illusive hopes of preserving the patient's life.

In the last stage, when perforation and exophthalmos are present, our expectation to save life is reduced to a minimum. Still, even here, a possible escape is conceivable in case of unilateral glioma, as is illustrated by

Sichel's case, which after rupture passed into a state of atrophy. *I should also, in such cases, perform the operation of total extirpation of the eye and all orbital tissues*, and not be contented with the operation of enucleation, although more favored at present and easier of execution. The fourth of the foregoing cases, in which a fatal local relapse ensued, though the stump of the optic nerve was healthy, yet furnishes an additional argument in favor of such a procedure. Had I at that time removed all the orbital tissues, the local relapse might possibly have been prevented and the life of the patient perhaps saved.

In cases of bilateral glioma of the retina, we would *be fully justified in extirpating both eyes*, since in this manner there is a possibility of saving life; but we will scarcely ever have the opportunity of putting these principles into practice, as the friends and relations will hardly give their consent. Our humane age, in which crippled children cannot be exposed on the Taygetus, as the Spartans were in the habit of doing, does not permit us to ask whether it would not be better to let a blind child die than to grant him a remedy for prolonging his existence. The uncertain result of this remedy can alone influence the physician not to request permission for the bilateral operation of extirpation.

If *cerebral complications*, in cases of unilateral and bilateral glioma, are unmistakably pronounced, as in Case II., vomiting, headache, and sopor, we can only be induced to undertake an operation in order to alleviate the severe pain resulting from the extreme tension of the eyeball.

The disease then terminates fatally, either in this manner or otherwise, for even if we do not wish to consider isolated retinal, spinal, or cerebral glioma as absolutely mortal, we can no longer cherish such illusory hopes when a combination exists.

After having expressed myself decidedly in favor of a vigorous treatment with the reservations previously mentioned, I must not conceal the fact that very many prominent physicians avoid such heroic measures on account of the sad results they have experienced from their operations. They then confine themselves to a reverent observation of the phenomena of nature, or content themselves with "an appropriate medical treatment" intended to bring on the atrophy of the pseudoplasma. But this atrophy, the possibility of which I am far from denying, we should carefully record after having made the diagnosis as positive as possible; for if we consider everything which presents the appearance of the amaurotic cat's-eye as encephaloid, we will draw very many false conclusions on the efficacy of an "appropriate medical treatment," as has been proved during the last few years from most varied sources.

The "appropriate medical treatment" to which I have reference, is transmitted to posterity by *Sichel*, and the importance of the subject makes it my duty to quote the same from his excellent work, which perhaps cannot be easily acquired by every physician. I beg permission to present it in the French, the original language, for it, as well as all other translations, must lose by rendition into the English. *Sichel*, on page 574 of his Iconographie,

speaks as follows: "J'ai été le premier et le seul à constater par l'anatomie pathologique l'atrophie du globe oculaire affecté de véritable encéphaloïde, et à baser sur cette terminaison heureuse une méthode thérapeutique contre cette terrible maladie. J'ai annoncé ces faits depuis longtemps; je les signale de nouveau à la sérieuse attention de mes confrères. Ces faits m'ont porté à tenter, dès la première période de cette maladie, d'amener l'atrophie par un traitement antiphlogistique, altérant et dérivatif, très-énergique. Les applications réitérées de sangsues près de l'organe affecté, précédées de saignées générales chez les individus robustes et sanguins; les mercuriaux à doses altérantes longtemps continués avec des interruptions, de manière à ne produire ni salivation ni action purgative (calomel un centigr. ou une pilule bleue de la Pharmacopée d' Edimbourg du poids de 5 centigr. deux à trois fois par jour; onction d'onguent napolitain; la pommade d'oxyde noir de cuivre, un gramme pour 10 grammes d'axonge); le chlorure de barium; les préparations antimoniales et iodurées; enfin, les antiplastiques et les résolutifs en générales, et chez les individus lymphatiques les antiscrofuleux; les purgatifs; un régime peu nourissant; des cataplasmes émollients appliqués sur l'œil; des vésicatoires volants promenés au haut de la nuque et derrière les oreilles, etc.: tels sont les moyens, qui ont parfaitement répondu à mon espérance. Plusieurs fois j'ai arrêté la marche de l'encéphaloïde retinien par l'emploi de ce traitement, en obtenant l'atrophie; celle-ci n'a été suivie que dans un seul cas de récidive du cancer oculaire."

It is left to the physician to determine, from the above-

mentioned methods of treatment, an appropriate remedy for a given case. Experience does not favor the assertion upon which *Sichel's* opinion is based, that, with the failing powers and nutrition of the body, malignant growths begin a more favorable progress, or, in other words, will atrophy. We are in want of further careful observations, especially of the beginning of this disease, and records of both the unhappy and happy results of operations. Though the statistics thus far are very discouraging, the possibility of preserving life by the removal of the eye, in cases where glioma of the retina is recognized at an early period, seems to me undeniable and well supported by convincing anatomical data.

If the above investigations contribute to the adoption of this conviction by my colleagues engaged in practical ophthalmology, I shall consider it the highest reward of my labor.

Part 2.

SARCOMA OF THE CHOROID.

SECTION I.

DESCRIPTION OF CASES.

CASE VIII.—*Melano-sarcoma of the Choroid, Ciliary Body, and Iris.*

HENRY FESTER, of Mannheim, æt. 65, was slightly short-sighted, but had always been healthy. About one year and a half ago he noticed a faint haziness over his left eye, unattended by any pain, but gradually becoming denser; three months ago the sclerotic became covered with thickened and more numerous blood-vessels; five to six weeks ago the globe became red, inflamed, and slightly painful; ten days ago these symptoms augmented considerably in intensity, the pain spread to the neighboring parts, and was especially marked by night. For these symptoms Heurteloup's artificial leech was employed. I first saw the patient two days ago.

Status præsens. The lids and the surroundings of the eye normal. Globe freely movable, neither protruding nor enlarged, its tension at present but slightly, two days ago considerably increased. Conjunctiva and episcleral vessels very much injected, without any marked tume-

faction. Cornea normal; less sensitive than that of the other eye. Anterior chamber of a smoky haziness, somewhat shallower than in the right eye. The normally blue iris of a reddish-yellowish gray, thickened, dull, with loss of the peculiar, delicately-fibrous aspect of its texture (hyperæmia and exudation). The pupil movable but sluggish, no synechiæ. The superior portion dilates perfectly with atropine. At the inferior and internal portion the iris is detached from its peripheral insertion by a tumor (Fig. 26. tu) fully the size of a pea, grayish-black in color, its shape semi-spherical, of a general dull and velvety appearance, protruding into the anterior chamber, and pushing the greenish, detached portion of the iris into the centre of the pupillary field.

The pupil is of a smoky haziness. With the ophthalmoscope the superior portion of the fundus of the eye can still be illuminated of a dull red, but none of the details can be recognized. The inferior and internal portions appear in a grayish-black obscurity. By oblique light, especially beautiful with the direct rays of the sun, there was seen, close behind the iris, and forming an uninterrupted continuation of the tumor which projected into the anterior chamber, another similar one of the size of a cherry-stone, of a dull grayish-yellowish color, and growing from the ciliary body toward the axis of the eye (Fig. 27. tu_1). Its surface is very slightly uneven and without visible blood-vessels, whilst that of the small tumor in the anterior chamber is smooth, and upon it a few dark red ramifying lines can be recognized as blood-vessels. In the lower internal quadrant of the

field of vision, the patient possesses only enough power of perception to follow the movements of the hand.

The eye was enucleated 23d July, 1868; its external appearance was entirely normal. A section in the horizontal meridian revealed the vitreous clear and viscous as usual, the upper half of the eye entirely healthy, a circular atrophy of the choroid around the optic nerve, broader toward the macula lutea, but no ectasy of the sclerotic.

In the lower half of the globe there was seen not only the melanotic mass observed during life (Fig. 27. tu_1), *but also still another lying close behind it, and of the size and appearance of a small black cherry* (Fig. 28. tu_2). Its surface was perfectly smooth and spherical; at its side were situated several others smaller, leveller, and irregular in shape (Fig. 28. tu_3). Besides, on the other side three black pigment patches (Fig. 28. p), evidently the beginning of other melanoses, were remarkable on the choroid.

The retina was everywhere adapted to the fundus of the eye, and also covered the melanotic accumulations. Only in one place near the optic nerve (Fig. 28. re), it was stretched over a fluid to the posterior tumor; with this exception it clothed the tumors closely as well on their depressions as on their elevations.

The eye was laid in Müller's fluid, and examined more minutely three months after.

The *retina* manifested nothing abnormal. It could be easily raised from every part of the surface of the tumor. Consequently, there were no adhesions. Even in those places where the retina covered the tumor most densely,

no extension of the elements of the tumor to the retina could be found in transverse sections, not changing its relative position to the tumor. An equatorial transverse section (Fig. 29) through the tumor (tu) revealed its direct origin from the choroid. On both sides the choroid (ch) appeared normal and in its normal position, then it suddenly swelled into the nodular tumor. The retina (re) covered this tightly, and was only detached from it at the borders of its base. The sclerotic (scl) was of normal thickness and normal appearance, free from every black invasion. The cut surface of the tumor itself was finely granular, soft, somewhat harder only at its base, and there of a deep black color, whilst everywhere else it appeared of a spotted grayish-black and light-yellow color.

Now I divided this half of the tumor by a longitudinal section (Fig. 30), in order to discover its anterior boundary. The ciliary processes and muscle were no longer recognizable, both having been destroyed by the tumor, which like the others, grew towards the axis of the eye from the sclerotic. The iris (Fig. 30. ir) was preserved; but immediately on its ciliary border the grayish-black, granular pseudoplasma surrounded the margin of the lens and extended somewhat further along its posterior surface. The cut surface of the tumor was completely like that of the equatorial transverse section.

The *microscopical examination* of the tumor revealed a uniform tissue consisting of round, oval, fusiform, and stellate cells, partly pigmented and partly unpigmented. Between them was a very scant, homogeneous, inter-

cellular substance, traversed rather abundantly by blood-vessels. Consequently the whole formed a well-characterized *melanotic sarcoma.*

The choroidal tissue, with its uniform arrangement of vascular anastomoses, intervascular spaces, and stellate cells continually communicating, as well as isolated lymphoid and fusiform elements, was nowhere to be found as such, although all these forms appeared in the tumor. Pale, fusiform cells (Fig. 31. a), uniformly with nucleus and nucleolus, formed one of the chief components of the mass, besides similar caudate (Fig. 31. b) and round, pale cells, finely granular with regular nucleus (Fig. 31. c), and those (Fig. 31. d) which in their interiors were either without nucleus or presented in one spot denser or coarser granulations, which perhaps could be considered as the development of a nucleus. In many places of the tumor the increase of the cells could be plainly demonstrated by the double nuclei and nucleoli (Fig. 31. e). All these forms of cells were also found pigmented (Fig. 31. f,g). The pigment filled almost all the cells regularly, since it was embedded in the cytoplasma as molecular granules. Ordinarily we could discover on the cells a well-marked, bounding membrane, and between this and the pigment, in the interior, a narrow, transparent ring (Fig. 31. i). This ring was often missing, and then the pigment granules filled the entire cell (Fig. 31. f_1) uniformly. In other cells the nucleus was without pigment and the contents uniformly filled with it (Fig. 31. f_2), or one side of the cell filled with pigment more compactly than the other (Fig. 31. g).

It was easy to determine the *structure* of the tumor. In many places, especially in the whiter spots of the centre, small, round cells could be found lying loosely together, with one or more nuclei (Fig. 31. k), as they have been designated by *Virchow* an indifferent stage of cell development. From these primary forms of cells we see every conceivable thing developing, and we did not need to go far to obtain other more advanced figures: the cells became larger, acquired more distinct nuclei, but, above all, more distinct boundaries (envelopes), and became oval and fusiform (Fig. 31. l). The distance between the single cells was, in many places, extremely small; indeed, we would be disposed to assume an entire absence of intercellular substance, if the image by the stereoscopic microscope did not correct the optical error and conclusively prove the contrary. The prominent form-elements appearing, under the monocular instrument, accumulated in one plane, were separated, under the binocular, further from each other, and it could easily be seen that they were suspended in a very delicate and fine intercellular substance.* The more the cells became fusiform the more pigment was present; still the pigmented cells themselves were more frequently rounded and poly-

* I am surprised that *Cohnheim*, in his highly meritorious article on choroidal tubercles, can say: "If we only had a really stereoscopic microscope." The English and Nachet's binocular microscopes are at present appreciated by most men in Germany, so that a person who cannot discover a difference in objects under the monocular and binocular microscopes has no longer the right to doubt the stereoscopic power of the latter, but has sufficient cause to have the motility of *his own* eyes and the capabilities of his own binocular vision (especially in the employment of stereoscopic instruments) examined.

gonal than fusiform. Generally it was found that, between the pale round and the fusiform cells, pigmented elements, in layers more or less dense, had become wedged in (Fig. 31. l); here and there the latter were so densely packed (Fig. 31. i) that nothing else could be seen between them; indeed, the coloration at times was so deep and regular that the cellular nature of the substance carrying the pigment could not be distinguished, as is so often the case in the pigment layer of the iris.

The point from which the tumor originated was the peripheral layer of the stroma of the choroid. Although the nodular intumescence itself rose abruptly from the choroidal level and approached the centre of the eye, we could still demonstrate, in transverse sections, that at its base it spread out in the choroid. The stroma of this membrane, in itself poor in pigment, presented, close on the sclerotic, an abundant accumulation of dark-brown pigmented cells. Most of these were elongated, and contained from two to five pigmented lumps arranged in a row. Between them lay light fibrous tissue, with fusiform pale elements. However, the more the pigment accumulated, the more this fibrous arrangement disappeared. The lumps of pigment lay irregularly together, became larger and irregularly shaped. Nevertheless, on thinner sections, we remarked a colorless, very finely dotted intercellular substance. The proliferous, pigmented elements soon caused the absorption of the suprachoroidea, and then encroached on the neighboring layers of the *sclerotic.* In the latter, however, they never reached any considerable stage of devel-

opment, so that the external three-fourths of a transverse section of the sclerotic were found everywhere entirely free from coloring matter.

Internally, however, the pigmented elements vegetated luxuriantly. The choroidal tissue became thickly impregnated by them, for the pigmented pseudoplasma gradually extended further into the inner choroidal layers. This could be plainly seen in transverse sections of the preserved larger *blood-vessels*. At first, the portion of their coats adjacent to the sclerotic acquired a black color, and as the black pseudoplasma increased, it gradually enveloped the entire blood-vessel, the inner coat of which alone still remained without pigment and unchanged. The blood-vessels were also considerably removed from the sclerotic, and pushed further into the interior of the eyeball. This took place because the black cells, situated between the blood-vessel and the sclerotic, multiplied rapidly, the vessels and the inner layers of the choroid naturally having to make place. In the black mass near the principal tumor there could be found the gaping lumina of the larger choroidal vessels, often lying pretty closely together, which consequently remained preserved, and were the origin of the formation of the new vessels of the proliferating pseudoplasma. The thin choriocapillaris remained over this for a long period perfectly free from pigment, and was covered uniformly by the normal basement and pigment layers. But at the apex of the tumor there was nothing preserved of these internal layers of the choroid.

From the choroid proper the pseudoplasma spread to

the ciliary body and iris, and there had produced a prominence which projected into the anterior chamber (Fig. 26), as we have already perceived.

The transformation of the normal tissue into sarcomatous tissue took place in the orbiculus ciliaris exactly in the same manner as in the choroid. Of the ciliary body, the *ciliary muscle* was peculiar. I executed a sufficient number of finer sections in a longitudinal direction, beginning near the tumor of the iris and progressing into its centre. The length of the cut was from the middle of the cornea to the orbiculus ciliaris, so that I, by this series of sections (14 in number), could easily observe the condition of these parts in their progress. Firstly, from the smooth portion of the ciliary body, which was entirely transformed into a black tissue, the pigment cells crowded in (Fig. 32) between the posterior fibrous strata of the ciliary muscle, whilst a simultaneous and more abundant development in the tissue which connects the ciliary muscle with the sclerotic took place, and continued as a black cord as far as the insertion of the ciliary muscle on the walls of *Schlemm's* canal. The principal portion of the ciliary muscle, however, was entirely normal; radiating and transverse tracts of fibres, without invasion of foreign elements (Fig. 32. m, c), could be distinguished. The part of the ciliary processes adjoining the vitreous was softened, and proliferation of pigment into the colorless enveloping layer was unmistakable (Fig. 32. p, c).

As the disease progressed, the pigmented sarcomatous cord lying between the ciliary muscle and sclerotic be-

came thickened, as also the layer running toward the vitreous, whilst the ciliary muscle at the same time became more and more atrophied. The sarcoma cells not only grew into it from behind, but traversed it in layers which, like its radiating fibres (Fig. 39), ran longitudinally from its anterior scleral attachment. These layers were composed of rows of irregularly round pigmented figures, from the size of a blood-corpuscle to that of a larger epithelial cell, lying close together, though not directly connected with each other. The interior of these figures was irregularly colored; the larger contained several dark nuclei. Besides, there lay embedded in the ciliary muscle numerous pale, nucleated cells, attaining and exceeding the size of a white blood-corpuscle.

Consequently, the whole was only a simple extension of the proliferous pigmented and unpigmented sarcomatous elements to the ciliary muscle, whose connective and muscular tissue gradually and finally completely made way for the intruding pseudoplasma, as is represented in the drawing (Fig. 37), borrowed from the following case.

The extension to the iris occurred in the same way of gradual progression, without any obstacle. The sarcoma cells, pigmented and unpigmented, multiplied in the stroma of the iris, as in that of the choroid, and there formed the small tumor previously mentioned, and in which sarcomatous tissue only could be discovered. At its anterior extremity the iris, almost unchanged, again appeared in the same manner as we have already remarked in the choroid near the tumor situated in it.

The *further progress* of the case, as kindly communi-

cated to me by his attending physician, Dr. Gerlach, of Mannheim, was, in short, as follows: The patient never recovered completely; he remained feeble and depressed in spirits. Painful œdema of the lower extremities set in. He frequently had blackish sputa, often discolored by blood. It was remarkable that, six months after the operation, all these symptoms disappeared; the patient became stronger, and was out of bed six to eight hours daily. Two months afterward a relapse again set in; loss of appetite, disgust at the sight of food, failure of strength, œdema of the legs, abdomen tense and tympanitic, hard bossy tumors in the region of the liver and stomach, pulse frequent, sleeplessness, vomiting of food, mucus, and chocolate-like masses, sinking of the powers to the extreme, and death on the 19th of March, 1868, nine months after the operation.

Although no post-mortem examination was made, it is evident from the symptoms that metastases to the liver, lungs, and stomach were present. No relapse was discovered in the orbital cavity.

Case IX.—*Melano-Sarcoma of the Ciliary Body and the Choroid, with Perforation in the Ciliary Region of the Sclerotic.*

Lisette Schneider, of Bruchsal, æt. 62, came to my clinique for the first time on the 2d of February, 1865. She had been sickly during the last ten weeks, and had

shortly before noticed a *sudden diminution of the power of vision* in the left eye, but unaccompanied by pain or other inconvenience originating in the eye. At the time of presenting herself at the clinique, she was able to count fingers at the distance of two feet. The boundaries of her field of vision could not exactly be determined; but an indubitable defect internally, upwards, and externally was evident. The lens is beginning to be of a radiated opacity from its equator. With the ophthalmoscope we can discover inferiorly and externally, when the eye is directed downward, a quarter of the ophthalmoscopic field occupied by a dark body with a movable surface, whilst the remainder of the fundus of the eye is obscured as if by smoke, and of a reddish reflection, but not precisely recognizable in its details.

The right, the healthy eye, showed $\frac{1}{10}$ hyperopia, and, for this age, normal power of vision. The patient was dismissed, a diagnosis of detachment of the retina inferiorly having been made.

At the expiration of three months she again presented herself. She had had, during the last three or four weeks, severe pain in her left eye, extending also to the right, and being combined with periodical cloudiness of the latter. However, the right eye, upon examination, manifested no change either in structure or function. But the left had changed essentially: the anterior chamber was shallow, the pupil moderately dilated and sluggish, and the tension of the globe very much increased (T_2, according to Bowman's scale); cornea clear, lens transparent, with the exception of the radiating streaks be-

fore mentioned, which had not spread, and the field of vision preserved only in its internal and lower portion. With the ophthalmoscope the upper portion of the field of vision gives a dull reflection, but none of its details are recognizable. The lower portion of the fundus of the eye is of a bluish-gray, and cannot be illuminated in the usual red color. With focal illumination there can be seen, in the lower and outer portion of the ciliary region, a prominence of a dirty grayish-red color, lying close behind the lens, and advancing toward the centre of the eye. Its surface was traversed by streaks of a dirty whitish-gray and blackish color, which ran from the capsule of the eye towards the centre of the globe.

The *diagnosis* was now fixed with certainty as a melanotic sarcoma, proceeding from the ciliary region, with consecutive detachment of the retina, and was particularly based on the pain and hardness of the globe, but principally on the appearance of a protuberance with black and white streaks and about the size of a cherry-stone. The characteristic symptomatology of sarcoma is certainly not always so decided as here. Nevertheless, several not inexperienced oculists frequenting the clinique, expressed their doubts as to the correctness of the diagnosis, arguing for detachment of the retina, accompanied by glaucomatous inflammation.

This did not convince me. I made the necessity of an enucleation plausible to the lady, and upon her consent performed it at once.

The simple enucleation healed without any accident, and the patient was dismissed ten days after, being free

from pain or other complaint. The recovery proved to be complete and lasting, since no sign of local relapse nor of metastasis could as yet (end of February, 1868) be detected.

The eye was hardened for three months in Müller's fluid, and then examined.

The globe, normal in form and size, was opened by a meridional section (Fig. 33). The anterior chamber had disappeared, for the iris and lens lay close to the cornea, but could easily be separated from it and from each other. On the lens, nothing remarkable.

The retina (Fig. 33. re) was detached in the shape of a funnel, and, indeed, so completely, that anteriorly it clothed the ciliary processes and the posterior capsule of the lens. Of the vitreous there was nothing more to be seen, since hardly any space was left between the folded retina and the posterior pole of the lens. A round tumor (Fig. 33. sa), of the size of a hazel-nut, was attached by a somewhat slender pedicle to the ciliary region. On accurate measurement, it proved to be 9 mm. in breadth, and 11 in height. It was perfectly hardened, had a black central nucleus of from 3 to 4 mm. in diameter, and from it there radiated several black processes. The remaining mass was of a dirty white to its very periphery, which appeared black, finely granular, and streaked. It was covered by the retina everywhere, though there were no adhesions with it, as it could easily and without resistance be detached in all places. The retina itself was white, and by reflected light appeared tolerably transparent. The fluid found between it and the choroid was

transformed by the hardening fluid into a brown, perfectly homogeneous, and completely translucent jelly.

I then made a transverse section through the tumor, in a circle nearly parallel with the equator, 6 mm. behind the transparent border of the cornea, consequently transversely through the ciliary region. In this manner it was discovered that the tumor had a broad base (Fig. 34) and rose as a hill. Therefore it probably proceeded from the ciliary body, and that in a breadth of thirteen to fourteen mm. In its entire length it was closely adherent to the sclerotic, and presented from its base to its apex the same homogeneous granular appearance. The body of the tumor was pale, its superficial layer being black, and was traversed, as in the meridional section, by black streaks which began in broad bands at the sclerotic and narrowed gradually toward the apex.

By minute exploration and dissection of the sclerotic, still another peculiarity came to light on the outer surface in the vicinity of the transverse section just described, namely, there were, opposite to about the centre of the tumor, three small, perfectly black protuberances, close upon the sclerotic and adjoining each other (Fig. 35. sa_1). They were, on sections, one-half to one mm. in height, and had a diameter of three mm. at their bases. The sclerotic which lay between them and the internal tumor was apparently normal.

Microscopical Examination.

The entire tumor, from its apex to its base, consisted of a homogeneous sarcomatous tissue: round, long, and fu-

siform cells embedded in a vitreous, intercellular substance, either entirely amorphous or slightly dotted. In torn preparations and on the edges of the cut surfaces, the cells were mostly oval or fusiform, whilst on thicker sections the round prevailed. The pigmentation was of such a kind that the bodies of the cells were more abundantly filled with the pigment granules, the processes being paler. Most of the colored elements were round, with a small white centrum, the nucleus of which, however, was often surrounded on all sides and concealed by the pigmented contents, so that it only came distinctly to view as a small white circle on changing the adjustment.

Many bloodvessels, most with delicate coats, traversed the tumor.

In order to determine the boundaries and development of the intumescence, the choroid was examined in all places. Posteriorly it was perfectly free of foreign elements, only somewhat atrophied. The tumor itself was developed somewhat abruptly at a well-marked boundary, whence it arose gradually, but rather steep, from the tissue of the choroid (Fig. 36). It could plainly be seen that it originated in a proliferation of the pigmented and unpigmented stroma cells of the *outer layers*. Wherever the choroid was still normal, the cells on transverse sections presented themselves chiefly as elongated figures (Fig. 36. a b). This layer then became thickened (Fig. 36. b c d), and the cells became round, polygonal, and received processes. The choriocapillaris and pigment layer regularly covered the beginning of the tumor, for only here and there (Fig. 36. e) pigmented cells invaded

the same. The majority of the larger choroidal vessels (Fig. 36. i i) were also crowded inwardly by the swelling of the exterior layers. In more elevated portions of the tumor it was no longer possible to prove it regularly covered by the internal preserved layers of the choroid.

Anteriorly, the tissue change extended through the ciliary body to the beginning of the stroma of the iris, in the same manner as was described in Case VIII. The farthest point reached anteriorly in a meridian intersecting the middle of the tumor, is shown in Fig. 37, where the entire ciliary body, muscles, and processes were transformed into the melanotic mass (Fig. 37. sarc), and the proliferation extended to the isolated black and white cells on the peripheral portion of the stroma of the iris (Fig. 37. ir). Cornea and sclerotic were perfectly free from foreign deposit.

The *sclerotic*, however, presented an entirely different condition in the places which separated the small outer tumors from the inner sarcomatous mass. On section, only here and there, a black spot or a short dotted line could be discovered. However, if fine sections were brought under the microscope, the tissue of the sclerotic could instantly be seen traversed by different streaks of pigmented cells, whose continuity throughout the whole thickness of the sclerotic was difficult of demonstration, since they traversed the white fibrous capsule at all possible curves. In one place (Fig. 38), however, the demonstration of the transition of the internal tumor (a) to the smaller outer ones (g g) by an uninterrupted series of cells was manifestly successful, only a very thin layer

intervening in which it was no longer possible to trace the relation. The connection took place in such a manner that a thicker cellular mass (cd) invaded the sclerotic for a short distance from within; from this several cell-rows branched off, wherefrom two ran parallel with the bundles of fibres of the sclerotic, the third (de), however, traversing them at right angles. This branch then divided itself into two secondary branches, the longer of which (ef) approached, in a winding course, to within a short distance of the episcleral tumor. That it communicated with the latter cannot be doubted, since we may assume that it continued obliquely through the cut, and that it must have been removed with the tissue lying over it. We perceive, however, by the scarcity of sarcoma elements in the sclerotic that this is as unfavorable ground for their development as it is for other pseudoplasmata. Whenever the most advanced cells of the invading rows reach the external surface of the sclerotic, they find in the subconjunctival connective tissue an exceedingly favorable ground for a rapid development. Hence, the outer tumors augment to considerable masses, whilst it is often very difficult to demonstrate their passage through the sclerotic to the inner tumor. In previous investigations I did not succeed in detecting these connecting cellular links, which is accounted for in my having to examine very large outer tumors which rested with broad bases upon the white membrane. At that time I took refuge in the migrating cells, to which we at present (immediately after they have been discovered) ascribe so much labor that I hardly should have

offended had I attributed this new burden to them. I do not doubt that I should have found a connection of those large tumors with the inner one if I had had perseverance enough to make an adequate number of transverse sections of the sclerotic. This, in the eye here described, has not been a difficult task, since the outer tumors were very small. As much as I acknowledge the yet undetermined importance of the migrating cells, and as high an esteem and friendship I entertain for their most intelligent discoverer, *v. Recklinghausen*, I could still dispense with their assistance in the origin of secondary extra-ocular tumors, after having observed their connection with internal tumors by macroscopical and, where these were deficient, by microscopical passage of pseudoplasma.

I did not fail to examine these connecting strips with higher powers (immersion system). It became evident that its elements are composed of round, pigmented cells of exactly the same formation as that of the primary tumor. They crowd in between the bundles of fibres of the otherwise perfectly normal sclerotic, and form accumulations, mostly all elongated (Fig. 39. cd) and parallel to the direction of the fibres of the sclerotic. They all bear the marks of reproductive cells and, at the apex of the cell-rows, consequently in the youngest accumulations, are mostly all unpigmented; then, at first its covering of protoplasma, afterwards the whole cell, become filled with black pigment granules. In Fig. 39 the letters a b represent the most external layer of the inner choroidal tumor; scl. scl., the sclerotic, whose undulating fibres could plainly be seen containing fusiform

and elongated lacunæ which were filled with a substance apparently vitreous, but in reality only the transverse section of the fibre bundles running in another direction. The sarcoma cells themselves (Fig. 39. cd) contained large single and double nuclei, and were generally round and connected by an amorphous cement. That many of them penetrate between the fibrillæ of the sclerotic, like the migratory cells of the cornea, and multiply on their way, may be admitted without provoking opposition.

Case X.—*Melano-Sarcoma of the Choroid and the Ciliary Body, with Perforation through the Sclerotic.—Death one half-year after the extirpation, caused by Metastasis to the Liver, Kidneys, and Lungs.*

Judge Heuberger, æt. 73, of Freiburg (Baden), came to me on the 2d of June, 1866, and complained that for the last five months the sight of his left eye was failing, without ever having produced pain, inflammation, or any other trouble. He had always been healthy, and in his family no hereditary or otherwise malignant disease was known. The power of vision in his left eye diminished in such a manner that, at first, a haziness spread from the left side toward the centre, and became gradually denser, so that at present this eye is capable only of a weak perception of light from over the nose. In truth, his power of vision proved to be entirely destroyed in the left half of the field of vision of this eye, whilst in the

right half larger and very bright objects could still be distinguished.

The shape, motility, and color of the eye and of the iris and pupil were not changed; the anterior chamber possibly was somewhat shallower than that of the other eye. Tension normal. By reflected light there could be seen in the region of the posterior surface of the lens, externally, an immovable, dirty, gray opacity, with indistinct radiating striæ converging towards the axis of the eye. In the centre of the ocular space behind the lens were seen gray, slightly transparent, folded membranes without blood-vessels. With the ophthalmoscope, only the inner half of the pupil could be illuminated of a dull red without disclosing in the least any details of the fundus, whilst the outer half appeared entirely black and the connecting portion presented a number of thick gray opacities.

I unhesitatingly pronounced the disease a melanotic sarcoma of the choroid, and protested against a diagnosis, proceeding from another quarter, of incipient cataract complicated with detachment of the retina. In fact, there were a few equatorial opacities of the lens, which were also present in the other eye without mentionably disturbing the power of vision.

Decisive for my assumption, I held the complete obscurity of the left half of the eye, and especially the dark striæ close behind the lens seen by reflected light, as of precisely the same nature as those I have already demonstrated in the foregoing case (Lisette Schneider). It was evident that the tumor originated in the ciliary

body; I was not able to determine to what distance it extended posteriorly. Although neither increased tension of the globe nor pain were present, I could not doubt the correctness of my diagnosis, since I knew that these symptoms are generally absent in the early stages of the development of tumors.

I immediately communicated my diagnosis to this intelligent patient, and asserted positively that his eye could never again regain sight, and that it must be taken out. I also made it clear to him that only if the operation be performed soon, he might entertain hopes that the affection, a malignant tumor, would remain local and be eradicated with the organ.

This declaration made a deep impression upon him; he hitherto having comforted himself with the hope that, being affected with cataract, he might sooner or later be operated upon with a prospect of a restoration of his power of vision. I advised him to consult his physician once again, whom he, as well as I, esteemed highly, and to communicate my diagnosis to him. Although the physician did not appear to be convinced of the existence of a tumor causing the detachment of the retina, he nevertheless asserted that he also considered the power of vision of this eye irrecoverably lost; and I had the satisfaction of seeing the resolute old man return in four days with the intention of having his eye removed.

I enucleated the eye carefully in such a manner that, in case of there being an extra-ocular tumor in connection with the sclerotic, it might be found and removed. In truth, at the posterior pole of the eye an obstacle to

the enucleation was encountered, for a hard lump connected with the sclerotic broke into the loose tissue surrounding the globe. As the four recti muscles were divided, and the eyeball protruded from its cavity, I was enabled to enucleate the tumor at the same time, since it also was surrounded by loose cellular tissue. After this, I cut the optic nerve, loosed the two oblique muscles from their insertions, and obtained the eyeball together with the tumor upon it in a perfect and uninjured state. I convinced myself, by examining the contents of the orbit with my finger, that no other indurations were present.

The wound healed without any complication, and the patient went home fourteen days afterward wearing an artificial eye and satisfied with the result. About three months later I saw him again. He did not complain of anything, and I could not find any recidive by examining the orbit, nor were there any signs of metastasis elsewhere. Nevertheless, six months later he died. The autopsy was not made.

His physician wrote to me about him as follows: "The patient suffered from neglected chronic inflammation, with scirrhous induration and considerable hypertrophy of the liver, complicated with chronic organic affection of the kidneys and secondary general dropsy, to which finally an inflammation of the lungs of uncertain cause was associated, and closed the scene by paralysis of the lungs. I had no ground for suspecting a metastatic sarcoma of the liver, but believed rather from exact information to have every reason for the assumption that the affection of the liver was an ancient one,

and that the cause of the whole complex of symptoms was one which, as is well known, is so frequently observed, to a greater or lesser degree and extent, in old topers as was here the case."

This diagnosis does not appear probable to me; I believe, in preference, that *formations of metastatic sarcoma* were present in the *liver*, *kidneys*, and *lungs*. The whole course of the disease favors the latter supposition, in support of which I shall communicate an analogous condition in Case XII., where an autopsy was made. The fatty liver of drunkards does not develop so rapidly to "very considerable hypertrophy and scirrhous induration," but metastatic sarcoma of the liver assuredly does. As long as I watched the patient (and two to three months before his death I took a walk with him for several hours across the mountains) he never complained of his corporeal condition, but, on the contrary, was cheerful and robust. This circumstance, in addition to all that we know of metastases of melanotic choroidal sarcoma, scarcely permits a doubt over the correctness of the latter diagnosis in this case.

Examination of the Eyeball.

The eyeball remained unopened, and, immediately after the operation, was laid in Müller's fluid, which I renewed from time to time. The anatomical examination was made a year later.

The globe proved to be perfectly normal in all its dimensions. Beginning near the optic nerve entrance, and proceeding toward the temporal side, there was seated upon

the sclerotic a slightly nodular, black, and tough mass of the size of a bean. It was covered with loose cellular tissue, and everywhere had a smooth surface. The remainder of the sclerotic, as well as the outer appearance of the eye, was free from every abnormality.

I laid the globe open by means of a longitudinal section running along the side of the outer tumor through the middle of the optic nerve and cornea (Fig. 40). The lens, iris, the internal portion of the ciliary body, and the choroid, appeared normal. Externally, a tumor was situated, perfectly black in color, the cut surface finely granular (Fig. 40. sa), beginning close behind the insertion of the iris and lens, and extending posteriorly very near the optic nerve; whilst its inner surface, which consisted of two semispherical elevations, almost reached the axis of the eye. The retina (Fig. 40. re) loosely covered it, was attached to the optic nerve and ora serrata; it was, however, totally detached everywhere else, and folded as a cord in the centre of the eye, and pushed forward until it rested on the crystalline. Between it and the choroid there lay a perfectly white, homogeneous substance (Fig. 40. r), which, during life, must have been a slightly albuminous fluid, but had become thickened by the hardening process into the well-known yellowish-brown jelly.

Under the microscope it appeared as a perfectly homogeneous, vitreous substance, free from cellular elements of any kind. I then excised a segment (Fig. 41) of the other half of the globe, intersecting the sclerotic longitudinally in such a manner that the outer tumor (Fig. 41. ex) was halved, and that from the internal one a wedged-

shaped piece (Fig. 41. sa_1), together with a corresponding portion of the lens, iris, and cornea, was removed. The cut surface of the internal tumor also here was completely black, uniformly hard, and granular, whilst that of the outer one presented several lighter spots.

Under the microscope the outer tumor proved to be one of the purest spindle-shaped sarcomata of pigmented and unpigmented elements with scanty intercellular substance. The cells could be isolated easily, and their details recognized in fine sections. *The mode*, so often described, of *cell-generation, by multiplication of the nucleolus, elongation, constriction, duplication, and segmentation of the nuclei within the cells, and indentation of the latter*, could be demonstrated here with diagrammatical precision and distinctness, especially in the unpigmented cells (Fig. 42. a to f). The pigmented cells also presented identical appearances, only more difficult of recognition at first sight, as the nuclei were covered more or less by the pigment granules. The latter appeared as small black dots, which lay embedded in the contents of the cells. By higher adjustment of the instrument the nuclei were concealed by the pigment granules, and by lower again became visible. In these places the nuclei themselves were unpigmented throughout (Fig. 42. g to o). The shape of the cells was fusiform as a rule; nevertheless there was a great variety in them: round, oval, elongated, with two or more processes, the latter either straight or crooked. The nuclei were often situated eccentrically, and when several were found in one cell they were not seen distinctly at the same time, but

successively by changing the adjustment of the instrument.

The inner tumor consisted of entirely the same elements, similarly disposed, as the outer.

Sections of the sclerotic between the two tumors again brought to view, as in the foregoing case, the connecting cellular passages from the inner to the outer tumor. These passages also here were very intricate, and only reached the external surface of the sclerotic after having made a number of unsuccessful *false passages* parallel with its fibre-bundles, as if in search of another soil more favorable to their growth. The numerous parallel branches of the passages through the sclerotic prove the fact, anatomically so clear, that the tissue of the sclerotic offers less resistance to a mass traversing it in a direction parallel with its fibre-bundles than to one invading it at right angles to them.

As I raised the retina from the tumor, which could be done without encountering much resistance, I observed that the surface of the latter was covered by a very delicate grayish-white coat, which, especially in transverse sections, contrasted very distinctly with the deep black mass. Microscopically it proved to be a layer of loose, white, fibrous, connective tissue, containing very many elongated, ramifying, pale cells, among which a few black ones were disseminated. The most external layer was very peculiar in different places. There lay in an amorphous or finely-granular basement substance very many small, round discs, which were exactly like the retinal granules. This white layer covering the tumor,

I consider a layer of connective tissue, which soon becomes transformed into sarcomatous tissue, at first unpigmented, afterward melanotic. It is known under the name of *granulating* or *formative* layer, but is found in many tumors in those places where the growth is rapid. An analogous condition is found in the layer of connective tissue clothing exostoses, and particularly the ivory variety, and there serves as a *matrix* for the osseous tumor. However, on the apex of the tumor I found no traces of the basement membrane and epithelium of the choroid, neither could I distinguish the columnar layer and limitans externa of the retina. The remaining layers were preserved wholly uninjured, as I convinced myself after many a transverse section.

In preparations hardened in Müller's fluid the columnar layer often becomes detached; nevertheless, in this instance I consider it as having been destroyed with the sustaining choroidal layers, upon whose condition its integrity depends as much as upon that of the retina. Radiating excrescences of connective tissue from the retina into the tumor, as have been found growing into the choroid in retinitis by *Bolling A. Pope* and others, I did not discover here, probably because the whole vegetative process transpired without inflammatory action on the retina.

The lateral expansion of the growth in the posterior and anterior sections of the choroid was not very great. Posteriorly, its boundary was very abrupt, so that perfectly normal choroidal tissue was met with close on the steep elevation. This went over into the tumor without

interruption, for extensive formations of pigmented and unpigmented cells were present exactly in such a condition as was described minutely in the preceding cases and represented in Fig. 36. The ciliary body was involved in precisely the same manner as in the two preceding cases; the iris, however, was unaffected. The ciliary muscle was transformed into melanotic tissue only in the centre of the tumor; laterally, it was compressed from all sides, whilst its central layers were not yet affected, consequently presenting a condition precisely like that represented in Fig. 32.

If we consider that the principal mass of the tumor lies in the equatorial portion of the choroid, and that the perforation of the sclerotic took place in the posterior division, it is probable that the origin of the pseudoplasma was also in the choroid, and not in the ciliary body, as I had suspected from the clinical examination.

Thus, in this case, we have met with a triple mode of growth:

1. At the base, by direct transition of the hyperplastic elements of the mother tissue to the pseudoplasma (Fig. 36).

2. In the interior of the tumor, by multiplication of its own elements by endogenous formation of cells (Fig. 42); and

3. On the periphery, by the formation of a developing layer of granulation cells and connective-tissue-like elements, similar to the germinal tissue of the embryo (see below, Fig. 54).

CASE XI.—*Melanotic Glio-Sarcoma, with double perforation of the Sclerotic. Death by metastases to the Liver, etc.*

Clemens Huber of Ottenhöfen, æt. 63, came to my clinique on the 25th of May, 1867, and stated that three years ago he first noticed a diminution of the visual power of his left eye. Afterwards his eye became inflamed and painful, and had gradually gone over into its present condition.

Status præsens.—A reddish tumor protruded from the opening of the lids, which latter could only be closed with great difficulty. Its smooth surfacc (conjunctiva) was traversed abundantly by bluish, tortuous blood-vessels. The nodular tumor pushed the conjunctiva forward in such a manner that the superior cul-de-sac and the palpebral portion were convex anteriorly. When the lower lid was strongly pulled downward at the outer canthus, a small piece of the cornea was brought to view. The tumor was moderately hard to the touch, moved in common with the displaced eyeball, and was most intimately connected with its coats. Its surface, here and there, was of a slightly dirty, grayish-black color.

Consequently the diagnosis was that of a *melanotic choroidal sarcoma*, which had perforated the nasal portion of the sclerotic and had vegetated, principally internally, but also posteriorly, since the whole orbit appeared to be filled with it.

Operation May 27th, 1867. After having divided the outer commissure as far as the edge of the orbit, I dissected

the conjunctival covering from the tumor as well as possible, and cut the tendons of the rectus inferior and r. externus muscles, after having secured them with strabismus hooks. The tendons of the r. internus and r. superior could not be found in the tumefied mass. I then removed the tissue round about the tumor with a pair of strong curved scissors, feeling my way for the most part and directing the instrument with my left index-finger, and divided the optic nerve behind the most posterior portion of the tumor, and then easily dislocated it with my fingers from the orbital cavity.

Examination of the Tumor.

After the cellular and adipose tissue had been carefully dissected off, the tumor presented itself as an extremely nodular growth, of the size of a hen's egg, and joined to a globe which itself was contracted to one-half its normal size. Most of its nodes appeared of a reddish-yellow color; a few, however, were of a marked gray and black. By a transverse section, the eye was divided in the plane of the equator, and at the same time the portion of the tumor situated internally upon it (Fig. 43). The shrunken sclerotic (scl) was lined by extensive deep black masses, (sa) which formed a second internal capsule from 3 to 7 mm. in thickness. In the interior of this, the eye was filled partly with a grayish-white and tough substance, and partly with a yellowish gray and soft substance (gl). Under the microscope, the black mass, in some places, still revealed remains of the choroid: fibrous tissue with fusi-

form and stellate cells, but particularly well preserved the ramifying pigmented stroma cells. The basement membrane was demonstrable in many places, and easily recognizable by its numerous and peculiar wrinkles. I could no longer distinguish the layer of epithelial cells.

On the internal and posterior portion of the eye the structure of the choroid had completely disappeared in a mass of round cells, 3 to 6 μ in diameter (Fig. 44), partly pigmented and partly free from pigment. They all contained nuclei; most of them only a single one; many, however, two or more. Most of the nuclei had single nucleoli, several of them double ones. Nearly all the cells were laden with *fat-granules*. These, lying more or less compactly together, occupied about two-thirds of the cell, and had crowded to one side the large, generally oval, nucleus. In general, the pigment filled the cells uniformly, but it had also collected in irregular clusters and heaps in and between them (Fig. 44). The several cells had well-marked intercellular spaces, of which we could convince ourselves, not only with the stereoscopic microscope, but also by considering that the cells simultaneously brought to view were separated from each other by a finely granular, transparent, intercellular substance.

Although the cells for the most part were round, and had undergone more or less fatty degeneration, isolated places were encountered where the cells were poor in fat-globules and fusiform, and whose nuclei came very distinctly to view (Fig. 44. a). The contour of the cells, in many places, was less distinct. The free nuclei, the intercellular substance deficient in cells and nuclei,

and the cells themselves in every stage of decay, afforded evidence that the organized elements of this growth are characterized by a high grade of fragility. In a few places it even was difficult to find unbroken cells. The mass consisted of a finely granular, here and there lightly and irregularly striped tissue, in which fat-globules, nuclei, and brown coloring matter lay embedded in most irregular figures.

The caseous granular mass (Fig. 43. gl) filling the middle space of the eye, proved to be a pure *glioma*. The elements looked like retinal granules, and did not lie very compactly together (Fig. 46). They were richly filled with fine fat-granules. In a few places pigment had also accumulated in and between them, not appearing, however, brown or brownish-black, but dark yellow. Therefore it could not be considered as belonging to melanosis, but as the consequence of extravasated blood.

Of the *retina* and *vitreous* there was nothing to be found.

At the equator the sclerotic had been perforated (Fig. 43. rw), and there the cheesy granular mass had made its exit. Microscopical sections of this spot revealed preserved fibre-bundles of the sclerotic, and the small round discs of glioma-tissue crowding in between them (Fig. 47). The fibre-bundles of the sclerotic were torn asunder and beset with the glioma-cells in every direction ; nevertheless the latter seemed to prefer the passages, more or less broad, which ran longitudinally between the fibres. The whole outer tumor (Fig. 43. te), as far as it had been exposed by the equatorial sec-

tion, consisted of round cells, each containing a nucleus, and for the most part richly filled with fat-globules. Near the place of perforation they were not much larger than the retinal granules, or the corresponding clusters which filled the middle space of the eyeball.

However, further from the sclerotic the elements became larger, and presented themselves as fully-developed cells, whose diameter was generally twice that of the intraocular glioma-cells (Fig. 48). The large nuclei were surrounded by a distinctly circumscribed ring of protoplasma, and lay in a vitreous intercellular substance with interspaces, easily recognizable. Many cells had double nuclei, and many nuclei had double and triple nucleoli (Fig. 48). In these places fatty degeneration had not as yet instituted itself, and they were the vegetating portions of the tumor.

A meridional section (Fig. 45) then exposed the interior of the globe from the middle of the cornea to the optic nerve, and divided the latter (Fig. 45. n. o.) and the posterior portion of the outer tumor into two equal halves. The cornea, which was shrunken to about a quarter of its usual size, was thickened, but without any changes worthy of mention. The iris and capsule of the lens touched the posterior surface of the cornea. The lens itself (Fig. 45. le) was whitish-yellow, its centre normal, but undergoing fatty degeneration in the periphery; since in the granular degeneration of the lens, large quantities of fat in small granules and globules were found disseminated singly and in clusters.

Cellular formations were not found in the lens, so that

there was no extension of the pseudoplasma to the lens. It was also enclosed in its intact capsule.

The *optic nerve* (Fig. 45. n. o.) was excised at the same time, as a flattened and attenuated cord, three-quarters of an inch in length. Its sheath was delicate, and not separated from the contents by any loose connective tissue. The nerve itself was abnormal. Its beautiful white color was transformed into a semi-transparent grayish-white; the pulp hyaline and tough, with ill-defined parallel lines. Under the microscope a few remnants of winding nerve-fibres were brought to view, embedded in a viscous pulp of granules, fat, small round cells, and irregular flakes (*gliomatous degeneration*). The optic nerve terminated at the sclerotic, and went over into the melanosarcoma, without any definite boundary. We could not discover that its fibres penetrated the black mass, nor that they spread in any way to form the retina.

Internally from the optic nerve, but close to it, the pseudoplasma had perforated the sclerotic, forming an opening of 4 to 5 mm. The black mass continued with less compactness externally into two clusters, lying close together and somewhat larger than cherry-stones (Fig. 45. sa. e), and showed precisely the structure of the sarcoma of pigmented round cells, described above.

The *sclerotic* itself was considerably thickened and essentially changed in the neighborhood of this sarcoma-cluster. The peculiar undulating character of its fibres could be traced in several places, but were driven asunder by force of round proliferating cells. Nevertheless,

in other places these cells, for the most part unpigmented, were in such preponderance that the arched fibres traversing them and connected to each other ceased to exhibit the characteristics of the typical tissue of the sclerotic, so that one might be induced to consider this form of degeneration as an extended fibrous areolar network, whose meshes were filled with round cells simulating the structure of carcinoma.

These places, however, were of very limited extent. By far the greater portion of the sclerotic did not deviate essentially from the healthy condition. That it was not a true carcinoma was shown by the absence of the epithelial nature of the cells, and by the presence of intercellular substance which separated them more or less from each other. Such microscopial conditions must at all events have frequently been mistaken for carcinoma.

The pseudoplasmatic accumulations external to the sclerotic were, for the most part, soft here and there, almost fluid, some of a yellowish-white, others again, on account of an extraordinary abundance of vessels, of a reddish, marmorated appearance, and, in patches, even of a uniform red. There was nowhere any sign of fibre. Cells with processes could only be seen exceptionally; the entire mass consisted of round cells with finely granulated, almost homogeneous and transparent intercellular substance, and blood-vessels which were generally filled with blood-globules at the time of examination. They all had a very distinct cell-wall, most of them containing a large oval nucleus with one or two large round nucleoli.

If now we glance at the anatomical structure of the pseudoplasma, we are confronted by tumors of different natures; one *glioma*, the other melanotic, chiefly round-celled *sarcoma*. The very localities in which both were found lead us to suspect different maternal tissues as starting points; namely, the choroid for the sarcoma, and the retina for the glioma. All of the preceding cases were of simple and pure tumors,—either gliomata which evidently proceeded from the retina, or sarcomata which had originated in a portion of the choroid of the eye. In this case we have a *mixed* (combination) *tumor*, a *glio-sarcoma*, before us. The former evidently proceeded from the choroid; for this membrane in many places presented its characteristic structure unchanged, and beside it that portion which had been transformed gradually into sarcomatous tissue. The place of origin of the glioma could no longer be determined. It only lay in the centre of the globe. We, however, have already seen that in the ordinary course of glioma the retina and the vitreous are wholly destroyed, and are replaced by glioma masses. Consequently, we have to deal with a final stage, whose beginning we must suppose to have been as usual, instead of resorting to a new hypothesis, for instance, that a portion of the sarcoma underwent gliomatous degeneration.

The larger portion of the entire (mixed) tumor was gliomatous, but it did not necessarily follow that the glioma was the older portion. It might have developed simultaneously, or even later than the sarcoma, and in this event have increased more rapidly. This more

rapid growth is quite probable, if we consider the great abundance of small cells in glioma; for the medullary forms of tumor, which *Virchow* regards as anatomically identical with those rich in cells (multo-cellular), generally develop more rapidly than the more solid forms. That the sarcoma had instituted the succession of changes in the eye, I conclude principally from my never having observed a primary glioma of the eye in elderly persons, and know of no well-authenticated case in medical literature.

Yet there remains to be demonstrated why, in this case, the retina also became degenerated to a tumor peculiar to itself, whilst in the three preceding cases we did not see its tissue involved in any similar change. Yet we must remember that all the previous cases were in their earlier stages, in which, with the exception of the choroid, no other tissue of the globe was degenerated. Even if the growth of the tumor, in the interior of the eyeball now before us, was no greater than in the two foregoing cases, it nevertheless reached a more advanced stage of development, a fact which is deduced from the large perforation and extensive destruction of the tissue of the sclerotic. In both preceding cases we only found microscopical passages through the sclerotic, whilst here there was extensive destruction and shrinking of its tissue. That the sarcoma, like all other pathological formations, at first continues to develop in its mother-tissue until it implicates the neighboring tissues, is very evident. Further research must elucidate what the nature of the changes in the retina is, when a sarcoma

of the choroid is constantly destroying its integrity. It is conceivable how, under these circumstances, atrophy by pressure, or inflammatory changes and destruction of its tissue, may ensue; or, indeed, absorption by the intruding sarcomatous tissue (which process we may more properly term fusion); or perhaps the development of another tumor, not sarcomatous in its nature, of which we have, in this case, an illustration in the presence of glioma.

The wound left after the operation healed by first intention; the remaining orbital cellular tissue became covered with healthy-looking conjunctiva, and the patient was dismissed nine days after the operation, with a very unfavorable prognosis as regards life. On the 24th of March, 1868, the curate of the village in which he resided communicated to me that he was still alive, but that a relapse of the size of a goose's egg was present in the orbital cavity, and a growth had arisen in the abdomen. The patient is constantly growing weaker, and the fatal issue cannot be far distant.

Case XII.—*Melanotic Sarcoma, with perforation of the Sclerotic; Relapses after Extirpation and Death, caused by Metastasis to the Internal Organs. Autopsy.*

L. Nauert, æt. 44, of Wieblingen, near Heidelberg, presented himself for the first time at my clinique on the 30th of July, 1865. He declared that for seven years he has not been able to see with his left eye, and that

several months ago he began to experience pain in it. Three weeks ago a physician performed the operation of iridectomy upon it. I found the eye completely amaurotic, very tense (T_2 Bowman), considerably injected, the anterior chamber turbid and shallow, the pupil hazy, and the iris of a yellowish discoloration. At that time I regarded the disease as a *glaucomatous* iridochoroiditis, and, since the iridectomy had already been performed, and the yellowish iris indicated a suppurative inflammation, I prescribed leeches, and frictions with gray salve. The patient did not return until the 23d of March, 1867. He said that the redness of the eyeball had persisted with varying intensity, and that the globe itself had gradually become larger, and of late protruded more observably from its cavity.

Status præsens.—Eyeball moderately protruding, soft to the touch, its power of motion completely gone. The shrunken, cloudy cornea is hidden under the outer palpebral commissure, so that, in order to obtain a view of the cornea and of the position of the eyeball, we were obliged to separate the lids forcibly, and at the same time to draw them outward toward the temple, since by the ordinary mode of examination nothing could be discovered concerning the condition of the eyeball. The entire palpebral aperture was filled by the conjunctiva, which was traversed by wide venous vessels, and behind which we could discover a bluish-red, nodular, and soft mass.

Internally and superiorly several humps of the intumescence could be recognized through the bulging and

irregularly nodular upper lid. The intumescence itself was soft and painless on manipulation; it apparently filled the entire orbit, and was inseparably attached to the portion of the degenerated eyeball yet visible.

It was pronounced a *choroidal sarcoma*, which, indolent at first, had lessened the power of vision, and then had caused detachment of the retina and consecutive cataract (?), perhaps with glaucomatous symptoms. The iridectomy, which was based on a false diagnosis, had accelerated the development of the tumor, and perhaps determined its place of perforation. In the age of the patient, and the bluish-black shade of the tumor in different places, we were justified in assuming that it contained melanotic deposits; likewise, the soft consistence led to the supposition of its being a medullary form of sarcoma consequently of its containing an abundant development of, probably for the most part, round cells, since tumors composed of round cells are generally softer than those with spindle-shaped elements.

On the 20th of April, 1867, I performed the total extirpation of the globe, together with the tumor and the contents of the orbit. The wound healed without the intervention of any complication, and the patient went home nine days after the operation, in good spirits and appearing healthy.

Anatomical Examination.

The eye and the tumor were immediately halved (Fig. 49) by a section (meridional) from before backward.

The cornea (co) was reduced to a quarter of its normal size: The sclerotic (scl) indented and perforated posteriorly, its interior completely filled by a uniformly and intensely black, granular, soft mass, which through the opening situated posteriorly was connected to a large tumor (Fig. 49. tu e), fully the size of a hen's egg, of the same appearance as the mass in the interior of the eyeball, with the exception of its color, which seemed to be less uniform and not so deeply black; besides, it did not manifest so distinct an arrangement of clusters. Between these more compact masses the tissue was very soft, and a dirty, yellowish-brown juice could be scraped off with the knife.

In this I found under the microscope numerous cells, mostly round, but also fusiform, free nuclei, granules, and fat-globules of various sizes. The nuclei and cells contained well-marked, often double or multiple nucleoli, and were also partially filled with fat-granules. Around the large nucleus there was formed a very delicate hyaline and transparent protoplasma covering. Besides, a large quantity of brown pigment was found arranged in granules in the interior of the cells, and in irregular figures.

The black granular mass filling the globe consisted of melanotic sarcomatous tissue; chiefly of round cells, 6 to 10 μ in diameter, with large nuclei and well-marked nucleoli, embedded in a tolerably abundant, amorphous, intercellular substance. Near these there were also found isolated, elongated, and regularly fusiform cells, lying either deserted between the round cells or upon each other in heaps and layers. They, like the round ele-

ments, were of rather large dimensions (their transverse diameter being from 5 to 9 μ), and contained large nuclei and distinct nucleoli. The majority of the cells contained brown pigment-granules embedded in their protoplasma, through which we could yet distinguish the nuclei free from pigment. Fat also was abundantly present, both confined in the cells and as free vesicles.

The outer, extensive portion of the tumor proved to be of entirely the same structure, but contained a smaller quantity of pigment and fat.

With the exception of the sclerotic, cornea, and portions of the crystalline, all the tissues of the eye had been destroyed by the pseudoplasma. Gliomatous tissue, as in the foregoing case, could not be found anywhere.

The anatomical examination, therefore, resulted in the demonstration of a *medullary, chiefly round-celled melanosarcoma*, whose origin was of long duration, and might be assumed to have been in the choroid. The history of the case by the patient himself, though very incomplete, still presented the characteristics of the three usual stages of development: 1. Slow, intraocular formation, and growth free from inflammation; 2. More rapid development, with the symptomatology of glaucomatous irido-choroïditis; 3. Perforation of the eyeball, and external prolification of the pseudoplasma.

The patient continued in good health for the interval of three months; then a rapidly-growing relapse made its appearance, and in six weeks filled the whole orbit. I extirpated this tumor radically. The lamina papyracea

(os planum) was partially, the bony floor of the orbital cavity entirely, removed, and the remaining portions of the osseous orbital wall were, by scooping with a grooved chisel, deprived of all their soft parts, including the periosteum. This severe operation also was followed by a cicatrization remarkably favorable. The wound immediately began to granulate finely, was cleansed with the syringe twice daily, and the patient was dismissed fourteen days afterward. He continued to enjoy good health for the space of two months. The orbit was lined by a mucous membrane free from irritation. Then the patient began to become anæmic, emaciated rapidly, experienced pain and a feeling of heaviness and fulness in the epigastric region, and, at the end of the month of October, the lower border of the liver could be felt, thickened, hard, and nodular. From the middle of November the patient could not leave his bed, began to be feverish, the liver constantly increased in size, could be felt as a nodular tumor through every part of the right side of the abdomen, extending as far down as the crest of the ilium. By the middle of December, ascites, and anasarca of the lower extremities were present, the vital powers of the patient constantly diminishing, but with slight fever only. At times he coughed and experienced a feeling of dyspnœa without our being able to demonstrate infarcta by percussion or auscultation. The sputa were scant, white, and slimy. Enlargement of the spleen could not be demonstrated. The malady had reached its *ultimate stage*, that of generalization by metastasis upon the most important parenchymatous organs, of which in

this case we may with certainty consider the liver, the lungs in all probability, as attacked.

On the 7th of January, 1868, the patient died of exhaustion.

The post-mortem examination was made in my presence by the attending physician, Dr. Francis Wolf, of Heidelberg. In the *lungs* there were numerous lumps, partly yellow and partly blackish-gray, all of very soft consistence. These lumps were in part scattered very irregularly throughout both lungs, in part situated in the peripheral portion of its tissue, forming prominences on the pleura. On the larger ones, a distinct flattening of the surface, projecting beyond the plane of the pleura, was noticeable. This was caused by friction and pressure against the parietal portion of this membrane. Their boundaries were sharply defined in the pleura, but not in the same degree in the tissue of the lungs, yet sufficiently so to distinguish the several accumulations of pseudoplasma from the surrounding and still normal pulmonary tissue. The size of these lumps varied from that of a cherry-stone to that of a hazel-nut, the largest not exceeding a walnut.

The heart was normal in size, its valves normal, but its muscular walls had undergone fatty degeneration.

The *liver* was enormously enlarged to three or four times its ordinary volume. Its surface irregularly nodular, with numerous small and large black, spherical elevations, several of which had large, stellate, gray and deep cicatrices in the centre of their free surfaces. There were, however, no superficial ulcerations nor abnormal

adhesions to the adjacent tissues. On section, there remained only small, circumscribed islands of the healthy tissue of the liver. By far the greater portion of the section was occupied by the cut surfaces of the tumors. These were generally larger than a cherry, and more or less rounded; one of them, however, attaining the size of a child's head. A small number were yellowish, but the majority of a blackish color, of soft consistence, and their separation from the neighboring tissues rather sharply defined. Aside from these tumors, so variable in diameter, we also found in the degenerated liver larger cysts whose cavities were traversed by different intersecting membranous septa, and filled with a muddy yellowish fluid.

On the *peritoneum* there were situated a number of smaller, black, and separated tumors.

In the kidneys and spleen none could be discovered.

The brain also proved to be without secondary tumors; *the posterior part of the orbit*, however, *was perforated*, the black mass invaded the ethmoidal cells and frontal sinuses, and in the anterior and middle fossæ of the cranium had destroyed the chiasma of the optic nerves in three-fourths of its extent, and also the portion of the substance of the cerebrum adjoining it, and had made its way through the destroyed sphenoidal cells and the fissura orbitalis superior to the other (the right) orbit. The trunk of the right optic nerve appeared unchanged; and though it entered a black, discolored chiasma, the patient had never complained of loss of sight, and at an examination about fourteen days previous to his death, the right eye had been found healthy in structure and

function. The left optic trunk and the adjoining part of the optic commissure were completely destroyed. The portion of tumor which had encroached on the brain might be said to be of the size of a hen's egg. Instead of the two optic tracts, a common blackish-gray cord continued a short distance into the brain. Nevertheless no cerebral difficulty worthy of mention ensued.

In other organs there was nothing abnormal found.

Of the brain and lungs I took pieces of considerable size with me for more exact examination, besides carrying away the entire liver.

The tumors embedded in the *latter* consisted of round cells, with large nuclei and a narrow ring of protoplasma. A rather abundant, hyaline, intercellular substance separated them. Among the unpigmented cells there lay also very many pigmented ones not differing from the others in size or shape. The pigment had collected most compactly in the vicinity of the nucleus, and was more scanty in the peripheral zone of the protoplasma. Thus the nucleus itself sometimes had the appearance of being pigmented. If, however, the adjustment with the higher powers was carefully changed, the brown pigment-granules were found most thickly accumulated in the zone immediately around the bright nucleus. The lobuli of the tumor were traversed rather abundantly in all directions by broad, thin-walled blood-vessels. In thin sections it was discovered that the layers of cells were denser around the vascular tubes than elsewhere; they also adhered more closely to each other there than in other places.

The tissue of the liver in the immediate vicinity was

degenerated to connective tissue, and between the parallel slack fibres there penetrated rows of nucleated round cells proceeding from the sarcomatous tumor, thus demonstrating a direct extension of the pseudoplasma into the neighboring tissues. In other places, however, there were situated in this layer of connective tissue surrounding the tumor, large numbers of lymphoid elements—granulation cells—which were continued as far as the border of the tumor, and there had gone over into sarcoma cells: growth of tumors by transformation from embryonic cells.

The above-mentioned layer of connective tissue surrounding the tumor was very narrow, but in a few places macroscopically distinguishable as a fine white line, so that the metastatic tumors in part had the appearance of being encapsuled. In the neighborhood of this ring, and indeed in a lesser degree throughout the whole liver, the interstitial connective tissue (Glisson's capsule) was hypertrophied.

The metastatic tumors in the *lungs* manifested relations entirely similar. The size, structure, and disposition of their cells, as also of their intercellular substance and blood-vessels, were exactly those of the tumors in the liver. Although, as a rule, also circumscribed, they were not encircled by so marked a ring of connective tissue, and the elements penetrated more freely into the neighboring tissue. In no place could there be found a dissemination of isolated sarcoma-cells in the parenchyma of the lungs; but wherever sarcoma elements were present, they were either in direct communication

with the larger tumor, or they had collected in more extensive accumulations in the tissue: formation of smaller secondary deposits.

The chiasma of the optic nerves was completely changed into a grayish-black mass, connected to the tumor, which penetrated from the posterior part of the orbit into the cranium. The right optic nerve alone was still white and normal on section. The microscopical examination confirmed this, but its fibrous aspect disappeared at its entrance into the chiasma, and was replaced by the pseudoplasma. This proved to be composed of round cells with large nuclei, brilliant nucleoli, and narrow zones of protoplasma, embedded in a scanty, hyaline, intercellular substance. The cells were chiefly unpigmented; and disseminated among them, isolated and in clusters, there were found brown pigment-cells which in part were entirely like the above-described unpigmented sarcoma-cells, but chiefly differed from them in not having a visible white nucleus with nucleolus, but the whole cell was occupied by two or more smaller or larger brown granules (Fig. 44. b), of the size and shape of the nuclei of the other cells, and between which there was a lighter hyaline substance. Thus the contents of the cells were split into a number of lumps, which in themselves were distinctly circumscribed and recognizable. Many of the unpigmented cells were also of the same composition, so that, aside from the simple nucleated cells, they were found with cleft contents in no less number. In other cells the lumps themselves lay further from each other, yet near

enough to make us consider them as proceeding from a common origin, so much the more as all forms of the consecutive stages of transition were present in great numbers. I could not abstain from considering this cleaving, so analogous to the segmentation of the vitellus, as a form of cell-multiplication; yet *Prof. v. Recklinghausen*, as on the occasion of a friendly visit he saw my specimens and illustrations, called my attention to the fact that they certainly were *cells containing blood-globules*. In truth, the lumps embedded in the protoplasma were similar to the blood-globules both in size and structure. The brown and pigmented lumps can be explained by transformation of the coloring matter of the blood. I had not thought of the occurrence of cells containing blood-globules in tumors, but find the picture so marked that I can only add my approval to the explanation of so excellent a pathologist.

In the blackish-gray tumors which occupied the chiasma and its vicinity, every fibrous arrangement of nerve-substance had been destroyed. At the margin it for the most part reappeared at a very distinct boundary. In the limiting layer there were embedded lymphoid and small nucleated cells with brilliant nucleoli, which gave plain evidence of the advance of the pseudoplasma. All portions of the tumor within the cranium were traversed by numerous blood-vessels, here and there having rather thick coats. Fatty degeneration or other conditions of retrogressive metamorphosis were not present.

CASE XIII.—*Unpigmented, simple, choroidal Sarcoma of spindle-shaped Cells. Recovery by Enucleatio bulbi in the stage of Glaucomatous Inflammation.*

The observation of this case I owe to *Dr. Walter*, of Offenbach, who placed at my disposal the following history of the case, and also the anatomical specimen. I am particularly indebted to the learned doctor for his description of the case, as it is not only of pathological and anatomical, but also of very high practical interest, since the knowledge of the disease affords an essential contribution to the data of the diagnosis of such cases, which latter is not altogether easy in its early stages. I will give the history of the case in the words of *Dr. Walter*.

History of the Case.

Mr. S. S., shoemaker, of Offenbach, a medium-sized man, formerly always healthy, æt. 52, experienced about three years ago a feeling of tenseness in the right eye, without having noticed any change in his power of vision. Only at a later period the patient became aware of a gradually increasing and peculiar distortion of objects which he particularly remarked when looking at large coin. As late as August, 1864, he presented himself to me, having already consulted many other physicians at different times. His sight was constantly growing worse, and he noticed that the internal portion of his field of vision was wanting. If in the street he closed his left eye, he could only see the row of houses upon his right. He came to me with

the assertion that others had made the diagnosis of detachment of the retina, a fact which my examination confirmed. The artificial leech was applied experimentally, but as this was without benefit I counselled him to wait patiently, and for the time being not employ anything. In the beginning of the year 1865, the power of vision was completely annihilated, although the portion of retina which was detached in the form of a tumor did not seem to have grown larger. The sensibility of the eye also appeared to have remained the same until, suddenly, towards the middle of May it began to be more troublesome, and in a few days augmented to severe and tormenting pains, for the relief of which the patient again, after a longer interval of absence, applied to me. The globe was very tense, the cornea insensible, the conjunctiva injected, lachrymation profuse, the pupil rigid, immovable, and of irregular shape, the anterior chamber shallow, its contents slightly turbid; in short, all the symptoms of a severe intraocular pressure were present. The patient no longer could pass a night in sleep on account of the tearing and boring pains in his head; finally the conjunctiva of the globe became swollen, so that in twenty-four hours œdematous folds projected from every side over the edge of the cornea. The system in general participated in the process; fever, loss of appetite, and debility being present. The patient consented to an iridectomy, from which it seemed probable that the pain would be mitigated. After the operation had been performed (the end of May), the patient being in a profound chloroform narcosis, all the pain disappeared, and for a short period subsequently the

patient was enabled to rest, and appeared in a measure to regain his strength. But soon after, similar though by far less severe pains instituted themselves, especially in the right half of the head. This induced us (Drs. Felde, Boehm, and myself) to puncture the eyeball, as the patient would not permit us to extirpate it. The paracentesis also produced a temporary remission, but in a few days the pain was again renewed, accompanied by severe inflammatory symptoms and participation of the whole system.

As we considered the already proposed operation of enucleation of the globe necessary for the safety of the other eye, the patient finally came to the conclusion to have it performed. It was undertaken July 5th, 1865, the patient being under the influence of chloroform, without hemorrhage or any other unexpected difficulty having presented itself; was followed by a rapid convalescence, and resulted in a cessation of all pain within twenty-four hours. A week after the operation an iritis and choroiditis formed in the left eye, but yielded to the influence of mydriatic and antiphlogistic treatment, slowly but steadily, so that, at the end of October, the patient (who has been presbyopic for years) reads No. 1, Taeger, with difficulty, but No. 3 quite fluently with lens 7. The extirpated eyeball was laid in a dilute solution of chromate of potassium, and a section made several weeks after. A tumor, the cause of the detachment of the retina, was brought to view on the posterior wall. The eyeball was transferred to Prof. Knapp, of Heidelberg, for more minute investigation.

DR. WALTER.

Anatomical Examination of the Eyeball.

The globe had been divided in an antero-posterior direction, and was preserved in alcohol. In one half the retina was detached like a funnel, and hung posteriorly to the optic nerve, anteriorly to the ora serrata, whilst its central anterior portion was loosely glued to the posterior surface of the normal lens. The remaining portions of this half of the globe did not present any abnormality.

In the other half of the globe, the cornea, sclerotic, ciliary body, iris, and lens appeared normal; the two latter nearer than usual to the posterior surface of the cornea. In the middle of the posterior ocular space, a tumor about the size of a hazel-nut (8 to 9 mm. in length, 7 to 8 in breadth), roundish oval (Fig. 50. tu), was situated upon the internal surface of the capsule of the eye. Its entire surface was covered by the retina, which, being attached to the ora serrata, applied itself anteriorly to the posterior surface of the lens (Fig. 50. re), and then folded itself like a cord and bent back toward the tumor, and clothed this as far as its posterior boundary (Fig. 50. ch_1), where the choroid was slightly thickened. The remainder of the choroid (Fig. 50. ch) appeared normal and was closely applied to the sclerotic, but was bare of retina. A section made from before backward through the tumor exposes its interior. The cut surface (Fig. 51. tu) appears uniformly white and granular, the different granules generally of the size of millet-seeds, and lying densely together without any visible intervening tissue. Under the micro-

scope with low powers a multitude of smaller granules are seen between the larger. The retina (Fig. 51. re) can easily be detached from the tumor. The surface of the latter exposed in this manner has a number of black spots, and on the cut surface we can perceive that this coloration in several places (Fig. 51. p) invades the most superficial layers of the tissue of the growth itself. On the borders of the latter the choroid appears thickened (Fig. 51. ch). In the centre of its base it is intimately connected to the sclerotic, and its former position only slightly indicated by a black punctation (Fig. 51. m).

The minute structure of the tumor proved to be that of a pure sarcoma of spindle-shaped cells. Elongated and rather narrow (3 to 6 μ in breadth), spindle-shaped cells, each with an elongated nucleus and well-marked nucleolus, lay in some places very densely together, and parallel (Fig. 52); in others they intersected each other at different angles in a hyaline intercellular substance (Fig. 53). The contents of the cells were fine and distinctly punctated, as also the nucleus, which was generally elongated, and now and then double in one cell. The quantity of intercellular substance varied very much in different places of the tumor, so that, wherever the cells lay parallel to each other, very little of it could be seen; but, on the other hand, wherever they were arranged more or less irregularly, and as if superposed, the hyaline intercellular substance proved to be very abundant, so that it occupied more space than the cells themselves (Fig. 53).

In order to trace the whole structure of the tumor in

its several divisions, its development and growth, I hardened it in pure alcohol, and embedded it in a hardening composition of oil and wax. By this proceeding I was enabled to make fine and continuous sections through the whole tumor and the neighboring parts. In this manner the compact mass was shown to be resolved into very numerous round clusters, which inclosed in their interiors dense accumulations of fusiform cells, but which were separated by a loose vascular tissue, but sparingly supplied with cells, and rich in intercellular substance. The composition of oil and wax had penetrated into the interstices of this tissue, and interfered considerably with the microscopical image, although it was easily discernible by its appearance. I then again removed the wax by laying the sections in chloroform during the night. This dissolved the composition of oil and wax, without attacking the elements of the tissue.*

The rows of bundles of spindle-shaped cells were not regularly arranged, but intersected each other at various angles.

By far the greater portion of the tumor consisted of pure, unpigmented, fusiform cells; only on the periphery, and particularly at the base and its borders, were

* When preparations are transferred from pure alcohol into a composition of oil and wax, which has become somewhat cool, but is still fluid, the composition does not penetrate so easily into the lacunæ of the tissue. In granular and fragile tissues it is of advantage to allow the fluid mass to penetrate into them, for the tissue then becomes more resistant, and can be cut without crumbling. It was very agreeable to me to have found in chloroform a means of dissolving the wax afterward, without changing the elements of the tissue.

oval and round elements to be found. The latter, however, did not possess the characteristics of the round-celled sarcoma, but were embryonic cells in a stage of transition to the spindle-shaped. The origin of the disease under consideration can be regarded as typical of the formation of tumors, according to the process of *embryonic development.* The tumor rose rather abruptly from the choroid, and on the border of its base the most internal layer of Haller's vascular layer could be seen, as well as the neighboring boundary of the chorio-capillaris, infiltrated with dense accumulations of embryonic or granulation cells (Fig. 54. a a_1). In the vicinity the choroid was perfectly normal in all its layers, and lymphoid cells were only lying scattered throughout its tissue in small quantities, as is also found in its physiological condition. The accumulation of embryonic cells increased rapidly toward the tumor, and lifted the internal choroidal layers. Precisely the same typical relations we have already noticed in a previous case (Case IX., Fig. 36), in which, however, the origin of the tumor did not take place according to the type of embryonic development, but according to that of physiological growth (consequently, without the intervention of embryonic cells), by direct hypergenesis of the elements of the mother-tissue. In the case before us, embryonic cells were present throughout the whole periphery of the pseudoplasma, most abundantly on the borders of the base, where the growth passed over into the healthy choroid.

The granulation cells became transformed into fusi-

form ones by becoming oval, and then spindle-shaped. Fig. 55 represents such a transition. At *a*, embryonic cells alone are seen, which are conspicuous in this place by a brilliant nucleolus, and a distinct ring of protoplasma; whilst further removed, in their earlier stages, they are finely and uniformly dotted, and without protoplasma, and therefore appear more like nuclei. At *b*, Fig. 55, short elongated cells, with distinct nucleus and shining nucleolus, are seen lying between the round embryonic cells; and at *c*, narrow fusiform cells alone lying beside each other, with nuclei, which appear narrower and oval, as if they had been compressed. Here and there two nuclei can also be seen in one fusiform cell.

In several places on the border and periphery, elements of uniform shape and of a brownish-black color, intermingled as above described, and even the embryonic cells were already pigmented (Fig. 56). In several of them I believe I have distinctly seen two nuclei, although the occurrence of this is of late a subject of much controversy, since similar appearances are produced by two cells lying near or over each other.

Pigmentation in this sarcoma was, however, not yet very extended, and was limited to the pigmented spots (section of the tumor, Fig. 51) microscopically visible.

Consequently, the origin and growth of the tumor by the intervention of embryonic cells from the periphery was clearly demonstrated.

In regard to its relations with the mother-tissue and neighboring textures, it belonged to the *diffusely limited* tumors. It is very seldom, and only in the earliest

stages, that the sarcoma is found as definitely circumscribed as the homologous (histioid) tumors, such as fibroma, lipoma, etc. The adjacent tissues were, in this instance, in nowise pushed backward by the tumor, nor had they become thickened—capsule-like—around it, but were beset with embryonic cells, which indicated the certain extension of the pseudoplasma into the continuity of the tissue. However, since this invasion of the new formation terminated at a distinct boundary (Fig. 54. a_1), and secondary herds were manifest nowhere in the neighborhood—for the sclerotic uninterruptedly closed the tumor in from externally, and the retina from internally, and all the remaining portions of the eye were found intact—we must still consider the same, from an *anatomical stand-point*, as a purely *local malady*, and infection of the neighboring parts not having been demonstrated.

From a *clinical* stand-point the prognosis is not quite so favorable, for it was shown that the tumor had arrived at a tolerably mature age, during which very grave symptoms of irritation of the eyeball had instituted themselves several times. These, however, by themselves do not prove the existence of infection from the tumor, but were of a glaucomatous nature, as occur in all processes which cause an increase of the contents of the interior of the globe, usually due to a hypersecretion into the vitreous space.

The *diagnosis* of pseudoplasma in the eye was perfectly correct, and also the indication, founded on it, for *enucleatio bulbi.*

The further progress of the case until at present [the

end of February, 1868] confirmed the favorable prognosis, for *Dr. Walter* writes that, $2\frac{3}{4}$ years after the operation, no local relapse nor any other disease had troubled the patient, who, during that interval, had had no difficulty with the other eye, and could follow his occupation without inconvenience. Although we cannot altogether deny the possibility of a metastasis, every unprejudiced person must certainly agree with me in regarding it as very improbable, when he considers how circumscribed [though pernicious in its nature] the primary affection was, and that no relapse until now, $2\frac{3}{4}$ years after, has made its appearance. The tumor in this instance was as yet purely a local malady, and was completely *eradicated by the operation.*

Case XIV.—*White, vascular* (*telangiectatic*) *Sarcoma of the Choroid. Recovery after Enucleatio bulbi.*

Jos. Weichel, æt. 30, of Frankenthal, came to me on the 2d of January, 1867, with the complaint that for five or six weeks the sight of his right eye had been much worse than formerly. He was very pale, walked slowly and with decrepitude, and in short presented the symptoms of evident exhaustion. On inquiring into the cause, he communicated to me that he has been suffering from caries of the dorsal portion of several ribs for years, and that at present there remained a large suppurating wound. This statement was confirmed by the physical examination without revealing any other anomaly. Up-

on examination of his organs of vision, both eyes were found to be normal in their outer appearance, in their power of motion and tension; the left eye with full power of vision, the right with $\frac{1}{100}$ of the normal, the patient being able to count fingers with it at a distance of two feet. The field of vision was considerably narrowed superiorly and externally. Iris and anterior chamber normal, pupil reacting well, lens transparent; but the vitreous of such a dense, smoky opacity, and on the nasal side filled with black floating flakes, that the fundus of the eye could only be illuminated of a dark reddish color. In its posterior division, somewhat internally and inferiorly, I saw a flat, slightly projecting, yellowish disc, about four times the diameter of the optic papilla in breadth. Its surface could be illuminated of a brighter red than the remainder of the ocular fundus, and was traversed by several tortuous red streaks, and covered with from six to eight elongated, light red spots, which could distinctly be recognized as extravasata, as well as the streaks as blood-vessels. The flat prominence went over into the remainder of the ocular fundus so gradually that I was not positive whether I had a circumscribed, plastic, retinal exudation before me, or a retinal or subretinal tumor. The formed and diffuse opacities of the vitreous I ascribed to apoplexies and inflammatory exudations. I prescribed frictions with gray salve on the forehead, and informed the patient that he was suffering of a severe malady which required careful observation, although, in consideration of his general debility, I could not counsel a more severe treatment.

The patient presented himself for examination regularly every eight to fourteen days, and was treated with frictions to the forehead. The disease progressed in such a manner that now and then the eccentric power of vision improved remarkably ; superiorly, externally, and in the centre, a circular section of the field of vision, occupying the outer portion of the entire field, was completely wanting, whilst the more peripheral portions were still preserved. The flat elevation in the fundus of the eye was yet more prominent internally, retained its yellow color and its small irregular vessels, whilst the red spots on its surface were very variable in the intensity of their color and in their extent, in number and in form. The prominence spread somewhat in breadth also, plainly advanced nearer to the centre of the eyeball, retained its round shape, and still could be distinctly recognized as a globular tumor by the employment of very strong convex glasses (No. 6) behind the ophthalmoscope. Even with reflected light it could be seen very well when the pupil was dilated.

The distinct button shape, the sharp limitation, the white-yellow reflection, the blood-vessels and hemorrhages on the surface, the constant growth, the lack of any movement of the surface, the want of any inflammation, and the absence of cysticercus in the Palatinate, were all considerations which did not allow me to think of any disease other than tumor. The retina was not detached, therefore must have been fused with the tumor or bridged over by it. It could not simply cover the tumor, for in that case large retinal vessels, with their char-

acteristic ramifications, should have been recognized with the ophthalmoscope on the rather extensive surface of the growth situated near the optic nerve. The tumor, according to my experience in intraocular growths, could only originate in the choroid, or in the retina itself. The color, and the complete disappearance of the characteristic retinal vessels on the surface of the tumor, favored the latter; the peculiar structural elements of the retina would in this case have been destroyed by the pseudoplasma. Though all this accorded so well with the anatomical facts, one circumstance still prevented me from placing my diagnosis upon retinal tumor; and this was my *individual* clinical and anatomical experience, according to which all tumors in the interior of the eye, and *not occurring in children*, proceed from the *choroid*. Standard authors are, it is true, of a different opinion; but I trust that people will not think ill of me if that which I had obtained from my own experience should be more conclusive to me than the affirmations of writers, none of whom (as far as I can gather and judge from medical literature) has anatomically proved with certainty that an intraocular pseudoplasma in an adult had originated in the retina. I will not deny the possibility of its occurrence, for it would be highly remarkable if primary tumors could not develop in the retinæ of adults as well as in children. As I knew that these were not observed with certainty, I considered it my duty to draw my conclusions from my present experience, and this urged me to the assumption of a choroidal tumor. The retina, in this case, must have been either pierced and

covered by it, or grown to it so intimately that its tissue was involved in the pseudoplasma until no longer distinguishable. The latter appeared to me more probable, and indeed from my own experience again, since the retina, generally, in tumors of the choroid, is found detached or glued to the superficial layer of the tumor. This cohesion usually is a very loose one, so that in most cases the retina can easily be lifted from the pseudoplasma. Still, it is conceivable that a more intimate fusion into each other should occur, and make the delicate elements of the tissue and the blood-vessels of the retina unrecognizable.

The day before the operation the power of vision had again become somewhat better, the patient counting fingers at a distance of from four to five feet. I searched in vain this time again, as I had done often before, for blood-vessels of the fundus and the papilla.

The whitish-yellow, shining, button-shaped growth in the interior, and the defect in the field of vision, were in the state above described. In all other places the fundus could be illuminated of a dull red. Anterior chamber, iris, reaction of the pupil, tension, and appearance of the eyeball, normal. In this condition, in which no pain or other troubles were present, the patient having a field of vision three-fourths of the normal extent, and in addition the ability of counting fingers at a distance of four to five feet, I proposed enucleatio bulbi, to which he, not without reluctance, consented.

It was performed on the 16th of June, 1867; patient under chloroform, no accident intervening, and wound

healing by first intention, so that the patient left the hospital June 25th, very much comforted in spirit, and wearing an artificial eye.

Anatomical Examination of the Globe.

As the tumor must have been situated internally and inferiorly, and could not well project into the vitreous farther than the axis of the eye, I laid the globe open by a meridional section in such a manner that it was divided into an inferior-internal and a superior-external half. The former contained the optic nerve and the tumor, the latter nothing of the pseudoplasma.

In order to be assured that I would not interfere with the surface of the suspected tumor in my section, I made a cut with a razor through the middle of the cornea, pupil, and lens. I then completed it with a pair of scissors, one blade of which I carefully inserted for a short distance into the eyeball. The *vitreous* was in general viscid and transparent, but was traversed by a few delicate white opacities in the shape of streaks and spots. In these opacities the microscope disclosed lymphoid bodies, and larger cells containing nuclei. In the posterior division of the inferior-internal half of the globe, a tumor (Fig. 57), of the size of a hazel-nut, and almost perfectly semi-spherical, and covered by a fine transparent layer of tissue, was present. In this, and immediately under it, numerous small vessels, dividing into stripes and stellate forms (Fig. 57. va), could be seen, besides round and elongated hemorrhagic spots. The retina

clothed the choroid normally all around the tumor, and appeared to continue over the whole surface of the tumor as a smooth covering, which, however, was not the case, as we shall demonstrate hereafter. The choroid, the ciliary body, and the remaining parts of this division of the globe had no abnormality. The other half of the eyeball was perfectly normal, the retina appearing especially healthy as it was applied to the choroid throughout its whole extent. I now made a shallow incision into the tumor, and found it to be a soft, yellowish-white mass, homogeneous in appearance, and containing a considerable quantity of blood. Several detached portions of the tumor for the most part consisted of round cells, and here and there fusiform ones, with large nuclei and brilliant nucleoli.

The eye was then laid in alcohol, and six months afterward, being in a well-hardened state, subjected to a minute microscopical examination. At first I again cut the half of the globe above described into two parts by a meridional section, which ran through the middle of the tumor, optic nerve, and cornea (Fig. 58). Thus highly remarkable relations were brought to view. The button-shaped tumor was seated upon the sclerotic, to which it adhered by a short, narrow pedicle (Fig. 58. tu), but was separated from it by a thin layer of pigmented tissue, which on both sides went over into the normal choroid (ch) without interruption. But the retina (re) also approached the pedicle of the tumor from both sides, and terminated in a point upon it, so that the tumor seemed to have grown from the retina, and to have

thinned the choroid, lying behind it, by pressure. The tumor itself then enlarged suddenly, and covered the adjacent retina as far as the entrance of the optic nerve. Its cut surface was finely granular, with traces of vascular canals and small dark-red hemorrhagic spots, situated chiefly at the periphery.

I then embedded one half of the tumor, which had been well hardened in alcohol, with all the neighboring parts in a composition of wax and oil; then made sections through the whole tumor and the neighboring membranes of the eye, and indeed so many that I laid almost the entire half of the tumor into successive microscopical sections. In this manner I revealed how it was connected to the neighboring tissues, its origin, its structure, and growth. I preserved a few of the thicker sections in *Canada balsam*, all the others in glycerine, which, unlike the balsam, does not destroy the distinctness of the finer elements by its extraordinary transparency.

At the border of the tumor I in this manner obtained sections which revealed in the *stroma of the choroid* an intumescence, perfectly circumscribed, and in its greatest thickness measuring only from two to three times that of the choroid. The pseudoplasma was situated on the internal layer of the tunica vasculosa Halleri, was bounded externally by it, the suprachoroidea, and sclerotic; internally by the choriocapillaris, the hyaline, and pigmentary layers; and over it the *well-preserved retina*, clothing it as usual. Other sections revealed the growth of the pseudoplasma, proliferating in the choroid to an ovoid tumor (Fig. 59. tu), on the exterior of which some stroma of

the choroid (Fig. 59. ch) was still situated, and upon the internal surface the loose pigment layer (Fig. 59. pi) was present.

The retina (Fig. 59. re) was bridged across this; its regular succession of layers becoming destroyed at the beginning of the tumor, and being reduced to an outer granular (Fig. 59. gr), and an inner fibrous (Fig. 59. fi) layer. Thus the transverse diameter of the retina had become somewhat thicker by hypertrophy of its granular alyers. In the tumor there were many sections of vessels, among which many of considerable calibre (Fig. 59. va). Another *very remarkable peculiarity was the condition of the blood-vessels in the neighboring choroid. They were extraordinarily enlarged on the side towards the optic nerve* (Fig. 59. ge), *so that they had completely compressed the stroma, and had caused numerous extravasations;* on the side towards the equator of the globe (Fig. 59. ge) they were, on the contrary, empty and by no means widened. In order to explain this remarkable appearance, we must remember that the vessels for the supply of blood to the choroid enter at the posterior portion of the globe, not far from the optic nerve, and on their way forward resolve themselves into capillaries through the entire choroid, the blood of which passes off by the vasa vorticosa which perforate the globe at its equator. The tumor, situated between the optic nerve and the equator, must of necessity press upon the blood-vessels in their course from the optic nerve to the equator, it being immaterial whether arteries or veins, as the currents of both run toward the equator, whilst, on the

other side of the tumor, there is no obstacle to the flow of blood. This pressure of the tumor upon the blood-vessels also caused the hemorrhagic spots which I had recognized as opacities of the vitreous, and which were confirmed as such by the microscope. Hence we have a mode of explaining why the power of vision was continually wavering between better and worse during the last few months of the disease.

Other sections through the tumor showed that it was constantly enlarging, the inner layer of the choroid gradually becoming thinner on the apex of the tumor, until finally both it and the retina covering it were perforated. The pseudoplasma now proliferated freely into the vitreous, but was still limited by a delicate fibrous layer (Fig. 60. h).

At the borders it reflected itself upon the retina (Fig. 60. re). The minutiæ of this very interesting transverse section could be seen with the naked eye, but became very distinct when strongly magnified with a lens. Fig. 60 represents such a transverse section. The sclerotic (scl) is intact. The choroid (ch) near the optic nerve full of vascular spaces enormously enlarged, on the side toward the equator (ch), free from them, and normal. In it the uniform white granular pseudoplasma is seen as an ovoid tumor, compressing its tissue on both sides, and protruding internally into the vitreous space through a rather large opening. There it forms a spherical tumor, only two-thirds of which had been intersected by the cut represented in the figure. The boundaries of the remaining third [which

was identical with the other two-thirds in structure], and also the inner border of the tumor, are indicated by the dotted line (k). As far as the pseudoplasma (tu) was enclosed in the membranes of the eye, its substance was dense and granular; after perforation it became coarsely fasciculated. Most of the bundles of tissue were intersected longitudinally by the section, yet there were also numerous transverse sections of the same (l) which enclosed round cavities in their interiors, which under high magnifying powers proved to be lumina of blood-vessels. The retina (re) remained applied to the choroid everywhere, and had, like the latter, been raised and perforated by the tumor. It became pointed as it terminated, without having suffered any loss of substance, and without having entered upon any proliferating process demonstrable by low powers.

The *minute structure* of the pseudoplasma manifested itself as a white vascular sarcoma of rare beauty. All around its sides it had compressed the tissue of the choroid, so that it was hemmed in by the latter as by a wall. It was very distinct, since the pigmented stroma cells, which were abundantly disseminated in it, marked the limit of the normal tissue with the greatest precision. Beyond this wall no trace of foreign elements could be found in the choroid. On the pigmented wall there lay, forming the outer layer of the tumor, densely-packed fusiform cells with large, generally single nuclei and bright nucleoli. Close beside these the round and oval cells already came to view with their large, well-marked nuclei and brilliant nucleoli (Fig. 61. A *and* B).

They were embedded partly in fine and partly in coarse intercellular substance (Fig. 61. A *and* B), with fibres running tolerably parallel in such a manner, however, that the several tracts appeared undulating at the side and over each other (Fig. 61. B). Between them the cells and nuclei lay either isolated or collected in short rows and clusters. This excellent fibrous arrangement of the intercellular substance was found only in the vicinity of the mother tissue, the choroid, from which it had abstracted a few pigmented cells (Fig. 61. B b). In the centre of the tumor, as well in that portion encircled by the choroid (Fig. 60. tu) as in that which had grown into the vitreous space (Fig. 60. tu), after having perforated the retina and choroid, the intercellular substance was finely granulated. In thin sections, wherever the cells had fallen out, the latter presented itself as a delicate network (Fig. 62. r).

The cells themselves were, in many places, without the distinct circumscribed envelope of protoplasma (Fig. 63. d, k, sp), and then lay as well-defined, smaller and larger, round or elongated nuclei in a delicate, very finely dotted intercellular substance, which could be considered as a confluent mass of protoplasma. Several of these cells were double or multiple in a well-marked common envelope of protoplasma (Fig. 63. C, *and* Fig. 61. B c), which, in accordance with the usual theory of cell-generation, we would consider as an endogenous multiplication of nuclei. In fine sections, however, we perceived that this formation of outlines in protoplasma was purely accidental, for on the borders two or more

cells also lay in a continuous mass of protoplasma, which was uninterruptedly connected to the intercellular substance of the denser accumulations of nuclei (Fig. 63. d). In other places the nuclei had uniform protoplasma envelopes (Fig. 63. A a b), with very delicate outlines and scanty granular or fibrous intercellular substance.

The *blood-vessels* formed a conspicuous element in the structure of every portion of the entire tumor. They consisted of wide tubes with thin walls, which, in very abundant and constantly finer ramifications, formed a beautiful network whose meshes enclosed the well-marked sarcoma cells. Only in the very largest (Fig. 62. a a) was it possible to recognize the different coats of physiological blood-vessels: *a*, the homogeneous or, with the highest powers, slightly fibrous internal coat (Fig. 62. i), with the superposed layer of endothelium (Fig. 62. e), appearing granular in the transverse section, if it might not be regarded as a coagulum. This could have been determined with certainty by the reaction with nitrate of silver, were it possible to employ it in hardened preparations; *b*, the elastic coat (Fig. 62. m), consisting principally of longitudinal and transverse fibres in which dark elongated figures were disseminated, which resembled the nuclei of the involuntary muscle cells; *c*, the fibrous coat which was closely applied to the preceding, and whose fibres radiated between the neighboring cells (Fig. 62. c). From these larger vessels smaller ones branched off (Fig. 64. b), in which there was remarked an outer fibrillated appearance, and an inner well-defined contour, generally consisting of a

double line. These then went over into a finer network (Fig. 64. f f), whose tubes were generally empty and compressed. In their coats numerous granules were scattered (capillary nuclei), so that in many places we might have been disposed to look upon these ultimate vessels as connective tissue arranged in areolæ, had we disregarded their continuity with distinct blood-vessels filled with blood-corpuscles. The cells arranged themselves regularly on the blood-vessels in such a manner that a larger vessel was always enclosed by a uniform and thick cell-mantle (Figs. 62, 65, 66). If in a longitudinal section we were successful in exposing a number of blood-vessels—and this was a very frequent occurrence —a utricular appearance was produced. From the principal canal others then branched off (Fig. 65. n c), and these had lateral twigs, whilst all were enclosed in thick cellular sheaths. I could not discover a formation of loops in these vessels, and it was almost impossible to discriminate between the arterial and venous nature of a blood-vessel. From the larger blood-vessels a considerable number of smaller and ultimate branches were constantly given off, apparently at right angles (Figs. 65, 66. c), winding as fine capillary tubes between the cells, and traversing them in such numbers and so densely that occasionally isolated cells were encapsuled by them. They anastomosed with each other in the cellular cloak surrounding the larger vascular canals, and coalesced to form wider tubes in the spaces lying between the cellular cylinders, which we may name in analogy to the structure of certain organs, interlobular spaces. *Consequently the ar-*

rangement of the blood-vessels would be as follows: The arteries which are surrounded by many cellular layers, give off larger branches of similar appearance, which latter constantly grow narrower, but from whose trunks a large number of capillaries branch off throughout their whole course; these again anastomosing in the cellular cylinder surrounding the arterial tube and uniting in the interlobular spaces into venous tubes, which again coalesce to form venous trunks, constantly increasing in size, and which, like the arteries, are enclosed by cylinders of multiple cellular strata. *The entire tumor, therefore, is composed of arterial and venous cellular cylinders with an intercellular network of capillaries.*

The connection of these vessels with those of the mother-tissue—the choroid—could not be mistaken, but it was remarkable that the vascular roots in the tumor were, in general, thinner than their continuations and branches. Also in the portion of the tumor enclosed in the sclerotic (Fig. 60. tu), the vessels were smaller than in the portions vegetating into the vitreous (Fig. 60. tu), although the vessels of the latter were distinctly seen proceeding from those of the former. In this widening of the blood-vessels, the pseudoplasma resembled vascular tumors, but could be distinguished from them, firstly, by the distinct and extended intermediate network of capillaries; and secondly, by the excess of cells over vessels, although the latter were richly developed. The pseudoplasma could therefore be designated only as a vascular cellular tumor, and not as an angioma (tumors consisting only of hyperplastic vascular tissue).

If we investigate the *mode of development* and nature of the pseudoplasma under consideration, we may regard it as a *circumscribed degenerative hypergenesis of the choroid.* On the borders of the tumor we find collected in the stroma of the choroid, at first scantily, afterward in greater abundance, fusiform and round cells, with sharply-defined nuclei. The cells arise and multiply either by segmentation or by the lymphoid bodies originating in the blood, the embryonic cells. Both of these processes could in this case be deduced from the anatomical condition revealed by the microscope. Fig. 61. B, represents a small portion of the tissue on the boundary of the tumor. In it there lay in the fibrous intercellular substance well-marked, larger and smaller granules, which, in part (d), resemble the lymphoid bodies, but in part also manifested themselves as sarcoma nuclei (e) by their sharp contours and their shining nucleoli. Besides, two nuclei (c) were also found enclosed in one protoplasma ring, which was to be regarded as a cell with two nuclei, consequently as in a process of multiplication. In fact, such occurrences are not very frequent. What we usually see are the granules, embedded in a homogeneous or fibrillated basement substance, which at first are transformed into nuclei and then into round or fusiform cells.

In the case before us it was very natural to ascribe the proliferation of cells to the presence of the vessels. In the immediate vicinity of the blood-vessels we saw that lymphoid bodies had accumulated in greater numbers (Fig. 62. 1). The fibres of the external coat of the vessel penetrated between them and passed over into the in-

tercellular tissue of the fully-developed cellular strata. We might, therefore, assume that the formations so similar to the lymphoid cells were situated in the external fibrous coat (adventitia). These spaces of loose cellular tissue around the blood-vessels, more or less full of lymphoid cells, and which are noticed even more distinctly marked in the physiological condition, are, of late, called lymph sheaths. That the beginning of the lymphatic vascular system of vessels is to be searched for in the connective tissue, and particularly in the system of lymph channels, is, according to the reformatory experiments of *Recklinghausen*, constantly becoming more generally adopted and confirmed. That the small canals of this lymphoid tissue are also in direct communication with the interior of the blood-vessels, appears to be more probable. The lymph cells which were observed so conspicuous in the perivascular spaces of our tumor, could be regarded as having originated there (in the connective tissue); but it is just as easy to consider them, as *Cohnheim* declares, as having emigrated through the blood-vessels. I abstain from discussing the greater or lesser probability of these questions from one pathological specimen. To arrive at any positive result it is necessary to make special researches upon this topic, as for instance, *Cohnheim's*. The presence of a large quantity of lymphoid bodies in the perivascular spaces I could confirm in every part of the tumor. They manifested themselves as embryonic cells, which gradually were transformed into nuclei and sarcoma cells. This process could be seen especially well on the smallest vessels (Fig. 63). On the vascular tube (v) with homogeneous walls of double

contour, there were situated lymphoid bodies and smaller and larger nuclei (n) surrounded by protoplasma. The more the lymphoid bodies—embryonic cells (l)—retired from the blood-vessels, the larger they became (k), and the sharper their outlines and the brighter their nucleolus. In a few places (sp) they lay more compactly together, appeared to compress each other, and consequently to become fusiform. All these forms evidently were new formations, and situated in a homogeneous confluent protoplasma. A row (a a_1) of embryonic cells passed through them, and as it progressed went over into a small blood-vessel and participated in the new formation or in the growth of a blood-vessel. As the nuclei continued to develop they were encircled with well-defined rings of protoplasma, and were separated from each other by intercellular tissue, as Fig. 61 .A, a *and* b beautifully represents. All these different stages of development are again found in the cells (Figs. 62, 65, 66), collected as cylinders around the larger blood-vessels. The tumor in every place was still engaged in a process of development, and in no place showed a beginning of retrogressive metamorphosis. The only things abnormal, so to speak, which were encountered, were the *hemorrhages* (Fig. 60. hæ), which had occurred rather frequently in the peripheral layers. The current of blood must have met with a very considerable resistance in the width of the vessels, the fragility of their coats, and the enormous development of cells and intercellular substance. Such a resistance would be more likely to cause rupture just at the periphery, because the counterpressure by the substance

of the tumor itself is evidently less, and also because the younger, more fragile and delicate developments of vessels and cells were situated at this part of the growth.

Of the other tissues of the eye, the *retina and vitreous* alone presented changes. We have already mentioned the latter in the description of the section of the fresh eyeball.

The *retina* was changed only in the limited extent in which it covered the tumor (Fig. 59, gr fi). *Its abnormalities consisted in hypertrophies, i. e. hypergeneses of the connective tissue.* In a few places the multiplication of the granules (Fig. 59. gr) preponderated, so that they were abundantly gathered into a radiated network, and had produced an increase of the transverse section of the retina to double or three times its normal thickness. But in other places the radiating fibres themselves were elongated and thickened, presenting themselves as rigid broad cords and bands, communicating freely with each other. Here and there they grew slightly beyond the limitans externa, and formed loose adhesions with the tissue of the choroid, which was degenerated and beset with sarcoma cells. In no place, however, did this hypertrophy of the retinal connective tissue appear to form tumors, so that we had before us in this case a pure choroidal sarcoma. That, at a later stage, the hypergenesis of the retina which had already been induced would have attained a more advanced and independent growth, and in this manner have caused the development of a mixed tumor (glio-sarcoma) cannot be asserted, but does not seem improbable, when we remember that such tumors—as in Case XI.—occur.

Progress and termination of the disease.—I saw the patient often afterward, and found no trace of irritation in the orbit nor of metastasis to other organs. In January, 1868, however, his general debility increased considerably, and was regarded as the cause of his death by his physician, no abnormality having been observed in the orbit. The strictly circumscribed nature of the tumor, and the radical extirpation reaching far beyond its limits, induced me to consider the case amongst those of permanent cure, though it had been under observation for only seven months after the operation.

XV.—*Inflammatory fibromatous sarcoma of the choroid; Enucleation of the globe; Recovery.*

Valentine Walter, of Rechtenbach, near Bergzabern, a healthy-looking boy of six years, had, a long time ago, received a blow on the left orbital region. Afterward his eye became amaurotic, and upon the nasal side in the region of the equator there appeared, under chronic and slight symptoms of inflammation, an ectasy of the sclerotic, which rose above the level in the shape of a cone, 12 mm. in breadth and 8 mm. in height (Fig. 67. k). The tension of the eyeball was increased, the episclera was covered by a coarse network of thick, tortuous blood-vessels. The cornea was sensitive and perfectly clear, the anterior chamber made shallow by the globular bulging of the iris, the pupil not quite the

middle size, rigid, and beset with small, grayish-brown synechiæ. Through it and the perfectly transparent lens we could distinguish a dull, yellowish-white mass, traversed by a few red streaks, filling, or at least concealing, the interior of the eye as far as the posterior surface of the lens. The appearance presented had a remote similarity to the amaurotic cat's-eye, but differed very essentially from it in the absence of brilliancy in the whitish-yellow mass which occluded the vitreous chamber.

I enucleated the eyeball on the 13th of July, 1865, and immediately made the *anatomical examination*, halving the globe by a meridional section intersecting the middle of the tumor. The sclerotic was thinned at the place of ectasy (dilatation) (Fig. 67. R), otherwise perfectly normal. The choroid (Fig. 67. ch) in this place went over into a tumor (Fig. 67. tu), encroaching considerably on the interior, but everywhere else lined the sclerotic, and presented nothing abnormal. The retina (Fig. 67. re) was separated in its whole extent from the choroid by a perfectly transparent fluid, revealing no form-elements under the microscope, and was compressed into the shape of a funnel between the ora serrata and the optic nerve entrance. Between the lens and the retina there still remained a small portion of the vitreous chamber (Fig. 67. v), with transparent fluid contents. Ciliary body, iris, and lens presented nothing remarkable.

The most striking change in the eye was found under the ectasy of the sclerotic. There, the choroid was detached from the sclerotic in a circle whose diameter was

9 mm., and formed the place of origin for two tumors; one of which (Fig. 67. tu) sprouted toward the interior, was slightly tuberous and covered by the retina, which had become adherent to it; the other (Fig. 67. ei) crowding toward the exterior and causing the ectasy of the sclerotic. The latter consisted of an *abscess*, for its creamy contents proved upon microscopical examination to be ordinary pus.

Its internal wall was constituted by a yellow, fragile membrane, the so-called pyogenetic membrane (Fig. 67. p). This was situated externally upon the sclerotic, internally and in the angles upon the choroid. The abscess was derived from the latter, for we perceived that it reflected itself in the angles and continued on the sclerotic for a short distance (Fig. 67. ch_1). To me it appears beyond question that the abscess at first lay entirely within the choroid, perforated it as it progressed toward the exterior, macerated the sclerotic and produced a bulging outward, but lifted the layers of the choroid (Fig. 67. ch) internal to it from the sclerotic, whilst at the same time these layers constituted a matrix for a sarcomatous pseudoplasma (Fig. 67. tu). The place in the sclerotic macerated by the pus and bulging would, no doubt, have ruptured in a short time and the pus been discharged externally.

The tumor vegetating toward the axis of the eye grew distinctly from the detached, thickened, softened, and pale choroid. It was tough, lobulated, and tuberous, but contained between the several clusters drops of a whitish-yellow creamy pulp, which under the microscope again

proved to be pus. At the base it became narrower, then again increased to a larger tumor, thus bearing quite a resemblance to a fungus. Its pedicle consisted of *fusiform cells*, which here and there had become so densely packed that the microscopical picture appeared streaked almost like fibrous connective tissue. In the body of the tumor the fusiform cells constituted the principal ingredients of its tissue, reaching as far as the surface of the pseudoplasma.

But near them there could also be seen numerous places in which larger and smaller round nucleated cells were embedded, more or less densely, in a fine fibrous intercellular substance. On the borders and periphery of the tumor the smaller cells predominated, so that in this place the characteristics of granulation-tissue were conspicuous. Laterally, longitudinal sections through the tumor and transverse ones through the neighboring choroid revealed abundant accumulations of embryonic cells in the chorio-capillaris. The basement membrane and pigment layer passed across it intact. The stroma of the outer layers was very much softened and thickened by abundant accumulations of compact nucleated fusiform cells, parallel with the pigmented stroma. These two elements, the fusiform and embryonic cells, also entered the tumor directly, the former in the pedicle and centre, the latter toward the periphery.

In several places they were intermingled and embedded in a fibrous intercellular substance, in one place delicate, in another tougher, and itself very variable in quantity. Besides, there were portions in which the

embryonic cells predominated, the intercellular substance being homogeneous and very soft. Such places also constituted the boundaries to distinct small abscesses, where the embryonic cells were no longer situated in a more compact intercellular substance, but were suspended in a viscid fluid.

The entire tumor bore the characteristics of an undeveloped formation, the products of suppurative inflammation and granulating tissue in a well-marked transition to permanent fibro-sarcomatous clusters. As the larger, round, and spindle-shaped cells, with their large nuclei, constitute the denser and greater portion of the tumor, we may assume that the sarcomatous character of the pseudoplasma would constantly have become more marked as the latter developed.

Of the *further progress* of the case I have only agreeable information to communicate.

The wound left by the enucleation healed by first intention, and from that time until at present—end of March, 1868—two and three-fourths years after the operation, the boy has been enjoying excellent health. He desires an artificial eye to be adapted to the movable, though flat, stump.

SECTION II.

GENERAL DESCRIPTION OF CHOROIDAL SARCOMA.

I WILL now endeavor, as I have already done in treating of retinal glioma, to sketch a general and easily-reviewable picture of choroidal sarcoma from the preceding detailed remarks. In so doing I will take into account as much of medical literature as may appear necessary or important for the completion or confirmation of my description. The results of the foregoing observations of cases shall, however, be the basis of the general description.

I.—*Pathological Anatomy of Choroidal Sarcoma.*

A. Macroscopical Condition.

The *appearance* of sarcoma of the choroid is much more varied than that of glioma of the retina. In some cases there is no macroscopical distinction between the two. For instance, the white medullary sarcoma of Case XIII. could not have been distinguished from encephaloid without the aid of the microscope, for, in the fresh state, the cells could be expressed as a tenacious juice, and the tumor itself was as spongy as vascular gliomata—for instance, the relapse of Case XVII. Therefore it also happened that former authors, who based their divisions principally on macroscopically visi-

ble properties, separated neither the medullary forms of sarcoma from glioma nor from carcinoma, since they included all these soft multicellular forms of tumor under the name of encephaloid, or fungous growths. For instance, *Fritschi*, in his detailed description of "Malignant spongy tumors of the eyeball" (Freiburg, i. B., 1843), mentions only fungoid and melanotic tumors. However, the microscope enables us by the conformation of the cellular elements of the intercellular substance and its vascularity, as well as by the arrangement of these parts forming the various growths, to distinguish between the several kinds of tumors. Forms of transition—for instance, *glio-sarcoma*—sometimes occur, and cannot be correctly classified by a hurried preparation of a few microscopical specimens, but only by a thorough study of the structure of all parts of the growth.

Although we find that the simple multicellular white sarcoma resembles glioma and medullary carcinoma in color and succulence, this is still the case when they appear *whitish or yellowish-brown, through increased vascularity*, and when *they are resolved into several parts by simple fatty or inflammatory softening*, as we have observed in Case XV. If such places are noticed on the surface we have the elements of *ulceration*, precisely as in glioma and carcinoma.

When *the intercellular substance of sarcoma is tougher and more fibrillated, and the cellular elements are elongated, spindle-shaped, more or less fibrous and compact, the appearance becomes more or less fibrous*, and then is like certain forms of fibroma, myxoma, myoma, and

even scirrhous carcinoma. Thus the tuberosity of the white sarcoma of fusiform cells in our Case XIII. appeared to the naked eye. The occurrence of abundant blood-vessels and consecutive hemorrhage, as in Case XIV., yields so much the same picture for sarcoma, glioma, and medullary sarcoma, that until lately all these forms were described under the name of fungous hematodes.

The appearance of sarcoma is materially changed by the admixture of pigment. The tumors then appear covered with black dots on the superficial and cut surfaces (Case XIII.), grayish-black, striped or marmorated, diffuse and dirty grayish-black, or more or less pure and deep black (Cases IX. to XII.). The melanotic carcinoma alone then bears a resemblance to it. Again the pigmented sarcoma presents the same variations in regard to softness and toughness as the unpigmented, according to the quantity of small and round cells with homogeneous and scanty intercellular substance (Cases XI. and XII.) they contain, or according to the large and elongated cells, with scanty and denser fibrous intercellular substance (Cases IX., X., and XI.).

B. Minute structure of developed sarcoma.

The component parts of a finished sarcoma are :

1. *Cells.* The cellular elements of sarcoma vary in *form.* We remark *small round cells*, whose nuclei comprise by far their greatest portion, since only a narrow ring of protoplasma is found around them. This is often

collected on one side, through displacement by the nucleus. Such cells must be considered as early formations, and are found chiefly in those places where the growth of the tumor is most marked. In denser portions of the pseudoplasma the nucleus is surrounded by a broader layer of the cell-contents, which, especially when other ingredients, as pigment and fat are present, often completely conceal the nucleus. By changing the adjustment of the microscope, and by the resort to chemical agents, chiefly acetic acid, it is always possible to bring the nucleus into view. The outline of the cell, *i.e.*, the outer boundary of its contents, never appears very sharply defined in the earlier forms, so that a uniformly amorphous or slightly granular protoplasma encircles the nucleus. However, in portions of the tumor more advanced in development, the boundary of the protoplasma is marked as a more or less well-defined line, termed *cell-wall.* At the same time the *round cells*, constantly *enlarge*, usually to about two or three times the size of white blood-corpuscles.

Elongated cells, with entirely the same properties as the round ones above described, are very frequently met with in sarcoma. They constitute a stage of transition to the spindle-shaped cells. They are present in sarcoma at least as often as the round cells. Their nucleus is sometimes round, but generally somewhat oval; their size very variable as well in breadth as in length. Tumors with elements of this nature are called *fibroplastic* by the French.

In a few cases only, small fusiform cells which are

narrow as well as short (Case XIII., Figs. 52 and 53) are seen distributed throughout the whole tumor; in other cases the greater portion is composed of cells two and three times as thick and as long as the above; and again in others we see small and large spindle-shaped cells separated in different sections as well as lying beside each other. The contours of the fusiform are, for the most part, sharp and characterized as distinct membranes, but we often miss the linear boundary of the cells, especially in the shorter forms.

In the mass proper of the sarcomatous pseudoplasma the *ramifying* or *reticulating* cells are rarer occurrences. On the border of the tumor they are often found; still, we may take for granted that the greater portion is deposited from the stroma of the choroid. That such is the case can be made especially evident in the pigmented stroma cells.

Sarcoma cells are distinguished, in general, by large and sharply-defined nuclei, with nucleoli generally bright and well marked. The contour of the nucleus is a distinct line, which sometimes appears double when seen under the highest magnifying powers. The interior of the nucleus is granulated, often finely and regularly, often also in such a manner that a few coarser granules are found among the finer ones. The *nucleolus* is homogeneous also under the highest magnifying powers. In many cells two easily-recognizable nucleoli, in some even three, are found.

Occasionally we see, in well-isolated and circumscribed cells, two nuclei distinctly separated. This is sometimes

found in the fusiform cells, but oftener in the round ones, and, indeed, the very large cells, as in Fig. 61. *B* c, are more rarely found to contain double nuclei than the smaller and medium-sized ones in the developing or granulating layers, as in Fig. 56. Occasionally we see in a medium-sized cell surrounded by fibrous tissue two nuclei in the same plane, whilst in direct communication with the common cellular contents we find a third nucleus either before or behind the others.

Of another formation are the dark granules or clusters which are found pigmented as well as unpigmented in the cell-like collections of protoplasma, represented in Fig. 44. b, and described on pages 115 and 116, and explained as cells containing blood-corpuscles.

Aside from these well-marked cells, we also find, in sarcoma, still other formed elements, which may be regarded as *fragments* of cells. Among these I classify such *clusters* as I have described above in the interior of circumscribed protoplasma masses, *i. e.*, in cells. They are as large as white blood-corpuscles, but also diminish until they arrive at the average size of the nucleoli or pigment granules of the choroidal epithelium. In their interiors they are homogeneous, or more or less regularly spotted. They are found pigmented as well as unpigmented, and in some parts of the tumor constitute so large a portion of the formed elements embedded in the intercellular substance that it is really difficult to detect regularly developed cells beside them. Such an arrangement has been mentioned and sketched by *John Müller*, the first accurate describer of the microscopical

structure of tumors ("Ueber den feineren Bau und die Formen der krankhaften Geschwülste," Berlin, 1838. Plate I. Figs. 9 *and* 17), and has been regarded as an evidence of the great fragility of the cellular elements in the pseudoplasma.

In the period of decay of a tumor, such fragments of cells are mixed in large quantities with the *products of retrogressive metamorphosis*, of which we will speak hereafter.

2. *The intercellular substance.* It is found in sarcoma in varied conditions similar to those in other tissues; perfectly homogeneous or hyaline, lightly dotted and more or less plainly striped. This can be shown remarkably well on hardened specimens when the embedded cells have fallen out from any cause whatever. It then presents the appearance of an irregular reticulum, with small meshes of fibrous or granulated framework of different thickness (Fig. 62. r). The quantity of intercellular tissue is very variable in different cases, and in the several sections of the same tumor. Sometimes, especially in sarcoma of spindle-shaped cells with parallel arrangement of the elongated elements, the intercellular substance is found so sparingly that it almost seems to be missing. On the other hand, we find it so abundant and dense in other tumors that they assume a fibromatous character. In portions of the tumor of recent development the young cells occasionally are embedded in a basement substance which we must consider as the intercellular substance. Yet the latter can belong to the mother-tissue, as has been observed on the

lateral boundaries of choroidal sarcomata, or may be a new formation produced by the activity of the sarcoma cells (Fig. 61. B and A).

In other places only lymphoid corpuscles and sarcoma nuclei are found in a common hyaline or finely granulated basement substance (Fig. 63), which we are not justified in regarding as intercellular substance, but rather as the confluent contents of the cells, protoplasma, similar to the contents of the multinuclear giant cells (myéloplaques). Only when this basement substance has become arranged like a zone around the several nuclei, does the separation of the real intercellular substance, which at first is hyaline, afterwards granular and fibrous, take place.

3. *The blood-vessels.* In sarcoma, as a rule, they are not peculiar. They are usually wide, thin-walled cylinders, with a network of capillaries whose lumen is generally much larger than is found in physiological tissues. Melanotic sarcomata appear, for the most part, poorer in blood-vessels than the white; the cause of this is, perhaps, that the melanotic are more frequently composed of fusiform cells, and such tumors are generally less vascular than those composed of round cells. The ætiological connection, however, seems to me to be just the reverse. In vascular pseudoplasmata there is an abundant afflux of nutrition, which causes a luxuriant development of cells and also a rapid decay. The fusiform cells, with their well-marked cell-walls, are probably a slower, and consequently also a more durable and tougher formation than the round, especially the small-celled elements.

They are certainly more closely connected to fibrous tissue, which is universally characterized by its poverty in blood-vessels, than the round cells. In pseudoplasmata, if we regard the increased or diminished vascularity of the mother-tissue as decisive for the form and toughness of the newly-formed elements, we must find differences in choroidal tumors according to the place of origin of the pseudoplasma, whether in the outer stroma which is poor in vessels—Haller's and the suprachoroidal layers —or in the internal layers of the vascular chorio-capillaris. Taken by themselves the outer layers of the choroid are sufficiently vascular, notwithstanding that they are traversed principally only by the larger trunks, which, however, are useless for the formation of new cells in the surrounding stroma, for the abundance of nutrition conveyed to any tissue is not dependent on the larger vessels which flow through it (for in that case the mediastinum would be the best-nourished portion of the whole body), but on the amount of capillaries distributed in it. In fact when we examine our cases of choroidal sarcoma, in which the principal point of development could be demonstrated clearly, we find the origin of the denser fusiform varieties in the external layers of the choroid as in cases IX., X., and XI., of which Fig. 36 gives a confirmatory representation, whilst in the softer forms, the pseudoplasma originated in the innermost stroma layers of Haller's vascular layer and in the chorio-capillaris, as we have observed so well marked in Cases XIV. and XV. The greater part of Case XIII., from which Fig. 54, which is also valid for the development of the two following cases,

is taken, belongs also to this class. Yet this case touches on the limit. The deposition of embryonic cells takes place in the innermost stroma layer and the adjacent boundary of the chorio-capillaris. The pigmented stroma cells are already absorbed in the proliferating cell mass, whilst the outer layers of the capillary stratum are yet comparatively for a long while raised by the pseudoplasma as an uninjured cover. Here the vascularity of the mother-tissue is of an intermediate grade, and this is also the case in tumors whose elements become fusiform but remain small and delicate, having generally very much homogeneous intercellular substance (Fig 53), and are interspersed at the base, at the periphery, and also partly in the interior, with roundish cells. The extent of pigmentation also allows us to consider this case, as we shall see hereafter, as a transition between these two forms.

We found in Cases XIV. and XV. a very remarkable disposition of the blood-vessels of the mother-tissue, for we observed that the choroidal vessels from their entrance into the globe to the tumor, *i. e.*, in the posterior portion of the choroid, were in a state of mechanical hyperæmia. As has been more minutely treated of in the description of these cases (p. 120), the tumor compressed both arteries and veins, since both run from the posterior pole of the globe to the equator. Tumors situated on the equator and more anteriorly will be an obstruction to the arterial circulation in the direction of the optic nerve, and to the venous in the direction of the cornea, since the arteries all come from the optic nerve and run

towards the iris; the veins, however, from both sides turning towards the vasa vorticosa, which peforate the globe at the equator. The passive congestion in the anterior veins will never be of such a degree as that in the posterior, because the former have a collateral outlet in the canal of Schlemm. The mechanical relations of the impediment to the choroidal circulation are of a peculiar nature, because the direction of the current in the arteries is also peculiar here, for the blood does not as usual return in the same direction in which it enters. It seems to be worthy of consideration to examine whether in other processes symptoms of a peculiar nature are not also produced by this arrangement.

In the neighborhood of pyæmic infarcta I observed in a previous examination this passive congestion; yet this is a common phenomenon in such cases, and I did not pay particular attention whether the passive congestion occurred only, as in this case, on the side toward the optic nerve.

4 *Pigment.* The pigmentation of choroidal sarcoma is prevalently caused by a deposition of a brown, now and then brownish-black coloring matter in the cells. This is often diffuse, and colors the cell more or less uniformly, or particular spots of the contents more than others. Thus, those cleft contents, of which we have already spoken, occasionally become very distinct. We also find as often, or perhaps more frequently, that the coloring matter exists in *brown granules*, which are similar to those of the pigment cells of the choroid. These granules are embedded in the cell contents, the protoplasma, generally

in such a manner that the zone around the nucleus is most densely infiltrated by them. Occasionally we only see one side of the cell pigmented, or perhaps the entire protoplasma from the nucleus to the periphery uniformly filled with it. The brown coloring matter is autochthonic, that is, a production of the elements of the tumor, and its origin is ascribed by *Virchow* to the metabolical activity of the cell. The cells with larger accumulations of coloring matter (Fig. 44. b) are to be regarded as metamorphoses of cells containing blood-globules. In some cases almost all the cells of the tumor are filled with pigment, and then these appear deep black; generally, however, only a limited number of pigmented cells are imbedded in the unpigmented ones.

We observe that already the youngest cells, whose character is yet undetermined, are pigmented (Fig. 56). The coloring matter then appears diffused in them, under ordinary magnifying powers; however, when the cells increase in size, it is also augmented and constantly becomes more granular. It was impossible for me to determine with certainty whether cells originally white can still become pigmented after they have attained a complete development, since I always found in pigmented sarcomata that the young elements in the formatory layer already contained pigment.

Aside from this autochthonic, brown, granular pigment adherent to the cells, we also find, *in sarcoma, accidental amorphous coloring matter collected in lumps and flakes, which must be regarded as metamorphosed coloring matter of the blood.* It does not generally have a brown ap-

pearance, but in the commencement is reddish and yellowish, later black. It is much less common and in much smaller quantities than that attached to the cells, and is found more frequently in the white, round-celled tumors, on account of their greater vascularity, than in the true melano-sarcomata.

5. *Products of retrogressive metamorphosis.* Among these, we must mention principally *fat*, which, similar to the coloring matter, is heaped up in fine granules in the interior of the cells. At first we find it in small quantities, and scattered in the protoplasma of the cells; then it collects, fills the whole cell either under the form of fatty granular cells developing everywhere, as long as the nucleus displacing and dissolving it, or as heaps of fatty granules, when the whole cell presents the appearance of an agglomeration of fat molecules. The fat granules are also seen scattered in the intercellular substance, and are not seldom met with collected in large clusters.

Aside from the fat we find *débris of cells*, such as irregular granules and fibrous flakes, in decaying portions of the growth, which together, and often mixed with remnants of blood, form a soft diffluent pap, or a thickened cheesy mass. On the surface these parts undergo most varied changes on account of evaporation and admixture of atmospheric particles, processes known as necrotic, sanious and purulent destruction, etc. The fluid and dried products of ulceration I do not find it worth while to treat of in this place.

Calcification, ossification, and amyloid degeneration, I have not noticed in the cases of sarcoma above-described; in

general, they are certainly met with very rarely in choroidal sarcoma, whilst in glioma, the choroid, which is degenerated to connective tissue and atrophied, becomes the favorite location of calcareous incrustations, or, relying upon our own experience, the calcified glioma clusters were found embedded either in the choroidal tissue or in its immediate vicinity.

Mackenzie (Treatise on Diseases of the Eye, 4th ed., p. 731) relates the following remarkable condition in an eye extirpated on account of melanosis: "The sclerotica appeared entire, but greatly atrophied, the natural contents of the eyeball completely destroyed, a pretty thick cup-like *deposit of bone* within the sclerotica at the back part of the eye; the rest of the cavity filled with the melanotic tumor. At one period the optic nerve, on its way to the retina, had passed through a small hole which was found in the ossific deposit."

Aside from this observation, we also find ossification in the interior of eyes degenerated sarcomatously, mentioned in Stellwag's Lehrbuch der Augenheilkunde, III., Aufl. p. 565.

Amyloid bodies, as far as I know, have not yet been observed in choroidal tumors; yet I saw, in a few specimens of the preceding cases, smaller or larger, *round, hyaline bodies* embedded in the sarcomatous tissue. This was very well marked, for instance, in Case XIV., in several places. Since, however, such round hyaline or colloid bodies are as yet rather equivocal occurrences, and since in all places I found them only in small quantity, without effecting any change in the structure of the growth,

I considered them as unimportant, and did not enter into details concerning them; yet, for the sake of completeness, I did not wish to leave them entirely unmentioned.

C. Varieties of Choroidal Sarcoma.

The arrangement of those parts forming the tumor, and the predominance of one over the other, determine the division. This can be accomplished according to different leading principles. If we consider the cells and their forms the most important, we can distinguish round-celled and fusiform-celled sarcoma; and when both kinds of cells are abundantly met with in one tumor, we call it a mixed round and fusiform celled sarcoma. The form of the cells is certainly not totally unimportant for determining the nature of the sarcoma, since in general the fusiform-celled are tougher, firmer, and grow with less rapidity than the round-celled. They also remain a longer time at their place of origin, attack the adjoining tissues more slowly, and lead to a generalization later. However, these assertions are only conditional, for we have seen striking exceptions to them in our own cases. Thus the fusiform-celled sarcoma, Case X. (Heuberger), produced early (after one year) a focus of dissemination at the exterior of the sclerotic, and soon afterward caused death by metastasis to the internal organs, whilst the round-celled sarcoma, Case XII. (Hauert), extended only after seven years' duration beyond the eyeball, and then, it is true, quickly deposited

herds in the vicinity and in different remote parts of the body.

According to the size of the formed elements, we may distinguish small and large celled choroidal sarcoma, and these again have a limited influence on the composition and extension of the pseudoplasma, since, as a rule, the small-celled grow more quickly, and become generalized more rapidly than the large-celled.

The relative quantity of the cells to the intercellular substance furnishes a practical, not unimportant basis for classification, just as it leads anatomically to positive and conspicuous symptoms. If, for instance, the intercellular substance is abundant, it will also generally become fibrous, and the whole growth tough and resistant; usually also grows slowly. Such tumors are analogous to fibromata, as well as regards their *habitus* as their relative benignity. A greater abundance of the cellular elements gives rise to the softer medullary forms, which grow more rapidly and possess a greater local and general contagiousness than the tough fibromatous forms. The multicellular or medullary sarcoma has also on this account ever been regarded as very malignant.

All these different relations, which are applicable not only to choroidal sarcoma, but also to tumors in general, have been especially mentioned and properly estimated by *Virchow* with great acuteness and convincing clearness.

If we examine *the structure* of those cases of sarcoma described by us more closely, we can distinguish four different kinds, which are not only marked anatomically, but may also be diagnosticated as such, according to their

development in the living, or at least may furnish grounds for this differential diagnosis, of which we will speak hereafter.

1. The *melano-sarcoma*, of which Cases VIII. to XII. serve as examples. The appearance of pigment in larger quantities is so striking that this form has been long since regarded as something peculiar. Macroscopically, these tumors appear equally black in all parts, but are often spotted both on the surface and in the interior (Fig. 49). Not seldom the surface as well as the inner mass is traversed by black streaks, which appear directed toward the middle of the eye (Fig. 34), but also have lateral shoots (Fig. 33). The melano-sarcoma is composed, in the majority of cases, of fusiform cells, yet we also find the round-cells prevalently (Case XII.) and even exclusively present.

2. *The white, simple sarcoma.* These cases seem to be scarce. In medical literature there is hardly anything known about them, perhaps because they have been described as medullary carcinoma, or encephaloid. Under this class we might place those rather scarce cases of this soft pseudoplasma which have been noticed in adults. A case, for instance, of *Jonathan Hutchinson*, in the Ophthalmic Hospital Reports, V., p 80, Case III.

A well-characterized example of this kind we found in our Case XIII., which macroscopically presented the picture of a white, soft, fungoid growth, and proved to be a fusiform-celled sarcoma of the choroid.

V. Graefe mentions a totally analogous example (Zur Diagnose des beginnenden intraocularen Krebses. Arch.

f. Opth., IV., 2, pp. 218–229; p. 222 he reports as follows:) "Between the detached retina and choroid there was situated a yellowish serous fluid; the outer surface of the choroid was everywhere in contact with the sclerotic. Embedded in the choroid, and indeed close to the outer border of the optic nerve, there lay a sharp, circumscribed tumor, 17 mm. long, 15 mm. broad, and 9 mm. thick, the inner surface of the same surrounded by the pigmentary and vascular layers of the choroid, *i.e.*, by means of an exudative membrane, grown to the retina. Externally, the tumor is covered by the strongly atrophied layer of outer choroidal vessels, and is easily detached from the sclerotic. Only on one circumscribed spot there appears a slight adhesion. The tumor presents the appearance, on section, of a regular, pretty soft framework, from which no juice can be expressed, and does not show any areolar structure when microscopically examined, but consists throughout of large nucleated cells, mostly drawn out in two directions. *Virchow* pronounced it a sarcoma."

I cannot decide whether these white sarcomata of the choroid, as they develop, can still become pigmented; yet this appears probable. We saw that the pigment contained in choroidal tumors is more abundant when it develops in the outer layers, which normally are richer in coloring matter. If a pseudoplasma originate in the chorio-capillaris, in itself poor in pigment, it may without doubt produce a certain quantity of unpigmented new elements; then, however, it extends further into the neighboring tissues, the pigmented elements of the mother-tis-

sue begin to participate, and in some manner give rise to pigmented pseudoplasmata.

We really saw also in our XIII. Case (Fig. 51), that a slight pigmentation was already commencing on the border, which without doubt was of the same nature as in the preceding cases.

3. *Vascular Sarcoma.* When the vessels predominate in a sarcoma and determine the arrangement of its elements, it is proper to call the tumor a vascular one. If, as is often the case, the vessels are small, resembling capillaries, or being really capillaries in the strictest sense of the word, we may call it a telangiectatic tumor. Case XIV. gives a highly characteristic example of a vascular sarcoma, which we can also call telangiectatic, since a large number of the vessels have the character of capillaries. The structure received a peculiar cylindrical or utricular appearance from the stratiform disposition of cells on the outer surface of the vessels, so that we may call this form vascular, cylindric, or utricular sarcoma (Figs. 60, 62, 66). Such vascular sarcomata have been sometimes mentioned, but have not been examined with sufficient minuteness in regard to their finer structure. Under this class we might also place the case which *J. W. Hulke* describes as medullary cancer of the choroid in his Case VII. (Lond. Ophth. Hosp. Reports, Vol. IV., p. 82).

4. *Inflammatory Sarcoma.* Of this class I have only seen one example, Case XV. The whole picture of the disease materially differed, both clinically and anatomically, from the common one of sarcoma. The inflammatory commencement and progress, probably occasioned

by an injury, induced several collections of pus, one of which affected the sclerotic, distended and threatened to rupture it. I found in the pseudoplasma itself, also, smaller collections of pus, and the structure of the firmer portions of the growth showed so many smaller round cells in a very distinct fibrous mother-tissue that it had the greatest resemblance to granulation tissue. Besides this, there also appeared in such large quantities larger round cells with large nuclei and distinct, brilliant nucleoli, as well as fusiform cells with similar well-marked nuclei; the cellular formations also were in such great quantity proportionately to the intercellular substance, and the whole tumor resembled, macroscopically, so much the button-shaped, pediculated sarcoma (altogether as in Cases XIII. and XIV.), that I can sooner place it in this class than in any other. However, it forms an intermediate stage, and indeed approaches the fibroma. It was very rich in vessels, yet no decisive peculiarity was given by them to the structure of the neoplasma. The youth of the patient, the deviation in structure and the peculiar kind of development, determined me to distinguish this neoplasma from the common sarcoma, and give it an independent classification.

Future observations must show in how far I was justified in so doing. It is self-evident that I do not, under the head of inflammatory sarcoma, understand such cases in which, to a primarily pure sarcoma, glaucomatous inflammatory symptoms supervene during its growth. The inflammation itself must be the ætiological point of origin of the formation of the tumor.

Cystic Spaces. I find mentioned in a case described (unfortunately too unsatisfactorily) by *G. Cowell* (Ophthal. Hosp. Reports, V., p. 189). The cut surfaces of the tumor, which was the size of a hazel-nut, showed several cysts of different sizes, which were filled with a transparent substance. This description is too short to justify us in considering cysto-sarcoma as a class among the tumors appearing in the interior of the eye.

D. Origin and Development of Choroidal Sarcoma.

We found in the preceding case examples of both types of development of morbid tumors—that of the *embryonic new formation, and of the physiological growth.* In the embryonic type of development, we saw arise, principally on the boundary of the mother-tissue and on the periphery of the tumor, abundant quantities of small round cells, with large nuclei and narrow protoplasma mantles, sometimes difficult to make visible, which gradually were changed into the peculiar sarcoma cells. As a typical example we have found Case XIII. (see Figs. 54 and 55). But also in the interior of the tumors such young elements are not seldom found, with as yet indifferent characters (granulation, formation, or embryonic cells), especially in the neighborhood of smaller and larger blood-vessels. It is not my task to discuss their origin here. They may come from the blood, and be nothing but the white blood-corpuscles which have passed through the capillary walls, or they may originate in the lymphatic system or in the connective tissues,

both of which, if not identical, are at least very closely related; true it is, that these elements are principally to be regarded as the first products of the former pathological pseudoplasma. In our cases they appeared as easily-demonstrable links between the adjoining mother-tissue and the developed pseudoplasma.

In other cases we saw the tumor arise immediately from the posterior choroidal layers without those links of granulation cells, whilst the existing fusiform and caudate cells received an immediate increase, which culminated in the tumor (Fig. 36). The mode of cell-multiplication has been often enough demonstrated, and it did not prove difficult to find it in the cases under consideration (Fig. 42, and others). However, the question, how important and effective this local multiplication of cells is, is not at all decided at the present day. This much is certain, that in some tumors this kind of cell with double nucleus is a rare occurrence, which must be sought for. In others, however, pr. ex., Case XV., they are throughout frequent, and we must indeed choose for observation principally those portions of the growth where smaller elements still lie—not the tough, developed, or already retrogressive parts of the tumor.

The peripheral portions of the intumescence, where this arises immediately out of the mother-tissue, which I have often demonstrated and denominated as a type of pure hyperplastic growth, do not appear to me entirely suitable for illustration, since then the development of the new elements may already be complete; therefore the observation of the original forms of the same is withheld

from us. We must examine the whole tumor, and if all its parts show a similar structure of the elements, we are then justified in assuming a growth through simple hyperplasy, according to the accepted mode of cell-multiplication. This, now, I did not in the foregoing examination find to be general, but as a rule, beside such places with simple hyperplasia, other spots with granulation cells came to view. Although these latter have increased in importance through the investigations during the last year on pseudoplasma, nevertheless I cannot allow this rule to remain valid: that all newly-formed elements of a tumor have migrated to it from a distance; for in many places I have seen cells isolated and in fine fibrous tissue with several nuclei; also in other places next to such cells I have found small rows and clusters of young cells, which must have had the same origin, since no vessels lay in the same neighborhood. I believe I am secure from error, since I employed for these observations the finest sections and a good immersion system. Even if I admit that the first cell of such a small herd had wandered thither from the blood (the migration may have proceeded just as well from the nearest cell cluster), it would be absurd to concede that a heap of cells should always have taken the same way for migrating, and that the cells on their passage should have passed through different phases of development, according to the duration of their stay. It is easier to assume that a cell capable of developing had reached this spot, and had then and there brought forth the brood. But in the soft portions of the tumor itself we

find totally the same pictures, and they have forced me to believe in the reality of the multiplication of the elements proper of the tumor. This increase of the elements proper would still fall within the range of physiological growth. We have, therefore, both types of development well marked:—

1. *Originating from embryonic cells which have migrated from the blood or lymph-vessels to the place of origin of the tumor; and*

2. *Through multiplication of the cells of the mother-tissue and the elements proper of the tumor, in the manner of the endogenous formation of nuclei and cells.*

The growth of the yolk is the well-known physiological model of the latter, and also the immigrated formative cells must somewhere have once been formed according to the same type. The difference of origin of the new elements of the tumor is only this,—that the one originated inside the tumor or the mother-tissue, the other far from it. Their further growth carries them to the fully developed characteristic elements of the pseudoplasma, and shows them their places in the arrangement of the tissue peculiar to it.

If we investigate the more immediate conditions under which once a round-celled, then a spindle-celled sarcoma, or now a melanotic, then an unpigmented growth, poor or rich in vessels, is formed in the choroid, I am able only to give a few hints concerning them.

We find ourselves, in pursuing these investigations, soon indulging too much in the imaginary, and in our conclusions we too easily come back to the point from

which we started. I have already remarked that the fusiform-celled sarcomata are more compact and more durable, and that they grow more slowly, and generally have fewer vessels than the round-celled sarcomata, and also I believe that the first-mentioned qualities are dependent on the lesser afflux of nutrition occasioned by the scanty vascularization; but I do not know why one should be less, another more vascular. Perhaps the age of the patient has some connection with it, for we find the less vascular forms more frequent among older people. Processes of involution I remarked very frequently and distinctly in the blood-vessels of more aged people, and these may, under the same ætiological influences (irritations), allow the formation of new vessels less easily than in youthful individuals.

In accordance with this is the fact, that we observe in old age generally more frequently hard scirrhous neoplasmas—in youth more cases of the softer medullary forms. A striking illustration of this is the always very vascular encephaloid of the eye.

The presence of pigment I have brought in connection with the place of origin, whose influence I have always been able to demonstrate. The existing coloring matter predisposes in such a manner to the pigmentation of the new elements, that we see melanotic tumors appearing primarily only in such places where pigment had already existed: in the choroid, episclera, lamina cribrosa, pia mater, and the integument. That the secondary clusters in the adjoining tissue and in the distant organs imitate, more or less,—not only in regard to pigmenta-

tion, but also as regards the important qualities,—the type of the primary tumor, is a known fact which is especially adapted to allow the infection of the tumor to take its origin in the local processes, instead of considering that an already existing dyscrasy of the general humors of the body precedes the primary tumor. When we see, for instance, that melanotic tumors with marked infectious qualities only develop primarily in physiologically pigmented organs, it would be absurd to suppose that an original degeneration of the coloring matter of the blood should select only the already pigmented organs as the seat of the foreign deposit.

Concerning the development of inflammatory sarcoma, I beg permission to say a few words. That circumscribed inflammations can cause the commencement of benign tumors is known, and first in the pathology of the eye we find a frequent typical illustration. The inflammation of the glands of the eyelids generally leads to suppuration, hordeolum Zeisianum, and Meibomianum. In cases of slower development we see, however, newly-formed (granulation) tissue growing into durable elements, and producing fibromatous tumors (chalazia and polypous excrescences), which can gradually augment to really considerable and persistent lumps. Further, it cannot be denied that injuries have occasionally caused sarcoma and carcinoma in different portions of the body. These then have always had an inflammatory primary stage. Thus, it can happen that circumscribed choroidal inflammations produce, besides different hyperplastic forms, also the sarcomatous new formations. It is true

that the fibromatous vegetations which approach near to the normal tissues are more common. Yet out of this and besides it, the sarcoma also, the next intermediate form of the cellular tumors, can be developed. Our Case XV. I should like to designate as such an intermediate form,—a fibromatous sarcoma.

J. W. Hulke mentions (Ophthalm. Hosp. Reports, V., pp. 181–184) a case of melanotic fusiform-celled sarcoma, very remarkable as regards its development. A man, 68 years of age, remarked during the last ten years a diminution of his power of sight. It was called amaurosis. The eye, two or three years later, had been repeatedly red and painful, and then slowly shrunk. Later he wore an artificial eye. The manufacturer remarked to him at the time of purchase that his eye was strongly ecchymosed. Soon it began to swell, and out of it and the orbit there vegetated a cancerous growth, which, after extirpation, proved to be a melanotic sarcoma. I do not presume to decide whether the tumor was the cause of the beginning of the failure of sight. At any rate, the subsequent atrophy of the eyeball is remarkable. However, this assumption is more probable than that a melano-sarcoma should arise subsequently in the eye, which had become phthisical through irido-choroiditis; for the primary diminution in the power of vision was unaccompanied by symptoms of irritation for two or three years. I am most disposed to believe that the first stage of development of the tumor interfered with the power of sight through detachment of retina, &c., &c., and led to irido-choroiditis with tem-

porary atrophy of the globe, until the tumor, subsequently growing more rapidly, continued to develop as usual.

E. Seat and extension of Choroidal Sarcoma.

Sarcoma is met with more frequently in the choroid proper; whether oftener in the posterior or anterior section, I do not presume to say. *The ciliary body seems also not unfrequently to be the point of development* (Case IX.). Two cases of *V. Graefe* (Arch. f. Ophthalm., XI., 2, pp. 233–237) belong to this class. In the first case, that of a girl of twenty years, a firm fusiform-celled sarcoma, with a tendency to melanosis, developed itself in the anterior section of the ciliary body, spread on the neighboring iris, became visible on its periphery in the anterior chamber, whilst it seemed to crowd the same from its ciliary insertion, and did not extend posteriorly beyond the boundary of the ciliary ligament.

The second case, a woman forty-three years of age, began in a similar manner. The operation was postponed for a long while (and only performed after the tumor had filled about one-half of the globe). Virchow, in his examination, found in the subretinal portion of the tumor masses of cells with glandular arrangement, with advanced fatty degeneration, and intermingled with brown and black pigment. In the sclerotic portion, less alveolar, more sarcomatous arrangement. To this short description the diagnosis of sarcoma carcinomatosum melanodes is added.

Further, a case of *G. Cowell's* (Ophthalm. Hosp.

Reports, V., pp. 188–190) belongs here, in which a slight melanotic sarcoma had its essential seat in the ciliary body, and continued as a small tumor in the peripheral portion of the iris.

Another case is reported by *Warren Tay* (Ophth. Hosp. Reports, V., p. 230), in which the tumor spread further into the anterior chamber, came in contact with the cornea, and obstructed the pupil.

I cannot remember any case of primary sarcoma of the iris. Stellwag (Lehrbuch der Augenheilkunde, III. Aufl., p. 562) shows a picture of a white, soft tumor, which had proceeded from the ciliary body and peripheral portion of the iris, and had ruptured the cornea. The case, which he quoted from Dixon, I have looked up in the original report (Medical Times, 1863, May 16, p. 507), and find, in short, the following: A healthy boy, 12 years of age; slight circumcorneal redness of the right eye; slight pain. The anterior chamber nearly entirely filled with a bossy, yellowish-red mass with blood-vessels, as is seen in the exudation of severe syphilitic iritis; five-sixths of the iris was occupied by the intumescence. The affection began three months earlier; the deposit increased slowly until it filled nearly the entire anterior chamber. Then suddenly considerable congestion of the eye set in, the cornea became cloudy, the neighboring sclerotic bulging as if the growth were about perforating it. The neighboring portion of the cornea appeared infiltrated and softened. *Dixon* extirpated the eyeball. The tumor seemed to have been developed from the outer layers of the ciliary body, had extended from this point to the

iris, and had perforated the sclerotic, so that it appeared covered only by conjunctiva. "Microscopically examined, the whole mass showed fibres mingled with *compound* cells in different stages of development."

Dixon describes this case as encephaloid. *Stellwag* places it under sarcoma, and adds that in such cases we might also think of granuloma. The observation of *Dixon* is decisive neither for glioma nor for sarcoma. It was an inflammatory tumor, which (as a granulation neoplasma) could have advanced either toward decay or to a further development as fibroma or sarcoma. More precise investigations and the progress of the affection can alone decide.

Of the several layers of the choroid, we saw as well the outer (suprachoroidea and Haller's vascular layer), as also the inner layer of connective tissue (chorio-capillaris) furnish the first place of development for this neoplasma. I am not aware that sarcoma can also arise primarily in the optic nerve. Only in the first period the choroidal layer which was first attacked remains the seat of the proliferation; very soon, however, the neighboring stroma layers become implicated in the vegetative process. First a button-shaped prominence arises, which remains covered for a long time by the inner choroidal layers, the hyaline membrane, and pigmentary epithelium. If the outer layers form the place of origin, the chorio-capillaris for a long time still covers the foreign growth.

Before the hyaline membrane and epithelium are perforated, neighboring clusters often will appear, which

through the ciliary body reach the iris, and come to view at its periphery in the anterior chamber (Case IX., Figs. 26, 27, and 28). The pseudoplasma develops itself also in the ciliary body,—first in the connective tissue-like stroma of the ciliary processes, and then from all sides attacks the ciliary muscle, until its elements are entirely replaced by sarcomatous tissue (Figs. 32 and 37).

The basement membrane of the choroid and the pigmentary epithelial layer become perforated and destroyed in the further development of the tumor. The retina clothes the tumor from the commencement, and is generally loosely adherent to it, whilst in its other divisions it is generally detached at an early stage (Figs. 28, 33, 40, and 50). It is rarer that it, like the pigmentary epithelial layer, is perforated and covered by the tumor (Case XIV., Figs. 58 and 60). This grows *button-shaped* into the vitreous space, inasmuch as it becomes constricted near its base, whereby the whole growth tends to assume the form of a mushroom or sponge, from which its old name, fungus, is derived. Between the detached retina and the healthy portion of the choroid, atrophying or degenerating to connective tissue, but not attacked by the pseudoplasma, there collects a sero-albuminous and frequently also bloody fluid (*Dor's* Case, Arch. of Ophthal., Vol. VI., 2, p. 244, and others). Both can be explained by the mechanical congestion in that section of the choroid lying between the tumor and the optic nerve, as we have especially demonstrated in Case XIV. (Figs. 59, ge, *and* 60, ch). The more the tumor encroaches upon the vitreous space the

more will the iris and the lens be pushed forward, and at last pressed on the cornea. In the mean time, symptoms of increased intra-ocular pressure and glaucomatous inflammation arise; the eyeball becomes enlarged, and at last is perforated in some place or other, whereupon the pseudoplasma vegetates in the orbital cellular tissue under the conjunctiva. For the most part, however, episcleral and orbital secondary clusters are already present before the appearance of glaucomatous inflammatory symptoms. The sarcoma becomes intimately connected with the inner layers of the sclerotic; at first pushes itself in most minutely (Figs. 38 and 39), and afterwards in distinguishably tortuous passages through the sclerotic, forms small round accumulations, which soon after spread to the fatty tissue of the orbit (Fig. 41, ex). The perforated globe becomes compressed by these vegetating masses, alters its form, and often is crowded so much aside that in the orbit it conceals itself under the lids. These themselves become disturbed, traversed by tortuous, bluish vessels, and their closure is usually prevented by the lobular masses of the tumor, projecting out of the incisura palpebrarum. At length the conjunctiva becomes ruptured, and a free ulcerating surface, with its excretory products, comes to view. This ulceration sets in much earlier when the perforation takes place through the cornea.

All the coats of the globe become destroyed. The sclerotic, which can be distinguished even in the largest tumors, offers the strongest resistance. However, the pseudoplasma encroaches upon the optic nerve early, and

spreads along it. In the same manner all the tissues of the orbit are attacked by and by, whereupon the devastating growth invades the soft and bony parts of the face, and causes the most dreadful ravages.

Generally, however, this does not reach such a high stage as we are accustomed to see in carcinoma, and especially cancroid of the outer portion of the eye, because death puts an end to its progress sooner by transitions into the cranium, and metastases to the important parenchymatous organs. Among the *metastases*, those of the liver are noticed as the first, the most common, and reaching the highest grade of development. In its tissue numerous isolated deposits take place, which later become confluent, softened, form cavities, and cause an enormous hypertrophy of the organ (Case XII.). The consequences are hydrops, ascites, and anasarca. Aside from this, metastatic sarcoma clusters develop in the lungs, the pleura, the peritoneum, the kidneys, the spleen, the stomach, the brain, etc., which, however, seldom attain any great dimension, for usually the disturbance in the liver kills the patient under symptoms of the cancerous cachexia and dropsy (Cases IX., XI., and XIII.). The minute structure of the metastases in the liver, lungs, and brain is described in Case XII., p. 122, etc.

II. Clinical Description of Choroidal Sarcoma.

A. Symptoms and Progress of Choroidal Sarcoma.

The symptoms of the affection, whose anatomical basis we have treated of in detail in the foregoing descriptions,

can be divided conformably to their order of succession into four stages:

1st Stage. *The origin of the primary choroidal pseudoplasmic clusters and their commencing growth without demonstrable symptoms of irritation in the eye.*

The functional disturbances are generally unnoticed by the patient in the commencing stage of the development. Only in case the region of the yellow spot should become the origin of a choroidal tumor would the disturbance of sight be observed immediately, and these would consist in symptoms of retinal irritation, amblyopia, metamorphopsia and hyperopia, for the function of the columnar layer is dependent as much on the integrity of the choroid as on that of the retina. We even notice in unimportant congestive and inflammatory changes of that portion of the choroid behind the macula lutea, that the acuteness of vision is altogether disproportionately diminished. The occurrence of metamorphopsia and hyperopia is, however, a necessary consequence of the change of position of the retina. The first things concerning which the patients complain, are defects in the field and the diminution of the power of vision. They observe when they accidentally close the other eye that a curtain covers a portion of their visual field. Frequently, however, this passes unnoticed, and the patients complain of a diminution of sight, and if we examine the same we find, besides this, that a portion of the field of vision is missing (Case XIV.). Both symptoms generally increase proportionately. The more the field of vision becomes curtailed,

the more the power of vision sinks, and at last results in total blindness. Sometimes this happens suddenly, on account of rapidly occurring detachment of the retina. Now and then it has also happened that the blindness approaching without irritation is only discovered by the patient when it is complete.

Seldom is the opportunity afforded to the physician to make a physical examination in the first stage of the malady, before detachment of the retina has supervened. This was possible in Case XIV. In the depths of the fundus, a globular prominence was noticed, whose position, anterior to the posterior focal surface of the eye, could be determined from the refractive power of the strongest positive auxiliary glass, in the examination of the upright image, with which we could still distinctly see the apex of the tumor. We also get a distinct stereoscopic image of the nodular prominence with the binocular ophthalmoscope. The retina covering this can be clearly recognized as such by the peculiar ramification of its vessels, and if the case in question is a vascular sarcoma, we see under the retina a second irregular system of vessels which no longer belongs to the retina, but must lie on the surface of the tumor, as *Bowman* has observed in one case (reported by J. W. Hulke in Ophthalmic Hosp. Reports, London, IV. Vol., p. 82): "A deep-seated bright reflection was noticed, and, when the pupil had been well dilated, this was found to proceed from a solid-looking, rounded tumor which projected from the fundus directly forward into the vitreous humor, and at the inner side nearly reached

the back of the lens. Upon inspection under oblique illumination two sets of vessels were distinguished upon its surface, one set slender and arborescent, belonging to the retina, wound round the border of the more prominent nodule, and were lost to view; the other consisting of larger vessels emerging at several points of the surface of the tumor, behind the retinal vessels, without any regular plan of arrangement."

If the tumor lies upon the retina, as we have seen in Case XIV., we observe only on its surface the irregularly ramifying vessels which belong to it, besides hemorrhagic spots. We can also, then, at the same time, distinguish the color and quality of the surface with the ophthalmoscope or by reflected light, whether white, spotted, or gray and black, and can employ this to determine the nature of the tumor. If the vitreous humor is sufficiently transparent we must be able to observe the fundus of the eye and its details, and must see it stop at the border of the tumor. The fundus of the eye is not seldom darkened in different degrees by hemorrhages and their consequences (Case XIV.).

Should the retina become detached and the fluid in the vitreous space opaque at the same time, tumors situated at the posterior part of the globe will be mostly hidden from our view. If the eye be completely blinded, intense illumination with direct sunlight, which can be allowed to fall through a small opening in a darkened chamber, and by means of an ophthalmoscope or a convex lens thrown into the eye (whereby, of course, you do not forget the warmth of the concentrated rays of the sun), will

occasionally show the outline of the tumor. If it be situated in the anterior portions of the choroid it will not be difficult to distinguish it, even through the detached retina (Case X.). Still easier is it, when the same proceeds from the ciliary body (Case IX.), where only the membrana limitans of the retina, aside from frequent simultaneously existing vitreous and crystalline opacities, covers it, and if it has spread altogether into the iris we can see it with the naked eye appearing as a round projection in the anterior chamber (Case VIII.).

Since microscopic passages of the pseudoplasma through the sclerotic and secondary nodes on the surface of the same have been seen, even in the first stage free from irritation (Cases IX. and X.), therefore we must never omit to examine the sclerotic minutely, and to pay attention whether there is any exophthalmos or any hindrance in the movements of the eye.

2d Stage. *Appearance of inflammatory symptoms in the eyeball under the picture of glaucoma.*

These consist in *injection of the episcleral and conjunctival vessels, increased intraocular pressure, and ciliary neurosis, etc.*

The injection manifests itself usually in the appearance of thick, tortuous and dilated coarser vessels on the sclerotic in a manner similar to what we observe in glaucoma. The cause thereof may be in the obstruction to the return of the posterior venous blood through the vasa vorticosa. If the sclerotic participates in a greater degree in the process by softening or distension of its tissues, we will find the injection surrounding these places

to be greater. However, it is not a rare occurrence to observe a deep rose-colored red around the margin of the cornea which belongs to inflammations of the anterior portion of the choroid, and even injection and swelling of the sclerotic.

Ciliary neurosis manifests itself in a feeling of tension and weight of the eyeball, in various violent pains in the eye and its surroundings, forehead, temple, and cheek; sometimes radiating on the whole head. The pains sometimes are insignificant, but at others very severe; may come periodically or are constant. Their course seems to lie less in the specific nature of the pseudoplasma than in the intraocular tension, since we see them occur with altogether the same variations in pure glaucoma, according to the severity of the affection, especially the increase of tension.

The increase of the ocular pressure takes place gradually, as a rule; yet there are cases known where it has appeared suddenly and diminished and disappeared with the inflammatory symptoms, in order, after a time, to return in new attacks. *Jonathan Hutchinson* has but shortly made known two cases (Ophthalm. Hosp. Reports, V., pp. 88–93), in which diminution of sight and detachment of the retina had existed without pain and without irritation for one year, when suddenly the symptoms of a totally acute glaucoma appeared. The degree of the increase of tension is liable to all possible variations.

Aside from the above-mentioned symptoms we further notice in this period, a *dilatation and rigidity of the pupil which resembles altogether the glaucomatous pupil.*

Discolored swelling of the iris. The tissue of the iris receives, through admixture of œdema, increased vascularity and probably also more numerous presence of lymphoid cells or the same, a swollen and muddy appearance.

Pushing of the iris and lens against the cornea. Diffuse opacity of the aqueous humor, and diminution of sensibility, with or without corneal opacities. All these are symptoms, which the intra-ocular tumors have in common with glaucoma, and therefore we call this stage characterized by the *appearance of glaucomatous symptoms.*

3d Stage. *Extension of the pseudoplasma to the surroundings of the eyeball.*

Small episcleral clusters arising from the microscopical passages through the sclerotic are occasionally found in both first stages, consequently are not clinically to be ascribed to separate periods. The affection assumes in this third stage entirely another appearance. The eyeball is perforated in some point, either of the cornea or the sclerotic; its contents are partially discharged, and thus the corneo-scleral capsule becomes shrunken and wrinkled, the pseudoplasma spreads in the orbital cavity, pushes the eyeball forwards, and usually to one side, so that we must seek it often under the lids; these are tightly drawn, reddened, and swollen; through their opening there crowds the bossy pseudoplasma, which in the beginning is still covered with conjunctiva, as a usually reddish or bluish-grayish, black-spotted tumor, variable according to the changeable quantity of colorless and pigmented elements and blood-vessels. Then

the conjunctiva ruptures, and an ulcerating surface forms, which excretes a juice, separates necrotic and softened parts; then swelling very badly, bleeds occasionally; then covers itself with dry crusts in layers, which are again separated, and thus allow the decayed masses under them to appear. In the meanwhile the pseudoplasma is constantly extending further, and destroys the adjoining integument, the bones of the orbit, crowds the nose to one side, destroys it more or less, and presents as a decaying growth of variable size, and vegetating more or less, a most frightful aspect.

Through the fissura orbitalis superior, and with the degenerated optic nerve through the foramen opticum, it passes into the cranial cavity, seizes upon the chiasma, and spreads over the base of the cranium. The cerebral disturbances produced by it are often very insignificant, when we consider the extent of the intracranial deposits.

In Case XII. we saw the chiasma of the optic nerve almost entirely impregnated by the melano-sarcoma, although only a short time before the power of vision of the other eye had not suffered to any great extent. That this, however, becomes entirely destroyed as the evil progresses, is shown by the striking case reported by *Landsberg* (Arch. of Ophthalm. XI., 1. p. 58–68).

4th Stage. *Generalization by metastasis to remote organs.*

As a rule, these appear only after the neighborhood of the eyeball has been more or less attacked. Occasionally (Case VIII.) they appear in the second stage of the affection, so that a thorough extirpation removes the

local germs, but does not prevent the further development of the metastases. Among them we almost always find the liver suffering in the highest degree, and the earliest. Œdema of the legs, ascites, swelling in the epigastric region, in which the rough and enlarged liver can be distinctly felt, are the symptoms of sarcomatous metastasis to the liver. Then cough, with occasionally bloody expectoration, and dyspnœa appear as signs of deposit in the lungs. They can seldom be proven by percussion. If the stomach is also attacked (Case VIII.), disturbances in digestion arise; loss of appetite; disgust at the sight of food; vomiting of food, of shiny and chocolate-like masses, from which alone we are not able to determine the existence of melanotic pseudoplasma, since similar masses are vomited in hemorrhages. The clusters in the pleura, the peritoneum, the spleen, the kidneys, etc., etc., with the exception of the last mentioned, produce no prominent symptoms. The patient becomes emaciated, with yellowish discoloration of skin, and at last succumbs to the continued sinking of the vital powers.

The duration of the several stages and of the whole disease is extremely variable. In the 12th Case the patient had observed the decrease in his power of vision, almost leading to total blindness, seven years before the appearance of inflammatory symptoms. In other cases this was noticed only for months. However, it appears that in the beginning, the development of choroidal sarcoma is generally slow, and that the first stage usually extends over a number of years.

In the soft vascular forms (Cases XII., XV.), the growth is a more rapid one, and the first stage usually lasts only from three to twelve months. After glaucomatous symptoms have set in, the patient usually succumbs within the first year (Cases VIII., XII.). Still, cases occur in which the second stage lasts for years. V. Graefe relates such an instance of extraordinary slow progress (Arch. f. Ophthal. X., 1. p. 179), in which the first stage, free from irritation, of a melanotic tumor of the choroid, lasted *seven years;* then the increase of tension, with symptoms of irritation in the eye, was observed for *six years*, and the interior of the enucleated eye did not prove to be entirely filled by the pseudoplasma. The duration of life cannot be considered to be extended for more than one to two years, when the surroundings of the eyeball are once attacked, and if metastases are demonstrable, the fatal issue is to be looked for within the next few months. In general the duration seems to be between two and four years, and only seldom does it continue for a longer period (Case XII., V. Graefe's case, quoted above).

The several stages seem to have a progressively shorter duration, so that the first is the longest, and the last the shortest.

B. Diagnosis of Choroidal Sarcoma.

It is easy, without doubt, to diagnosticate the affection in the third stage, when tumors are immovably situated on the eyeball and move with it. They can be dis-

tinguished from *episcleral* sarcomata and other tumors, especially carcinoma, inasmuch as the interior of the eye is unaffected in the latter forms. If, however, this is not the case, if the fundus of the eye is concealed by detachment of the retina, or if perhaps the eyeball is already misshapen, enlarged, or shrunken, the tumor is most likely a secondary cluster, and if the history of the case be taken, no doubt can remain. When an extra-ocular tumor attacks and changes the eyeball itself in its growth, it certainly always comes to view at a time at which the eye and the power of vision are still intact, whilst, if the reverse be the case, the patient becomes blind before the tumor appears in the eye.

The deeper-seated orbital tumors also, and those of the optic nerve, betray themselves beforehand, inasmuch as they crowd the eyeball forward, and not seldom produce the symptoms of neuro-retinitis in the ophthalmoscopic examinations, which, especially in tumors of the optic nerve, never should fail.

In the second stage the diagnosis of a choroidal tumor is already more difficult, but still for the most part can also be made with certainty. To *V. Graefe* (Zur Diagnose des beginnenden intraocularen Krebses, Arch. f. Ophth. IV. 2, p. 218) belongs the honor of having, in 1858, already called particular attention to the fact that a tumor is to be assumed when, simultaneously with detachment of the retina, an increased intraocular pressure and ciliary neurosis appear.

Later (Arch. f. Ophthalm. XI. 2, p. 237), he affirmed that exceptionally sometimes the formation of a tumor

could for a while produce a diminution in the tension of the eye, namely, when being still small, it excited inner plastic inflammations ushering in phthisis bulbi. The example mentioned there I will quote in this place on account of its importance: "A man was attacked with severe pains in the smaller left eye. Nothing could be found in the history of the case, except that after a disturbance of sight, which had preceded by several months, severe inflammatory attacks had occurred during the last half-year and brought on the present condition. The examination showed a moderately atrophied eye, strongly flattened in the anterior half, cataracta accreta, great pain on touch. From this I could diagnosticate nothing but choroiditis, probably following a previous detachment of the retina, perhaps following cysticercus. On opening the enucleated eye, we found a melanotic choroidal sarcoma, which filled about one-half of the globe, and shrunken products of connective choroiditis."

If other glaucomatous symptoms join the increased intra-ocular pressure in an existing detachment of the retina; pushing forward of the iris, vascularization of the sclerotic, enlargement of the eyeball, and the like, the diagnosis is less doubtful. Then it can only lie between two things: Tumor or glaucoma, and in truth, within the last ten years, the two have been confounded often enough. It is true, in glaucoma we have no detachment of the retina, but as well in the pure glaucomatous inflammation as in that brought on by tumors, the papillary field can be so cloudy that we

cannot distinguish the ocular fundus; therefore we cannot determine the presence or absence of a detachment of the retina. However, the history of the case will often give us a clue.

If the disease appeared suddenly, and if the field of vision is not diminished, then we have no tumor before us. Has the patient, however, observed a dimness of the visual field from one side, then this can be occasioned as well by a tumor, as also by chronic glaucoma, embolia of a retinal vessel or of a ciliary artery, hemorrhages of retinal or choroidal vessels, cysticercus, or detachment of the retina. All these conditions can be diagnosticated by the ophthalmoscope, the examination of the function, and taking the history of the case. If one of them existed previously, and if glaucomatous symptoms supervened, then in case of detachment of the retina, it can only be a tumor, whilst in the other cases it can only be pure glaucoma.

Unfortunately, some patients are such poor observers of their own condition that they only give us, concerning the former state of their complaint, the information that their sight became dimmed more or less rapidly. If such a patient should present himself with increased tension of his blinded and darkened eye, it is often impossible to determine whether we are examining a tumor or a glaucomatous irido-choroiditis. Generally iridectomy must then be performed to alleviate the pain. This proceeding often causes the refracting media again to become clear, inasmuch as it improves the glaucomatous inflammation for a short time. We are then

occasionally enabled to diagnosticate the detachment of the retina, and through this the tumor, as V. Graefe has done in one case. Often, however, this is not even then the case, and after a shorter or longer period the tumor enters as such into the anterior chamber, or after perforation of the capsule of the eye, comes unmistakably to view. Such cases induced even Mr. Critchett to advance the untenable hypothesis, that the glaucomatous process could cause the formation of tumors.

Since it is very difficult to distinguish both the abovementioned conditions from each other, and in some cases it is impossible even with the diagnostic auxiliaries we now possess, I can only advise to use these auxiliaries very carefully, and to examine as often and as exactly as possible, in order to reduce those cases where the diagnosis is impossible to the smallest number. In case the usual means of illumination are not sufficient, we might with advantage employ direct sunlight. It is possible that, with its assistance, we might diagnosticate either through the pupil or the sclerotic, a darker portion as a tumor, which would otherwise have remained concealed.

B. Travers (on the local diseases termed malignant, Med. Chir. Transactions, XV. Vol., I. Part, p. 239) recommended in doubtful cases of tumor, and in deep-seated disorganizing inflammations of the eyeball, an exploratory incision in the same. In malignant tumors, the globe will continue solid, and from the incision a little blood or black pigment will be poured out; but if a discolored fluid should be emptied and the eyeball collapses, the affection is not malignant. In this case,

for the purpose of completing the cure, he makes a deep transverse cut from the outer to the inner canthus through the eyeball, in order to empty its whole contents and cause it to collapse.

The differential diagnosis of choroidal tumors is most difficult in the first stage. It might be confounded with simple, serous, and hemorrhagic detachment of the retina, cysticercus, retinal tumors, detachment of the choroid from the sclerotic, and detachment of the hyaloid membrane from the retina.

Differential Diagnosis between Choroidal Tumors and Hemorrhagic Detachments of the Retina.

Von Graefe says (Arch. f. Ophthalm. XI., 2, p. 238): "As regards the first development of sarcoma of the choroid, I have arrived at the conviction gradually more and more, that the early appearance of serous inflammations of the retina forms the rule. Therefore, with the exception of tumors in the region of the ciliary body, it will hardly be possible ophthalmoscopically to diagnosticate the first commencement of a choroidal sarcoma; we will rather, in the beginning of the malady, have a simple detachment of the retina before us, may perhaps have some remote suspicion from the absence of the causes commonly occasioning the same (scleral staphyloma, affection of the vitreous, inflammatory processes, hemorrhagic extravasations, scleral cicatrices), but to diagnosticate with certainty in this stage, can hardly be thought of. Only when by increasing growth

the sub-retinal fluid becomes more and more displaced, and the mass of the tumor again approaches the retina, suspicious rigid lumps, occasionally pigmented, come to view, from whose appearance beside the flabby retinal sections the above-mentioned supposition arises, the probability of which increases the more when with the advancement of every lump the intraocular pressure progressively increases.

It is not possible to express more clearly and precisely the observations, until now so hopeless, both for the diagnosis and treatment (for in this stage life may yet be saved). Our aim must in future be to make the tumor visible through the detached retina, and for this purpose I have already repeatedly recommended the employment of the direct rays of the sun in a darkened room. Further, a more careful analysis of the cases must be instituted, in order to discover whether it is true that in the earlier stages of sarcoma we have as a rule detachment of the retina. We found it missing in Case VIII., where, indeed, already large clusters existed in all the divisions of the choroid (see Fig. 28, and page 90). The retina was also lying on the choroid in Case XIV.; the value of this I will explain shortly. Cases XI. and XII. came under observation at a later stage. In Cases IX., X., and XIII. detachment of the retina existed, but in two of these cases the tumor was visible through the same, as was remarked in the cases of *V. Graefe* and *Bowman-Hulke*, above described. Thus, of five of the cases under consideration, the retina was in its normal position in two, and only in one, Walter's, the detachment was an

obstacle to the diagnosis of the tumor. Although the number of these cases is small when compared with the great experience of *V. Graefe*, it still shows that in very many cases we are enabled to make an early diagnosis of choroidal sarcoma. But just as it was possible, in the anterior sarcoma, covered by the retina, to recognize under the retinal net of blood-vessels still another irregular set of black streaks and lumps, we may also be able to make use of such occurrences in tumors situated more posteriorly. We cannot mistake the tumor for the first stage of cysticercus, since we recognize this by the shape of the cyst, the movements and peculiar form of the parasite. In later stages, when the latter is dead, and the detachment of the retina and the haziness of the refracting media have augmented, the diminution, which for the most part has set in, of the tension of the eyeball will guard us against error. Of the difference between retinal glioma and other affections which we are liable to mistake for it, I have spoken in the description of the differential diagnosis of glioma. I must here speak more explicitly of one case of *V. Graefe's* (Arch. of Ophthalm., XII. 2, p. 239–242), which was considered as a glioma or gliosarcoma of the retina, but is entirely analogous to Case XIV. Since the eye was enucleated only at a later period, this highly interesting observation serves at the same time as a completion of our description of white, vascular, choroidal sarcoma. The ophthalmoscopic examination, which agrees in every respect with that of Case XIV., is satisfactorily explained by the anatomical condition found, and the Figures 57–60 of my

case. *V. Graefe* relates substantially the following: "A man, thirty years of age, complained for several months of a disturbance of the sight of his eye, appearing under the character of glaucomatous attacks,—periodic darkening of the field of vision and seeing many colors, hardness of the globe, dilatation of the pupil, narrowing of the anterior chamber, opacity of the refractive media, so that the fundus oculi could not be seen. During the remissions these symptoms disappeared, and the refracting media became clear. I found a very considerable bluish-white intumescence in the fundus oculi, between the optic nerve and the equator on the nasal side, of the breadth of fully three diameters of the papilla, and of irregular surface; it formed an eminence of 1½ mm. in height (estimated by the paralactic movements of its summit to the fundus). The retinal vessels were still visible on the portions which were less prominent, although partially veiled in many places by the haziness of the tissue lying before them, whilst in the neighborhood of the tops every sign of vascularization was missing; the surface, everywhere else sharply defined, was here somewhat indistinct, as if small processes extended from the inner surface of the retina into the vitreous. The mass seemed opaque, and gave a very strong reflection, without presenting anywhere the peculiar, brilliant appearance of accumulations of fat-granules in the retina. [The author thinks of the metallic lustre of gliomatous retinæ, where the cells often undergo fatty degeneration. —Ed.] In the vicinity of these larger patches there were also found disseminated smaller whitish herds, of

scarcely perceptible magnitude, situated distinctly in the retina, as was shown by the arrangement of the blood-vessels; around all these metamorphoses there were observed choroidal changes in patches, partly discolorations, partly abnormal pigmentations."

All these symptoms are easily explained by analogy to the anatomical condition of Case XIV. A white sarcoma had developed in the choroid, had lifted and perforated the retina in its centre (Figs. 59 and 60). Consequently the retinal vessels could still be seen on its periphery. In their further progress both these cases remained the same.

"Two months later the visual field, which originally had presented a slight indistinctness externally, became narrowed in a peculiar manner. The whole inner half was missing; then, about 30° more externally, we met with another well-marked defect with semicircular outline. I considered the first constriction due to consecutive glaucoma, whilst the other could be accounted for by the local processes in the fundus oculi. The patient counted fingers at the distance of $1\frac{1}{2}'$ eccentrically towards the outer side. An iridectomy which had been performed to alleviate the pain caused by the glaucoma, was followed by clearing of the refracting media, so that all the details of the fundus of the eye could be seen with precision; the degenerated portion was much greater than originally, measured at least six diameters of the papilla, and had by this extension ingulfed all the smaller herds, so that now they formed one entire mass, which extended over the whole boundary of the

degeneration and was perceptibly raised. With the aid of good daylight, we began to receive a whitish glittering reflex from the fundus oculi in the direction corresponding with the same. In the central most prominent portions small vessels could be seen; towards the periphery they became manifest in such short stretches that it was difficult for us to estimate their relation to the retinal vessels; their number and the manner of their ramification, however, spoke for pseudoplasma. *There now remained no doubt of the development of a retinal tumor.*"

The description is perfectly applicable to the condition of the eye in Case XIV. immediately before the operation, so that it could be referred to the condition of this globe. Fig. 57 gives an illustration of the condition of the surface; Fig. 58, one of the section in natural size, and Fig. 60, which is a slightly enlarged drawing of the section, show how the tumor covered the retina and choroid laterally.

If the conditions of *V. Graefe's* case are explained by anatomical facts, we find the further confirmation of our views in the future fate of the patient, of which *Mooren and Iwanoff* inform us (A. Mooren, Ophthalmiatric Researches, Berlin, 1867, pp. 35–40). The eye was extirpated by *Mooren* at a later period on account of the incessant pain, and afterward given to Mr. Iwanoff for anatomical examination. An episcleral tumor about the size of a hazel-nut was found, and the whole interior of the eye was occupied by three tumors, one of which proceeded from the trunk of the optic

nerve, the other two from the choroid. They had perforated the latter, and had covered it as they increased in size, and had pushed the remains of the vitreous and the retina upon the sclerotic. To judge from its structure, the pseudoplasma was a very vascular, unpigmented, round-celled sarcoma; consequently entirely identical with Case XIV. The relation of the blood-vessels to the cells is not mentioned, more than that the adventitia was thickened here and there, and beset with granules.

In the second case, mentioned in the same article, pp. 242 and 243, *V. Graefe* observed the development of an unpigmented tumor in the fundus oculi from a number of smaller clusters, which later became confluent. The appearance of the tumor was, in the last examination, similar to the earlier stages of the preceding case.

I have entered so minutely into the detail of these cases, because they are till now very probably the only ones in which such early ophthalmoscopic examinations of tumors of the fundus of the eye have been made. The result of the anatomical examinations of the eye in Case XIV. has compelled me to consider such tumors as unpigmented sarcomata of the choroid, with perforation and covering of the retina, which everywhere remained attached to the choroid. This anatomical research explains the condition found in the *Graefe–Mooren–Iwanoff* case, of which ours may be considered as a primary stage.

Instead of giving further directions for the differential diagnosis of retinal and choroidal tumors, I will rather refer to my preceding remarks.

I must now mention two cases in which I made a false diagnosis of choroidal sarcoma. That they at the same time belong to the ophthalmoscopic rarities, at least as regards our knowledge of them, will be shown by a more minute description of the same. The first may serve as an illustration to the differential diagnosis between choroidal tumors, and detachment of the choroid from the sclerotic.

CASE XVI.—*Detachment of the Ciliary Body and the adjoining portion of the Choroid from the Sclerotic.*

Daniel Grub, of Niedermohr, in the Palatinate, 46 years of age, came to me on the 10th of November, 1867, with the complaint that he had never had strong eyes. In the right eye, sight had always been weaker since twenty years, yet he could distinguish larger objects across the street with it, till half a year ago, when a white spot formed in the pupil, and he very rapidly lost his sight.

Status præsens: Left eyeball in appearance, tension, and mobility normal; also the anterior chamber, iris, and pupil. Crystalline lens cloudy at the equator and the posterior pole. Fundus of the eye was somewhat veiled by this, but still to be seen in its details, showing nothing abnormal. Field of vision complete, power of vision $\frac{1}{16}$.

Right eyeball in tension, mobility, and external appearance also normal; the anterior chamber lessened, however, through slight advance of the tremulous iris.

Pupil medium-sized, dilatable. Lens clouded, thickest in both cortical layers; the anterior layer irregularly interspersed with white spots; nucleus still semi-transparent. Lens dislocated inwardly. With dilated pupil, the outer edge of the lens becomes visible, and on the other side of the same, another smaller sickle-shaped ring, which appears red when examined with the ophthalmoscope, but does not allow us to recognize the details of the fundus. The patient is able to count fingers, with dilated pupil, at $\frac{3}{4}'$ distance. Field of vision is retained in all directions, although externally the presence of a light is noticed with difficulty. The prognosis for the extraction of the cataract was not set as very favorable as regards the resulting power of vision, and yet the operation was declared worthy of trial, especially since the other eye had commenced to decline very considerably. After the completion of the cut, made in the usual manner, with *Graefe's* narrow knife in the upper limbus of the sclerotic, a considerable quantity of water escaped, which was more than the anterior chamber could possibly hold. The iris did not prolapse, was therefore drawn forward with Tyrell's blunt hook and cut off. Then I passed a large spoon behind the lens and extracted it, together with the capsule, without difficulty; however, with more loss of watery vitreous. The cornea sank, funnel-shaped; with this exception, there was no abnormal appearance, hemorrhage or the like, during the course of the operation. It was, therefore, accompanied only by so many complications as we might have expected under the

given circumstances: luxation of the lens and fluidity of the vitreous, and perhaps detachment of the retina.

Patient did not complain on the first day and night, nor in the subsequent days either. But when the bandage was changed the next morning, I was astonished to find an immensely large bubble of air in the eye, which filled the whole anterior chamber, and extended through the dilated pupil into the posterior space of the eye. It was recognized thus, that its border moved with the movements of the patient, when it always filled the uppermost portion of the eye.

If the patient bowed forward, the lower section of the anterior chamber was immediately filled with clear fluid, whilst the bubble of air retreated proportionately into the upper vitreous space. I thought of drawing the air out with a Pravaz's syringe, but since it deported itself entirely without irritation, and the incision made for extraction had healed so nicely, I thought it would be better to wait. Evening of the same day, condition the same; on the following morning the air-bubble had undoubtedly diminished, and this occurred day by day more, until after the eighth day it had totally disappeared.

From the healed cut, lightly striped opacities had entered the parenchyma of the cornea, as we commonly see it, in variable degrees. The power of sight did not amount to more than a quantitative perception of light. The fundus of the eye appeared in the ophthalmoscopic examination of a dirty red, which indeed, as we could

convince ourselves on examining with oblique light, was occasioned by blood extravasated in the vitreous.

Patient was dismissed thirteen days after the operation. He saw movements of the hand, and had still many striped vitreous opacities, without demonstrable detachment of the retina.

On the 29th of December, 1867, five weeks later, he again appeared, and related the following: In the first week after his discharge his eye became somewhat clearer, but he could not as yet distinguish objects with it. Four weeks ago he remarked that one evening out of that eye very much clear fluid escaped, which ran down his cheek like water. There was no pain whatever connected with this, but he could hardly sleep during the night, and therefore noticed that out of this eye water continued to flow ten or twelve hours longer. Subsequent to this his power of sight continually diminished, until after three weeks it had totally disappeared. Eight days afterwards he came again to me in the following condition: The eyeball is nearly free from redness, only on the superior portion a few more vessels traverse the sclerotic; it is evidently smaller and very soft (—T_2 Bowman); pressure on the upper scleral portion is painful; anterior chamber is again restored. The cut for extraction was well cicatrized, with the exception of a spot in its middle, which appears glassy and lightly contracted; the cornea still slightly streaked; anterior chamber clear; in the pupillary plane a very tender, bluish-white, narrow stripe. With oblique light, and also with favorably-falling day-light, we distinguish

close behind the pupillary plane in the vitreous space, three brownish hemispherical tumors, with a velvety surface (Fig. 68, tu); they are all situated in the ciliary region, touch each other at their borders, and completely conceal the upper and inner portion of the vitreous. The lower and outer section of the posterior space of the eye is filled with an opaque-white membranous mass; on the lowest of the three tumors, parallel to the basis of the cornea, a white membranous stripe is situated; the middle tumor advances with its anterior border to the apices of the ciliary processes, which it seems to have dislocated somewhat anteriorly, for we see the same distinctly behind the upper limbus of the cornea, and their continuation is lost in the surface of the intumescence. No vessels nor any other prominent feature are noticed on any of the tumors, nor on any other portion of the fundus of the eye. Light is altogether extinct.

The diagnosis was set on the probability of a melanotic sarcoma, and indeed, because we could directly see the spherical lumps of dirty-brown color. However, this circumstance appeared remarkable, that the patient had for more than twenty years had poor sight in this eye. If this was the commencement of the affection it could not have been a sarcoma, for there is no example extant of such slow development of such tumors. Further, the great amount of softness of the eyeball also spoke against this. We find mentioned only in one place (V. Graefe, see above, p. 186), that in the first stage of the development of an intraocular tumor the tension of the eye was diminished, but in a much less degree. The

hemorrhage which had taken place in the vitreous during the healing after extraction caused me to think of extravasated masses of blood, which had lain encapsuled in some form in the eyeball. If, however, such hemorrhages are, after the extraction with the capsule, not of rare occurrence (see the article of my assistant, Dr. Bergmann: Ueber die Extraktion des grauen Staares mit der Kapsel. Arch. f. Ophth., XIII., pp. 383–397), they nevertheless tend soon to be absorbed, and the interior of the eye again becomes clear, and the sight generally satisfactory.

In spite of these conditions speaking against the presence of tumors, the direct appearance of the spherical, dirty-brown prominences in the ciliary body, was so like that of sarcoma of the ciliary body, that the probability seemed to me much greater for this than for anything else.

Therefore, also, the prognosis and indications were of a very critical nature. To wait until the diagnosis of a sarcoma should have become more certain by the institution of pain and increase of tension, would have made the prognosis, *quoad vitam*, in the same degree more unfavorable.

The eye being here as an organ of sight irretrievably lost, since even the last traces of perception of light were already gone, a false diagnosis would only have had the consequence of removing a useless eyeball, whilst the omission of the extirpation of the sarcoma, diagnosticated with probability, would have undoubtedly endangered life if the diagnosis were confirmed.

The danger of omitting the operation on the one hand, and the harmlessness of its execution on the other, determined my course without hesitation. I enucleated the eyeball on the 31st December, 1867.

Anatomical Examination of the Enucleated Eye.

I halved the globe by means of a meridional section running through the middle of the coloboma. Serous fluid of a slightly bloody color escaped, and in so doing all the fluid contents of the globe emptied themselves, since the vitreous was perfectly watery. The surface of the meridional section, by means of which the globe was halved, measured 21.5 mm. from before backward, and 20.5 mm. from right to left. The globe was also lessened about 3 mm. in all its diameters.

Nothing could be found of sarcomatous or other tumors, but a *very remarkable detachment of the ciliary body and anterior part of the choroid from the sclerotic*, by which the hemispherical prominences were produced. The sclerotic was atrophied in the ciliary region, but considerably thickened at the equator (Fig. 69, scl). Its tissue everywhere tough, tendinous, and white. The iris (is) was normal, the choroid (ch) in the posterior section of the globe was applied to the sclerotic, and appeared normal. In its anterior portion it and the entire ciliary body (sch) were detached from the sclerotic, so that here an annular space (r r), filled with a clear fluid, whose height was 8 mm., and breadth 4 to 5 mm., was situated between them. The ciliary body

thus pressed in, formed those lump-like prominences which during life were mistaken for sarcomatous tumors. In several places it was covered with grayish-white, membranous patches, which might have been products of inflammation.

The retina (re re_1) was not detached from the choroid, and had also retained its attachment to the optic nerve and ora-serrata. For the present, I did not wish to examine more minutely, and thereby destroy the very instructive specimen of which Fig. 69 represents the two unfolded halves. I will only yet observe that the detached ciliary body (c c) and the inner surface of the sclerotic (r), as far as it lay uncovered by the detached choroid, were smooth and white. The cause of this detachment of the ciliary body and the neighboring portion of the choroid appears to me without doubt to be that (certainly chronic) thickening of the sclerotic, to which perhaps a plastic inflammation, following the forcible removal of the crystalline lens, on the surface of the ciliary processes supervened as another cause. After a serous fluid had been exuded between the ciliary body and the sclerotic, it might have been followed by a loosening and atrophy of the latter, which, however, was not very considerable.

For the diagnosis, this truly exceptional case teaches the important fact, that we must very closely consider the structure of the surface of a lump; the less this resembles the inner surface of the choroid, and the more this appears dirty-gray, or spotted and nodular, the more we will be justified in considering it a degeneration, a

pseudoplasma. If it, however, resembles the normal, and appears regularly brown and velvety, we should consider it a simple *detachment.*

The following case may serve as an illustration of the differential diagnosis between choroidal sarcoma and detachment of the hyaloid from the retina :

Case XVII.—*Detachment of the Hyaloid Membrane from the Retina.*

Madame Ruch, of Strasburg, 58 years of age, has noticed for two years a gradual reduction of the sight of her formerly entirely healthy and not myopic eye, and since the last year she scarcely can see at all with it. Accompanying this she had no manner of pain or ailing, but had frequent attacks of headache. As she appeared three days ago, for the first time in my clinique, the external appearance, the size, tension, and mobility of both eyes were altogether alike, and not differing from the normal. Both eyes had normal anterior chambers and irides, normal, wide, and dilatable pupils, and about equally ripe equatorial cataracts, which in the left eye yet allowed a clear view of the unchanged fundus oculi.

In the right eye there was apparently a total detachment of the retina. The interior of the eye could not be illuminated red. Superiorly and outwardly it seemed to be gray, and inferiorly and inwardly yellowish-gray and whitish. With oblique light this was noticed in the same manner, and we recognized with it that the whitish-yellow mass reached close to the lens, commenced in the

region of the ciliary body, was thickest on the lower portion, and traversed by several red stripes and spots, and terminated with an indistinct boundary, after an apparent ascension of 4 to 5‴ towards the axis of the eye, and yet remained covered by the retina. In order to receive a clearer explanation concerning the nature of this whitish-yellow mass proceeding from the ciliary body, I examined the patient in a totally darkened chamber, in which, by means of a heliostat, the rays of the sun were thrown, by direct sunlight, with the ophthalmoscope and focal illumination. The patient bore the intense illumination without any trouble, since she only had slight traces of perception of light inferiorly and externally. The result of this manner of examination was the same, only the opacity of the whitish-yellow mass could be further confirmed by it. I reached very carefully for a gray or black coloring in some place which would have insured the diagnosis of a choroidal sarcoma; yet even the most intense illumination with direct sunlight showed no traces of it.

The diagnosis remained uncertain. I was in doubt whether it was a *purulent plastic process or a choroidal sarcoma.* For the former spoke the appearance and the irregular line of demarcation; against it, however, in a high degree, the development completely painless and without inflammation, which made it probable to me that a soft, white, ciliary sarcoma had slowly been formed, in which opinion I was strengthened by the presence of the vessels in the thickest portion of the mass. I thought the presence of a sarcoma the most probable, and there-

fore, also, the enucleation of the eye justified, on considering that a mistake in diagnosis would only, at the most, bring with it a slight, easily-borne cosmetic injury, in addition to the blindness of the patient, already incurable on account of detachment of the retina. Whatever nature the vegetative process in question on the ciliary body might have, it was always dangerous for the organism or the other eye, whether it tended to inflammation or to foreign growth.

The eye was, in consequence of this, enucleated, and immediately afterwards divided by a cut in the vertical meridian. A watery, yellowish fluid, mixed with blood, flowed out of it.

Under the microscope this showed an admixture of numerous blood and pus-corpuscles.

The retina was apparently detached in its whole extent, being, however, connected with the optic nerve, and with the entire ora-serrata. Yellow flakes (appearing purulent) traversed the anterior, and principally the inferior portion of the vitreous still remaining in the eye. They could be picked out with the forceps, and spread on the object glass in the viscid, still clear, vitreous fluid surrounding them. Under the microscope there was found a finely granular mass, among rather closely-packed pus-corpuscles.

The eye was laid in alcohol, and I was not a little astonished to find, several hours afterwards, the retina totally uninjured, lying everywhere on the choroid. When freshly opened it had been so transparent that it had been entirely overlooked. That membrane, how-

ever, which was fastened to the optic nerve and the ora-serrata, and enclosed the funnel-shaped, yellowish, opaque vitreous space, was nothing else than *the hyaloid membrane detached from the retina.* Fluid had collected between it and the retina in the same manner as generally between the detached retina and the choroid.

The microscopical examination disclosed peculiar relations, into which I cannot here enter in detail. The hyaloidea was a perfectly homogeneous hyaline membrane, upon whose inner surface oval nucleated cells, with two very long and distinctly-defined processes, were heaped at greater and lesser distances from each other. They also entered, less densely however, into the homogeneous substance, and we could clearly discern how the processes of different cells ran into each other. I did not meet with lateral processes in these elongated and fusiform cells. The *outer* layer of the *choroid* which faced the retina was free from formed elements. Toward the vitreous, however, the fusiform cells constantly became more compact, touched each other; more internally they became shorter and rounder, until at last they went over into pus-cells. These lay in great numbers in a finely granular coagulated mass, and formed a thick layer on that portion of the hyaloid corresponding to the lower and inner section of the ciliary region. Toward the axis of the eye and posteriorly the pus-corpuscles constantly became scantier in the coagulated vitreous humor.

The whole then was a *suppurative, plastic hyalitis which, through the contraction of the cells of the connective*

tissue, situated on the inner surface of the hyaloid, had detached the hyaloid from the retina.

This case has induced me to be extraordinarily careful in diagnosis. That *inflammatory processes in the vitreous humor occasion disproportionately slight symptoms of irritation, I have known long ago, but it was new to me that they deposit such extensive purulent plastic products entirely without irritation, and at the same time can detach the hyaloid from the retina for the whole of its extent.*

The rarity of this occurrence will naturally leave but rare opportunities to mistake it for other conditions, and especially tumors. Suppurative hyalitis, with detachment of the hyaloid, is distinguished from white sarcoma by its indistinct line of demarcation, and from the common form of detachment of the retina by the presence of the yellow collections of pus and the absence of ramification of vessels similar to that of the retina.

C. *Etiology of Sarcoma of the Choroid.*

Of the circumstances causing the formation of sarcoma, the present cases of my own observation afford but very few data from which deductions might be made. In the boy of Case XV. trauma had preceded, and this could very well have given the impulse to the hyperplastic inflammatory processes which had resulted partly in transitory products, suppuration, but partly also in permanent portions of tissue, namely, elements of connective tissue in marked transition to the peculiar arrangement and form of the sarcoma tumor.

That spontaneous inflammations in the interior of the eye, namely, irido-choroiditis, can occasionally give the incentive to the formation of sarcoma, I do not at all contradict, although I would rather have otherwise explained the case of Hulke already mentioned (p. 234), which seemed to belong to this class. I refer, however, to that which I have said concerning the development of inflammatory tumors on p. 231.

It is known that injuries can be the cause of the formation of tumors of the most different kinds; therefore I will not repeat here what others, and especially *Virchow*, have so clearly explained in different places.

M. Landsberg (Arch. f. Ophthalm., XI., p. 58) relates a case in which a piece of wood struck an eye amblyopic from childhood consequent to squinting, but with this exception free from irritation, and caused inflammatory symptoms and loss of sight. After this condition had lasted more than a year, Dr. Schueller enucleated the very tense eyeball in which a tumor had formed (see below, Appendix, p. 288).

I could not give a direct cause in all the other cases.

The age has certainly an influence on the formation of sarcoma. With the single exception of the sarcoma which had formed from preceding inflammatory processes, the other cases were all in adults, of which only one, the white vascular sarcoma, developed in the middle; all the others, however, in the advanced and latest periods of life. These circumstances also are too well known that I should dwell longer on the subject. I will only mention once more the immense difference between the period

of development of the retinal glioma and the choroidal sarcoma. Whether the same is true of other forms of retinal and choroidal tumors not noticed by me, must be taught by further more detailed and more lengthy examinations.

That the nature of choroidal tumors, as of tumors in general, is in a high degree influenced by the quality of the mother-tissue, is evident from our cases already in the preceding discussion, according to which the sarcoma appearing in the outer, denser, more pigmented, and less vascular layers of the choroid were of the harder, less vascular, and less pigmented forms, and those arising in the chorio-capillaris of the softer, more vascular, and unpigmented forms of tumors.

Constitutional causes and disposition were not remarked. All individuals to whom our cases relate were healthy, with the exception of Case XIV., where a great bodily weakness and anæmia had ensued after a long-standing and extensive caries of the ribs.

D. *Prognosis of Sarcoma of the Choroid.*

Sarcoma in general is a disease terminating fatally sooner or later; no case of spontaneous cure is known with certainty. This assertion is particularly applicable to choroidal sarcoma, which therefore must decidedly be classed among malignant growths. However, as regards their degree of malignancy they do not stand foremost, but are secondary to the carcinoma proper. Choroidal sarcomata are homœoplastic tumors, and for this reason alone more benign than carcinoma. That the

fusiform-celled sarcomata, particularly the tougher forms which are poorer in vessels, and especially those which contain more fibrous intercellular substance, are less malignant than the vascular forms containing a large quantity of cells, is known to all, and is founded on the richer channels of nutrition, consequently on the more favorable conditions for the more rapid increase of the latter. Further, small-celled sarcomata, whether spindle-shaped or round-celled, are more malignant than the large-celled.

If we refer to our observations we find in Case IX. a tough, melanotic, fusiform-celled sarcoma, with small herds, about the size of a pin's head, externally on the sclerotic, perfectly cured now three years after the operation, the same of a white fusiform-celled sarcoma (Case XIII.), and a white fibro-sarcoma (Case XV.), the two latter still completely intra-ocular. These three cases, if we are disposed to optimism, may be considered as permanent cures. If, however, we look as unfavorably as possible on the matter, we must still allow that the operation has at least prolonged the lives of the patients. In Case XIV. the patient died of another disease; but since it was only half a year from the time of operation, we cannot say that it prolonged life in this case. Certain it is, however, that it would either have entirely removed, or at least delayed the danger of death threatened by the sarcoma.

The remaining four cases died within the first year after the operation through generalization of the choroidal sarcoma.

If we draw the conclusion from these eight cases that about one-half the cases of choroidal sarcoma can be cured by the extirpation of the globe, it is a much too favorable proportion for our present practice, and still more so for that of the past. At least this much can be certainly deduced from them, that the prognosis of choroidal sarcoma is now rendered more favorable by the healing art, consequently that even in this disease the physician is of benefit. In how much treatment is capable of improving the prognosis, is, in the first place, dependent on the nature of the case under consideration, but especially on the stage of development in which the tumor is found at the time of operation. Since tough, fusiform-celled sarcomata which are poor in vessels increase but slowly in size, a longer interval of life, independent of all treatment, is granted to the patient; therefore an operation followed by cure would lengthen life by a lesser number of years than if it removed a rapidly growing tumor.

As regards the second point, we can assert that the operation is the surer, and the cure the more durable, the earlier the tumor is removed. If we go to the limit of the assertion, as mathematicians are in the habit of doing, we come to the conclusion that the operation undertaken in the first stages of the formation of the tumor will with certainty remove and cure the affection. This assertion has already long since, and until the present day, been attacked and defended from many sides. Whether the carcinomata have a commencing stage in which they are purely local affections is, not

withstanding the best authorities, still doubtful. That, however, the sarcomata in the commencement are purely local, therefore non-malignant maladies, is much less disputed than with carcinomata. I, myself, am entirely of this opinion, but consider that further researches on this point are not to be dispensed with. Such researches can be undertaken on no other portion of the body with more positive results than on the eye, because here the minutest commencement causes the patient immediately, on account of his disturbance of vision, to seek medical aid. If our power of diagnosis is sufficiently educated to recognize this commencing stage, the enucleation of the eye will here be the rational mode of cure, and the total extirpation of the pseudoplasma will be so much the surer, and will be possible in many more cases, since the sclerotic offers a more effective barrier to the spreading into the vicinity than the neighboring tissues of tumors in any other portion of the body. Our decision, whether an infection of the neighboring tissue has already taken place or not, is less liable to error in the case of the eye than in other parts, because we are enabled, through the smallness of the object, to divide the whole tumor with its surrounding tissues into microscopical sections. If we find neither sarcoma clusters on the outer surface of the fibrous coat of the eye, nor microscopical sarcoma-cell passages in its transverse section, then we are perfectly justified in taking for granted that an infection in the neighboring tissues has not yet taken place.

However, the general infection through lymphatics and blood-vessels can, without doubt, be already present

before the extension to the neighboring tissues has taken place; nevertheless, this succession of symptoms does not appear to be the common one; as a general rule, the constitutional infection in most sarcomata seems to make its appearance at a later period.

For the determination of these questions, we must have clinical observations concerning the further progress of cases, which, as regards their anatomy, have been well examined. It seems to me, therefore, desirable that in the publication of such cases the address of the patient should also be given, so that every one who is interested in such observations can inform himself as to their further progress. If we review our cases, we will find in the *four* cases of cure that the affection *three* times was purely intraocular (Cases XIII., XIV., XV.), and in one case (Case IX.) we found microscopical passages through the sclerotic, and three small episcleral clusters of the size of pins' heads, which, however, were still perfectly isolated.

In this case we can also consider that the extirpation was a complete one, and that the constitutional infection, in all four cases in which a dissemination into the neighboring tissues had not taken place, had not yet supervened. More convincing still than these cases, is that of *Prof. Dor* (Arch. f. Ophthalmol., VI., 2, p. 244). The patient, 56 years of age, had in the year 1858 first noticed a black portion in the field of vision of his right eye. The enucleation of the eye was made in January, 1860, whilst in a state of glaucomatous inflammation. The eyeball was slightly enlarged in its dimensions; the

tumor, a melanotic, tough, fusiform-celled sarcoma of the choroid. A short time ago *Prof. Dor* wrote to me that the patient since then had had no local recurrence, that no disturbance in the power of vision had occurred in the other eye, and until now, nine years after the operation, the patient had been perfectly well. In this case, therefore, there was also no spreading in the neighboring tissues. Another favorable result after enucleation is the following, of which *Dr. J. W. Hulke* sent me the history, most obligingly: "I saw on Sunday last, October, 1868, in perfect health, a gentleman whose eye I enucleated April 2d, 1862, for a white, spindle-cell sarcoma of choroid which I, at that time, considered a medullary cancer. The drawings, which I still possess, of the finer structure of the tumor leave no doubt that, from an anatomical point of view, we should unhesitatingly place it in the family sarcoma." Further, I may mention two cases as favorable examples which, on the occasion of a discussion on this subject, *Prof. O. Weber* reported in the *Med. Naturhistorische Verein*, in Heidelberg, namely, that both of the cases of choroidal melanosis were still perfectly well, one thirteen, the other twenty years after the operation.

If the most pessimistic believer in the malignancy of melanosis should not wish to designate such cases as permanent cures, he must, nevertheless, concede that life is at least prolonged by the extirpation.

V. Graefe makes the prognosis of melanotic tumors as entirely unfavorable. He says (Arch. f. Ophth., X., 1, p. 176), in speaking of it, as follows: "I, myself,

when I bear in mind all the cases of my experience, can remember no case in which, after a very thorough extirpation of a tumor of this nature, the state of apparent cure had lasted more than four years. In the majority of cases, recidives partly local and partly in other organs set in after one-quarter, one-half, or one year."

Although we must consider the results of operations undertaken in the first stage of the malady in general as favorable, this does not hold good in the second stage, that of glaucomatous inflammation; for in such cases the general infection through the lymphatics and blood-vessels could have been previously present. Thus the patient mentioned in our eighth case, succumbed nine months after the operation, to metastasis to the vital organs. Yet in this stage operations followed by permanent cure have been performed, as is illustrated by our thirteenth case and that reported by *Dor*.

If, however, the next stage, that of extension to the neighboring tissues, with secondary episcleral or orbital herds, has set in, the malady is only exceptionally annihilated by the operation, in such cases where, as in Case IX., we have to do with the first isolated traces of accumulations on the sclerotic, which may yet be completely removed. Examples of this are Cases X. and XI. In the former, no glaucomatous irritation had as yet set in, but the episcleral tumor had already attained a considerable development, and constitutional infection had begun already at the time of operation. That this was the case, and that the poisoning of the fluids did not take

place later through the germs of the tumor which had remained in the orbit, is demonstrated by the fact that no orbital recidive had ensued during the nine months which the patient still lived, for which reason we must assume that no germs had remained in the neighboring tissues.

If the globe is perforated, and clusters are present in the orbit, our hope of permanent cure is reduced to a minimum. It is possible that a total extirpation of the entire contents of the orbital cavity may result in cure, still it is much more probable that the germs of pseudoplasma have already been carried to distant organs through the blood-vessels.

J. W. Hulke was kind enough to send me further notes on his case, which has been briefly mentioned on p. 234 of this book. There had been voluminous melanotic masses in the orbit, proceeding from the eyeball. After the removal of the tumor *Hulke* used the actual cautery and caustic zinc paste to complete the destruction of the tumor in the bony walls. The wound healed well, and the patient quite recovered. In October, 1868, that is three years and three months later, when *Dr. Hulke* saw him last, he was still free from any sign of recurrence of the growth.

This is an encouraging example with regard to both the prognosis and treatment.

The metastases are absolutely fatal.

E. *Treatment of Choroidal Sarcoma.*

The treatment of the affection which we have so minutely considered in the foregoing remarks, can be comprised in a few words. If the diagnosis has been made certain, we must not hesitate with the enucleation of the eye whilst the disease is still intra-ocular. This is indicated not only in the first stage, when no increase of tension or symptoms of irritation have as yet manifested themselves, but also in the second stage, when glaucomatous inflammation, with increase of tension, and even distention of the capsule of the eye, are present. As is shown by *Dor's* case and our thirteenth case, the cure even then is possible.

We would advise, immediately after the enucleation, to examine the eyeball with care, especially the end of the optic nerve, for occasionally the pseudoplasma continues for a short distance in it, a fact to which *Jonathan Hutchinson* (Ophth. Hosp. Rep., V., pp. 88–93) has drawn especial attention. In such cases we should excise a still larger piece of the optic nerve from the orbital cavity. The optic nerve is easily felt through the orbital tissues, can be seized with broad forceps, pulled forward, the forceps be given to an assistant, and with the index-finger of the left hand feeling its way into the orbit, the optic nerve, whose position we have ascertained in this manner, is cut through as far back as possible. In sarcoma the necessity for this subsequent operation is rarer than in glioma, as we have already seen.

If secondary herds or local recurrences are present in the orbit, the total extirpation of the contents of the orbital cavity is indicated. We may at the same time remove even portions of bone; for, even if we can no longer save the patient from death, we can at least spare him the annoyance which a decaying, stinking, frequently bleeding pseudoplasma in his face causes, inasmuch as it presents a horrible picture of fright and disgust, not only for the patient himself, but also for those around him.

I may assume that the manner of execution of the total extirpation of the contents of the orbital cavity is well known. Yet I will only add that this operation, which was practised more frequently in former times, is not entirely without danger to life. However, fatal issues are still rare occurrences, and we can even boldly cauterize with the moxa the bony walls of the orbit in order to destroy every portion of pseudoplasma, without having to dread any accident to the neighboring parts, especially the brain. *J. W. Hulke* (Ophth. Hosp. Reports, V., p. 181) relates further, that during the last years many favorable experiments on the availability of chloride of zinc paste have been made in the Cancer Department of the London Hospital. One portion of chloride of zinc with four parts of flour, mixed intimately with sufficient quantity of tincture of opium to form a paste of the consistence of honey. This is then spread on lint or linen, and the walls of the orbital cavity lined with it. Only slight inflammatory symptoms of the tissue under the slough, and unimportant general reaction, fol-

lowed upon the use of this means of cauterization, whose primary effect we could easily regulate.

The treatment where metastases have once set in is purely symptomatic, and needs no further discussion in this place.

APPENDIX.

Notes on other Forms of Tumor occurring in the Eyeball.

As the foregoing examinations are the results obtained from my own clinical material, and as tumors other than those described have come too rarely under my personal observation, the treatise should terminate here. Still, for the sake of completeness, I will take from medical literature a few observations worthy of mention, and will add what little I have gathered from my own experience.

(1.) *Sarcoma carcinomatosum* is described as a mixed form by *Virchow* and *Landsberg*.

Virchow's case is described by *V. Graefe* (Arch. f. Ophth., X., 1, pp. 179–184). It was remarkable, as was mentioned there, for its extraordinary slow course: 1st stage, 7 years; 2d (glaucomatous) stage, 6 years. The intraocular choroidal tumor found after enucleation did not fill the globe by far, and was described by *V. Recklinghausen* as sarcoma; by *Virchow*, in a later examination, as sarcoma carcinomatosum. "In the tumor there are without doubt extensive tracts which bear all the characteristics of sarcoma. Yet in a tumor situated on the sclerotic and in a portion of the principal pseudoplasmic mass, the same alveolar structure, and the same

filling of the alveolæ with crowded, large, round or polygonal, partly pigmented and partly unpigmented, cells are found as were later present in the recurrence. Consequently we have a *mixed tumor* before us. We cannot say that a sarcoma has become carcinomatous, for we can demonstrate clearly that the carcinomatous proliferation arises in the connective tissue without there having existed an intermediate sarcomatous stage between the original condition of the connective tissue and the ensuing cancerous state."

Very similar is the description of *Landsberg's* case (Arch. f. Ophth., XI., 1, pp. 58 to 68). As a consequence of trauma, a tumor, which proceeded from the choroid, had arisen and grown into the vitreous humor as a round and fusiform-celled, soft sarcoma; near it, however, the sclerotic was invested by a tougher tumor which extended both into the interior of the eye, and on its outer surface into the orbital space. It enclosed spindle-shaped, round, and polygonal cells in the meshes of a tough, fibrous network. This portion Landsberg regards as carcinoma, and considers the whole pseudoplasma as a *combination tumor* of simultaneous development. The same cause, trauma, should have excited the development of a melanosarcoma in the choroid, and of a carcinoma in the sclerotic.

E. Klebs (Arch. f. Ophth., XI., 2, pp. 253 to 257) described a case of mixed sarcoma and carcinoma teleangiectodes which is very similar to our Case XIV., and which probably must also be explained in the same manner. Only it appears that the retina was not perforated.

An intraocular tumor with external clusters is also described by *Schiess-Gemuseus* (Arch. f. Ophthalm., X., 2, pp. 109–136), as proceeding partly from the choroid, and partly also from the sclerotic (?). The larger portion was regarded as a *carcinoma*, the smaller as *tubercle*. From the description I could not convince myself of the correctness of this view. It seemed to me rather to be a partially pigmented, fusiform-celled sarcoma with perforation through the sclerotic, secondary metamorphoses, such as fatty degeneration, softening, etc., giving the appearance of the existence of tubercle.

As component parts of the tumor, there are mentioned: abundant fusiform cells of extraordinary beauty, smaller and larger round cells, vessels, products of retrogressive metamorphosis and a stroma of connective tissue "which, when compared with the number of cells, is so abundant that we cannot but rank it with carcinoma." However, the alveolar structure and the epithelial character of the cells are not mentioned in the description.

(2.) *Sarcoma of the Iris.*

(a.) *White Sarcoma.*

A rare and beautiful case of tumor of the iris was presented January, 1869, by *Drs. Pardee* and *Roosa* at the New York Ophthalmological Society, where I had the opportunity of seeing it myself. It was in a servant girl; had begun, without any irritation, as a small swelling in the lower part of the iris; had slowly increased until after about a year and a half, if I remem-

ber right, it had reached its actual size, being a tumor about as large as a hazel-nut, but flatter, touching inferiorly the posterior wall of the cornea, and occupying about the lower four-fifths of the iris, leaving a small upper segment of it intact. By instillation of atropine the unaffected part of the blue iris contracted ad maximum, and a small, crescent-shaped, black pupil became visible. Eccentric sight and visual field were both normal. The tumor itself was white, with a reddish tint, and traversed irregularly by numerous blood-vessels. Some purely white dots in its superficial layer indicated, as it seemed, fatty degeneration. This growth can hardly be considered as anything else but a white *sarcoma of the iris*. The patient refused the enucleation of the globe.

Another case is described by Dr. *Lebrun* (Annales d'Oculist., LX., p. 208), in a woman of 36 years.

(b.) *Melanosarcoma of the Iris.*

J. Hirschberg (Arch. f. Ophth., XIV., 3, p. 385, etc.) describes a very interesting specimen of *pigmented fusi-cellular sarcoma of the iris*, which had been extirpated by *V. Graefe* in 1868. It originated in a "black spot" on the iris, which had existed during the whole life-time of the patient, a healthy man of 38 years of age. One year ago the spot began to enlarge, and continued to do so without any irritation or pain, until at the time of admission of the patient, it had reached the apparent size of a hazel-nut, leaned against the posterior wall of the cornea, left the upper part of the iris and pupil free, and was darkish-brown in color. The eye appeared

quite healthy besides. S, T, and F normal. After the extirpation the eye was examined and found sound in all its membranes, except the lower half of the iris, which was replaced by the tumor. The boundaries of the latter were rather abrupt. The growth seemed to have originated in the anterior layers of the iris, and consisted of pigmented and unpigmented spindle-shaped cells, homogeneous intercellular substance and blood-vessels, showing the usual form of *melanosarcoma.*

(3.) *Myosarcoma of the ciliary body* is described in a case of Iwanhoff's (Compte-rendu du Congrès international d'Ophthalmologie, 3e Session, p. 118, Paris [J. B. Baillière], 1868). A tumor of the size of a hazel-nut pushed the iris forward, crowded the lens to one side, and caused detachment of the retina and choroid. The eye was extirpated by Wecker. Until now, two and a half years later, no recurrence.

The cut surface of the tumor was white, slightly striped, and slightly pigmented only at the periphery and the portion adjacent to the iris. It occupies the entire length of the inner section of the ciliary body. In the section adjoining the sclerotic, the tumor, which is from 4 to 5 mm. in thickness, consists of *fusiform cells arranged in bundles*, and containing distinct *rod-like nuclei.* The cells possess all the properties of the unstriated fibres of the ciliary muscle, but are twice as large. The inner layers of the tumor, for a thickness of 2 mm., consisted of *round cells*, and also in part of *strongly pigmented stellate and spindle-shaped cells.*

Formative (embryonic) cells were disseminated in great abundance between both varieties of cells and in the tissue nearest to the tumor. The duration of the latter was not given. The author regards it as myosarcoma, and as non-malignant. Hypertrophy and hyperplasy of the muscle cells of the ciliary body appear to be well-established, and the occurrence of myoma of the ciliary body worthy of our attention.

(4.) *An example of a vascular* (*teleangiectatic*) *tumor of the iris* is described by *Mooren* (Ophthalmiatrische Beobachtungen, p. 125). On the outer portion of the iris was situated a tumor of the appearance and size of a blackberry, traversed at its surface by rather large and winding blood-vessels. On ophthalmoscopic examination nothing abnormal was revealed, and sight and visual field proved normal. When the patient shook his head and bent it forward, the anterior chamber became filled with blood, and sight was reduced to mere perception of light. When, hereafter, the patient held his head backward, the blood gradually disappeared so completely in the course of a few seconds, that no trace of it was discernible, and vision became normal again. The tumor shrunk to a certain extent, but iridochoroiditis glaucomatosa developed in the eye. The patient always declined an operation, until the sight of the eye was destroyed and violent pain had set in. This was relieved by an iridectomy. Subsequently the other eye was affected with (sympathetic) iridochoroiditis, which was cured by proper treatment and the performance of an artificial pupil.

(5.) *Syphilitic tumors* (*gummata*) in the eye have twice been anatomically described; the first time by *Alfred Graefe* and *Colberg* (Arch. f. Ophth., VIII., 1, pp. 288–296), as a node on the iris of the size of a pea; the second time by *V. Hippel* and *Prof. Neumann*, in Königsberg (Arch. f. Ophth., XIII., 1, pp. 65–74), where a tumor about the size of a bean had developed in the ciliary body, and extended to the neighboring iris and choroid. The structure of these tumors was that of gummata,—small cells, resembling lymph corpuscles, in scanty intercellular substance, and more or less vascular.

During life, *syphilitic excrescences on the iris* are not rare. They are not always similar in their origin. In one kind which appears to be rarer, transparent, *waxy*, round, circumscribed nodes of the size of millet seeds or pins' heads are embedded in the zone of the iris. The remaining signs of iritis coexist. The second form appears as a circumscribed, *reddish intumescence* of the anterior surface of the iris (*papula*), which as it increases projects more and more beyond its plane, and grows into the anterior chamber as a single or cleft condylomatous excrescence. These formations do not remain distinct for a long time, but new ones develop in the neighborhood which augment like the first, decay in part frequently, bleed, arrive at the posterior wall of the cornea, and fill the anterior chamber more or less completely, as a fungoid mass. In their further progress, when undisturbed, they destroy the eyeball; with antisyphilitic treatment they gradually become absorbed, and leave larger or smaller cicatrices proportionately

to the extent of mother-tissue implicated in the pseudoplasma.

Sometimes the gummy products form a *grayish-red, dirty wheal, deposited around the pupil.* This appears to be a less compact, diffuse infiltration of lymphoid cells in the tissue of the iris, for in about one-half of the cases, lues does not lead to any pseudoplasmic formation, and cannot be distinguished from ordinary iritis by its appearance.

(6.) *Tubercles in the choroid* were first described anatomically with satisfaction by *Manz*, in Freiburg, i. B. (Arch. f. Ophth., IV., 2, p. 120, and ibid., IX., 3, p. 133). At a later day, *Busch* reported a case (Virchow's Archiv, XXXVI., p. 448). But *Cohnheim* (Virchow's Archiv, XXXIX., pp. 49–69) described them more minutely last year, and was followed by *V. Graefe's* and *Th. Leber's* anatomo-clinical paper (Arch. f. Ophth., XIV., 1, pp. 183–206). According to these authors, miliary clusters are present in the choroid in all, or nearly all cases of general acute miliary tuberculization, but not in localized pulmonary or mesenteric tuberculosis. They appear as small, round, whitish nodes, from $\frac{1}{10}$ to $2\frac{1}{2}$ mm. in diameter, disseminated throughout the substance of the choroid. Their seat is ordinarily at the posterior section, encircling the optic nerve, yet they may spread to the most anterior portions of the choroid. The smaller ones are invariably covered by pigment, and are easily overlooked in the ophthalmoscopic examination; the larger ones, however,—of one-

fifth mm. and upwards, in diameter,—are without the pigment covering at their centres, and appear as projecting round nodes. They differ neither macroscopically nor microscopically from the ordinary tubercle. According to *Manz*, they arise from a proliferation of the cells of the external coat of the blood-vessels; according to *Busch*, from the unpigmented stroma cells of the choroid; and according to *Cohnheim*, from the lymphoid bodies which are irregularly scattered in the tissue of the choroid, and which he considers to be migratory cells.

(7.) *A lipomatous tumor* of the iris is described by *Mooren* (l. c., p. 128). On the outer segment of the iris of a girl of ten years, a smooth, whitish-yellow tumor had gradually developed to the size of a large pea. Mooren removed it with the corresponding piece of iris, performing thus a large iridectomy. "The tumor was tense to the touch, its contents resembling those of a *fresh atheromatous cyst.* The microscopic examination made by *Dr. Siering*, left no doubt on the lipomatous nature of the tumor."

Further observations must show whether lipoma is to be registered as a special form of tumor in the iris, or whether we had better classify the specimen just described among the following group:

(8.) *Cysts of the iris* have not been observed very seldom. *L. Wecker* (Etudes Ophthalmolog., Tom. I., p. 397) gives a compendium of their literature. *W. Bowman* (Lectures on the Parts concerned in Operations of the Eye, p. 76. Lond., 1849) says the following: "This

slowly developing disease begins as a small, circumscribed elevation of the iris toward the cornea. It appears to me, that the first fluid contained in the cavity causes a swelling of the iris toward the lens and the zone of Zinn; since, however, the resistance of these parts soon checks the further extension backward, the collecting fluid pushes the anterior layer of the iris forward, and forms a semi-globular projection into the anterior chamber."

The size of cysts of the iris is variable; generally not exceeding that of a pea. Occasionally, however, they project further into the anterior chamber, touch the cornea, and conceal the pupil. Generally they have a yellowish color.

Wecker, as also *Mackenzie* formerly, considers the cyst as an originally circumscribed exudation in the posterior chamber. A horseshoe-like agglutination of the posterior surface of the iris to the lens and its suspensory ligament is the cause of the confinement of the fluid which afterward pushes the iris forward as a vesicle. *Mackenzie*, in the last (IV.) edition of his book (p. 705), accedes to the explanation of *Bowman*, namely, that the disease consists of a pathological development of fluid between the stroma of the iris and the posterior epithelial layer (uvea).

V. Graefe (Arch. f. Ophthal., III., 2, pp. 412–418, and ibid., VII., 2, pp. 39–40) describes the most remarkable case of cyst in the eye. This was a dermoid cyst which, after a wound (perforation of the cornea by a sharp piece of steel), developed and increased slowly in the iris.

It appeared white and shining, was two and a half lines high and one and a half wide, projected hemispherically over the anterior surface of the iris, and also in a somewhat more flattened shape over its posterior surface, and slightly crowded the lens backward. *V. Graefe* incised the cornea with a lance knife, removed the delicate anterior envelope of the cyst, and with a Daviel's spoon emptied the contents, which consisted of *lumps of a groat-like mass* (epidermic scales) and of *short fine hairs*. The tumor returned, ruptured the cornea, emptied itself, and grew into the corneal cicatrix. The eye then remained relatively healthy, since another reproduction of the cyst was not observed.

Mackenzie and others punctured cysts of the iris through the cornea. The cysts then filled again; but, after the third or fourth puncture, disappeared without injury to the eye. When they are very large, and consequently return, an occurrence which is not uncommon after the puncture of these and other cysts, it will be best to excise its anterior wall, and occasionally we will find ourselves constrained to draw the whole cyst out, either with the blunt hook or forceps, or perhaps to cut out the entire piece of the iris in which the cyst is located.

J. W. Hulke has given (Ophthal. Hosp. Reports, VI., p. 13) a description of two new cases, and besides collected all the cases, nineteen in number, as yet known. The majority followed some injury, and *Hulke* thinks that it may be caused by a portion of the membrane of Descemet being dragged into the iris, and there giving the

impulse to a formation of a cyst, a tumor entirely foreign to the tissue of the iris, and indeed to the interior of the eye. Although this ingenious assumption might answer very well for serous cysts which are provided with a smooth or connective tissue-like envelope lined with epithelium, the dermoid cysts which occur in the iris still remain an unexplained heterotopia. Aside from their location in the iris, the small cysts in several cases appeared to have arisen in the *ciliary body*. One case (*Richard*, Gaz. Hebdomad., T. I., 1082) appeared to have been a softened myxoma. *Hulke* concludes that all cysts of the iris will finally excite destructive iridocyclitis; consequently they must be excised as early and as completely as possible.

(9.) *Simple melanoma* (pigment tumor) of the *iris*. With the exception of the frequently-occurring, not very prominent pigment spots, we sometimes find in the iris a formation of small tumors which are colored by a more or less brown pigment. They consist, as I have become convinced from a specimen of Prof. *J. Arnold*, in a circumscribed but enormous development of the stroma cells of the iris, the smaller portion unpigmented, the larger pigmented, and for the most part giving forth numerous branches which anastomose freely. They have no well-defined boundary line from the neighboring tissue, and the remaining portions of the iris are perfectly normal.

Melanoma of the iris is an entirely benign hyperplasy, similar to the pigmented warts of the skin, which they resemble also in their tendency to become transformed

into melanosarcoma much more easily than other tissues. However, they appear to be very rare.

A case is described by *V. Graefe* (Arch. f. Ophth., VII., 2, pp. 35–36). A blackish-brown tumor, slightly oval, about the size of a pea, and of a smooth surface, projected from the smaller circle (sphincter muscle) of the iris until it nearly touched the cornea. A black stripe was situated along the insertion of the ciliary muscle in the larger circle of the iris, and the intervening portion of iris was slightly elevated. *V. Graefe* draws the conclusion from these circumstances that the vegetation "without doubt proceeds from the pigment layer of the iris, and as it grows penetrates the tissue of the iris." The patient, æt. 15, and healthy, accidentally noticed the affection about a year ago. *V. Graefe* watched it from that time, and could not perceive any change. He considers it congenital. Besides, as the power of vision was in no way disturbed, "as a matter of course all interference was out of question."

Another case I myself observed. It was in a man, thirty-one years old, healthy, who came to me under the assumed name of Jacob Resch, of Kaiserslautern, on the 27th of June, 1867. He has noticed for fifteen years, a few small, brown tumors in his left eye, which did not in the least interfere with his power of vision, and did not annoy him in any other way than that they frequently (every three or four months, lately) caused hemorrhages in the anterior chamber, which however were absorbed rapidly. By examination I found the eye normal in structure, appearance, and function. In

the lower and inner section of the iris, and also in the large circle of the iris, three small, hemispherical tumors were seated near each other. They were grayish-brown in color and velvety in appearance, the two larger of an apparent diameter of about 5 mm. each, the smaller ones about 3 mm. The portion of iris between them and the margin of the pupil was pigmented of a grayish-brown, and was dull, whilst the remainder of the iris was of a bright light-brown. Between the small tumors and the insertion of the iris still lay a narrow stripe of iris tissue, which was also pigmented of a dull dark-brown. But in the lower and inner section of the iris there still appeared three dull, grayish-brown spots, not quite the size of pins' heads, and separated from each other. They were situated in the larger circle and projected slightly from the iris, and appeared altogether like the larger tumors of which we have just spoken, and must be regarded as of the same formation. We could not discover blood-vessels in any of the tumors.

I do not think, as *V. Graefe* does, that tumors of this nature proceed from the pigment layer of the iris; but can only consider them as simple hyperplasies of the pigmented and unpigmented stroma-cells of the iris.

An operative procedure I did not think indicated in the case just spoken of, as the affection had been observed during fifteen years, and had not progressed. Possibly it was congenital.

(10.) *Simple granulation tumors.* After wounds it is not at all uncommon that white, vascular, small-celled,

hyperplastic tumors should develop in the interior of the eye, proceeding from the iris, ciliary body and the choroid, and being nothing else than the ordinary traumatic granulations of other portions of the body. If the wound in the corneoscleral capsule cicatrizes rapidly, they continue to grow in the interior, producing more or less irritation. Occasionally they atrophy, very often rupture the capsule of the eye, especially the cornea, vegetate then for a time as a white, reddish, easily-bleeding, fungoid mass externally, but finally shrink and leave a phthisical globe free from irritation.

The tumors which develop rapidly after wounds all belong to this class, a fact highly serviceable in the differential diagnosis and prognosis. I saw an exquisite example of this kind after a simple amputation of staphyloma in a child. The wound did not close, but a soft, reddish tumor sprouted from it under very moderate inflammatory symptoms. It proceeded from the interior of the eye, was constricted at the scleral opening, and then spread.

I considered the fungoid growth as simple *proud flesh*, cleansed the eye, put on a compressing bandage, and found that in about six weeks the outgrowth had completely disappeared, and that the opening in the capsule of the eye had healed as usual.

Cases belonging here are described in Mackenzie's book (4th edition, p. 705, &c.), and also by other authors. To this class belong many of the tumors described as malignant, but ending in phthisis bulbi, or not returning after extirpation.

That granulation tumors in the interior of the eye are also local phenomena of constitutional affection is not at all doubtful, for instance in syphilis. The same fact is asserted by *Stellwag von Carion*, *Mackenzie*, and others, for tuberculosis and scrofulosis, according to which the miliary tubercle above described does not develop in the eye, but larger tumors of similar nature are found. Among the various products of suppurative plastic choroiditis, many, in the period of growth or atrophy, are not entirely unlike tumors, but are distinguished from them by their course.

It cannot be denied that granulation tumors arise spontaneously, but this is very rare. A case communicated by *V. Graefe* (Arch. f. Ophthal., VII., 2, p. 37) gives evidence of the insurmountable obstacles in distinguishing them from hyperplasies due to constitutional infection, particularly from syphilitic formations.

A second case of *granuloma* is described by *V. Graefe* (Arch. f. O., XII., 2, p. 231). A child, two years of age, got a yellowish outgrowth at the lower border of the iris, accompanied by inflammatory symptoms. The outgrowth increased, perforated the cornea, and overlapped as a small fleshy tumor the lower part of the juncture of cornea and sclerotic of the shrunken eyeball. The eye was extirpated. The tumor was seated in the iris and ciliary body, and not strongly defined. It consisted of lymphoid bodies, embedded in homogeneous intercellular substance, and of giant cells (myéloplaxes). The lymphoid bodies were found in abundance scattered through the neighboring tissue of the tumor.

It will not appear arrogant for me to close this short appendix with the remark that not only my own knowledge and experience of the subjects therein described are as yet very defective, but also that the material collected in medical literature bears the same character.

The progress of pathological histology, the delicate diagnostic methods, and the greater centralization of clinical material of late years, will without doubt and within a short time enlighten us in this field also.

EXPLANATION OF THE FIGURES.

(The Figures are all drawn strictly according to Nature, and none is a Diagram.)

Plate I.—Fig. A.

Ophthalmoscopic drawing of an eye affected with glioma retinæ in a child of 18 *weeks.* (Case I.) In the upper section the retina and fundus oculi are normal. *The darker yellow, circular surface represents the diffuse gliomatous degeneration of the outer retinal layers.* The inner surface of the retina is smooth, brilliant, and traversed by retinal vessels. The papilla cannot be seen. Its place is behind the central vascular arch which unites the two vascular systems, yet we must search for it superiorly and toward the left, namely, in that spot where the retinal vessels yet visible on the normal fundus would converge. The retina is lifted and conceals the papilla. A number of small white spots are seen on the yellow surface, and represent *scattered nodular glioma clusters.*

A larger, roundish glioma tumor projects beyond the diffusely degenerated retina. Its surface is dull, whitish-yellow, and covered with numerous small white spots. Vessels are only visible at its edge.

Fig. 1.

Glioma of the retina in various clusters arising in a hyperplasy of the granular layers.

a. Detached retina; its internal surfaces applied to each other.

b. Retina pushed forward, clothing the ciliary body and the posterior surface of the lens.

f. Choroid, and space between it and the detached retina.

c, d, e. Larger and smaller glioma clusters on the external surface of the retina.

Fig. 2.

Transverse section of the retina. Hyperplasy of the granules.

li. Limitans interna.

f. Nerve-fibre layer.

gl. Cellular *or* Ganglionic layer.

gr. Molecular layer.

ik. Internal granular layer.

zk. Intergranular layer.

ak. External granular layer.

le. Limitans externa.

st. Columnar layer.

a. Glioma-cells crowding toward the inner layers of the retina.

Fig. 3.

Retina with granular (gliomatous) degeneration of all its layers ($b\,b_1$), and with abrupt intumescence ($a\,a_1$) of the external granular layer (small glioma clusters).

d. Limitans interna.

c e. Darker streak marking the transition of the external granular layer into the glioma cluster.

The layers of the retina marked as in Fig. 2.

Fig. 4.

Gradual increase of the retina by thickening of the granular layers (Glioma diffusum).

a a. Nerve-fibre, ganglionic and molecular layers. The remainder as in Fig. 2.

Fig. 5.

Choroid greatly atrophied and degenerated to connective tissue.

a a. Preserved pigment epithelium.

b b. Stroma of choroid.

c. Blood-vessel.

Fig. 6.

Disseminated glioma cluster vegetating in the pigment epithelium (*p*) *of the atrophied choroid* (*ch*).

a. Accumulation of glioma-cells, lifting the epithelium.

b. Cluster of cells on the epithelium.

Fig. 7.

Glioma cluster in the pigment epithelium of the choroid (*surface preparation*).

a, b, c. Microscopical collections of cells, which spread among the epithelium (*d*) as they develop.

FIG. 8.

Atrophied iris.

u. Pigment layer.
ir. Stroma.
e. Anterior layer.

FIG. 9.

Atrophied ciliary body.

ir, ir_1. Iris.
pr, pr_1. Processus ciliares.
z z. Zonula Zinnii.
ue. Membrane investing the ciliary processes.
mc. Ciliary muscle.
c. Its circular, and
r. Its radiating fibres.

FIG. 10.

Child, æt. $2\frac{3}{4}$, *with glioma of the left orbit and metastases of glioma on the cranium* (proceeding from the diploë). The right eye (Fig. 1) had been extirpated $2\frac{1}{2}$ yrs. ago, in the first stage of retinal glioma. Plate I. Fig. A. Ophthalmoscopic drawing made $2\frac{1}{2}$ yrs. ago was taken from the left eye.

FIG. 11.

External appearance of the cranium of the same child after death, the skin having been removed.
k. Orbital glioma.

a, c, g, f. The metastatic glioma tumors of the cranium covered by the periosteum.

Fig. 12.

The cranium of the same case, opened.

a, g, c. Gliomatous tumors bounded externally by the periosteum, internally by the uninjured dura mater. The substance of the cranial bone destroyed.

d. Left orbit crowded backward.

e. Apex of the same, through which the orbital glioma is beginning to invade the cranial cavity.

h, i. Displacement internally of the anterior and middle cranial fossæ, caused by the pressure of the metastatic gliomatous tumors in the bones of the cranium.

Fig. 13.

Longitudinal section through the orbital tumor of the same case.

bk. Base (or superior root) of the lesser wing of the sphenoid.

n o. Nerv. opt.

r i. M. rect. inf.

r s. M. rect. sup.

l p s. M. levator palp. sup.

de k. Deficiency of bone in the roof of the orbit.

m sch. Sheath of muscle.

d m. Dura mater.

p e. Periosteum.

k o o. Supraorbital ridge.

t gl kn. Temporal glioma.

scl. Sclerotic.

gl. Gliomatous tissue in the eye.

gl e. External glioma.

ch. Choroid.

re. Retina completely degenerated.

FIG. 14.

Glioma of the retina, with extension to the optic nerve and choroid.

o. Nerv. opticus.

n. Degenerated retina.

v. Vitreous, preserved.

e, e. Space between retina and choroid filled with a fluid resembling whey.

a, a. Intumescence (gliomatous degeneration) of the choroid.

FIG. 15.

Collection of glioma cells (a) on the internal surface of the choroid.

a. Glioma cluster

p,p. Pigmented layer, raised.

gl. Structureless membrane.

c. Choriocapillaris.

v. Tunica vasculosa Halleri, inflamed and atrophying to connective tissue.

FIG. 16.

Glioma without rupture; the eyeball completely filled.

ch. Choroid.

m. Ciliary muscle.

c. Calcified glioma clusters.

Co c. Ciliary body.

FIG. 17.

Elements of the outer tumor (*k*) *of the case from which Fig.* 18 *is taken.*

a. Pigment.

b. Larger round cells.

c. Fine nuclei, disseminated.

d. Free fat-granules.

d'. Heap of fat-granules.

d''. Glioma-cells having undergone fatty degeneration.

FIG. 18.

Retinal glioma with extraocular glioma (*rupture*).

a. Inner, soft, grayish-white, vascular mass.

b. Choroid.

c. Sclerotic.

d. Posterior, yellowish, granular mass.

e. Optic nerve.

f. Iris.

g. Envelope of connective tissue.

h. Outer, gray, and transparent portion.

k. Inner, grayish-yellow, marrowy mass of the tumor, external to the globe.

l. Yellow clusters in the glioma.

m. Gray gliomatous mass between the choroid and sclerotic.

FIG. 19.

Extension of the glioma (*ab*) *to the sclerotic* (*scl.*). Specimen with acetic acid.

FIG. 20.

Glioma completely filling and enlarging the eyeball; calcification and extraocular tumor.

le. Crystalline lens.

no. Optic nerve.

ch. Choroid.

ca. Lime.

gg_1. Yellow line running transversely through the pseudoplasma, as line of demarcation of a rather extensive surface.

FIG. 21.

Calcareous glioma clusters (*ca*) *in the choroid, which itself is degenerated to connective tissue* (*str*).

p. Pigment layer of the choroid.

v. Larger blood-vessels.

gl gl.[1] Encroaching glioma-cells.

str. Stroma of the choroid.

FIG. 22.

Meridional section of an eye gliomatously degenerated and ruptured through the cornea.

Scl. Sclerotic.

Ch. Choroid.

le. Crystalline lens.

Co. Cornea.

aa. Hemorrhagic spots.

b. Calcareous spots.

m. Protruding mass.

FIG. 23.

Invasion of the choroid (*str*), *which is degenerated to connective tissue by the glioma* (*gl, gli*).

FIG. 24.

Spinal cord (*m*) *with glioma* (*tu*).

FIG. 25.

Glioma with rupture of the cornea. Intra and extrascleral development of homologous glioma tissue.

co. Remains of cornea.

ch. Atrophied remainder of choroid.

h h_1. Spots of dark red discoloration from hemorrhages.

m m_1. Denser layer of glioma grown into the sclerotic.

FIG. 26.

Anterior view of an eye affected with melanosarcoma of the choroid. A sarcoma cluster (*tu*) *pierces the iris at its periphery and pushes it toward the centre of the globe.* On the tumor two vascular branches.

FIG. 27.

Side view of the same case. With oblique light, the sarcomatous tumor (tu_1) proceeding from the ciliary body is brought to view.

FIG. 28.

Meridional section of the same eye after extirpation. Aside from the tumors (*tu* and tu_1) described in the two foregoing Figures, there is still a third (tu_2) in the posterior portion of the choroid, and a row of smaller ones (tu_3), and three pigment spots (p) in the choroid.

re. The retina covers and is loosely connected to the tumors, and also lines the choroid, as in the normal state.

FIG. 29.

Equatorial transverse section through the same tumor.

Scl. Sclerotic.

ch. Choroid.

re. Retina.

tu. Black tumor with whitish-yellow spots.

FIG. 30.

Meridional section of the same tumor.

ir. Iris.

co. Cornea.

le. Lens.

FIG. 31.

Forms and manner of collection of the cells in the same tumor.

a–d. Unpigmented cells found in the stroma. Without nucleus, or containing one or more nuclei.

f–g. Similar cells, pigmented.

i. Highly pigmented cells lying close together.

l l_1. Sarcoma tissue; round, oval, and fusiform cells, pigmented and unpigmented, and lying in contact.

k. Young cells embedded in a protoplasma common to all.

FIG. 32.

Melanosarcoma of the same case extending from the choroid to the ciliary body.

scl. Sclerotic.

co. Cornea.

ir. Iris.

m. c. Ciliary muscle.

sarc. Sarcomatous mass wedging in between the ciliary muscle and the sclerotic, and between the fibres of the ciliary muscle.

FIGS. 33, 34, and 35.

Melanosarcoma of the choroid and the ciliary body.

Fig. 33. *Meridional section.*

sa. Sarcomatous tumor, with black masses.

re. Retina detached in the shape of a funnel, and covering the sarcoma.

Fig. 34. *Equatorial transverse section through the middle of the tumor*, showing its intimate connection with the sclerotic and the striped division of the black masses.

Fig. 35. *Anterior view of the eye before it was laid open.*

sa_1. Small episcleral melano-sarcomata.

Fig. 36.

Choroid in a state of transition to a pseudoplasma.

ab. Normal choroid.

bcd. Proliferous enlargement of the outer layers tumefying to a sarcoma.

i i. Larger choroidal vessels.

g h. Choriocapillaris and pigmentary epithelial layer.

e. Pigment cells invading the choriocapillaris.

Fig. 37.

Melanotic sarcoma of the choroid. The ciliary body, including the ciliary muscle, is entirely replaced by pseudoplasma which is beginning to encroach on the iris.

Fig. 38.

Melanosarcoma infesting the sclerotic.

ab. Inner (choroidal) sarcoma.

c d e f. Passages of sarcoma tissue in the otherwise normal sclerotic (scl).

g g_1. Outer (episcleral) sarcoma (*Fig.* 35, sa_1).

Fig. 39.

Melanosarcoma infesting the sclerotic.

a b. Choroidal sarcoma.

c d. Unpigmented and pigmented sarcoma-cells between the fibres of the sclerotic (scl).

FIGS. 40 and 41.

Melanotic choroidal sarcoma with secondary episcleral tumors (*ex*).

Fig. 40.

sa. Sarcoma.

re. Detached retina.

r. Space between the detached retina and normal choroid.

Fig. 41. Segment from the other half of the eyeball.

sa_1. Inner (choroidal) sarcoma.

ex. Episcleral secondary tumor.

FIG. 42.

Unpigmented (*a–f*) *and pigmented* (*g–o*) *fusiform cells with one or more nuclei*, showing the structure and manner of multiplication of the cells in a sarcoma of spindle-shaped elements.

FIG. 43.

Gliosarcoma. Equatorial section. Rupture (*ru*) and external proliferation (*t e*) of the *glioma* (*gl*).

sa. Sarcoma.

scl. Sclerotic.

FIG. 44.

Gliosarcoma. Embryonic cells, round and fusiform (*a*) sarcoma-cells. Recent and older pigmented cells.

b. Cells containing blood-corpuscles which have been transformed into balls of pigment.

FIG. 45.

Gliosarcoma. Meridional section of the same eye, showing the sarcomatous vegetation (*sa e*).

le. Lens.

n. o. Degenerated optic nerve.

FIG. 46.

Elements of the gliomatous portion of the gliosarcoma. Small, round cells undergoing fatty degeneration, and of the size of retinal granules.

FIG. 47.

Passage of these glioma-cells through the sclerotic at the place of perforation.

FIG. 48.

Elements of the sarcomatous portion of the gliosarcoma. The cells are larger, have distinct nuclei, brilliant nucleoli, well-defined protoplasma, and are embedded in a homogeneous intercellular substance.

FIG. 49.

Melanosarcoma with rupture through the sclerotic.

co. Cornea.

scl. Sclerotic.

tu e. Tumor externus.

Figs. 50 and 51.

White choroidal sarcoma of fusiform cells.

Fig. 50. *Meridional section of the eyeball.* The retina (*re*) covers the white tumor (tu).

ch. Normal.

ch_1. Slightly thickened choroid.

Fig 51. *Section of the tumor* (tu).

re. Retina clothing it.

ch. Slightly thickened choroid at the periphery of the growth.

p. Slight collection of pigment in the superficial layer of the tumor.

m. Thin layer of pigment between sclerotic and pseudoplasma.

Figs. 52 and 53.

Small fusiform cells from the interior of the same tumor.

Fig. 52. Cells parallel and dense.

Fig. 53. Cells in irregular arrangement, and separated by abundant intercellular substance.

Fig. 54.

Primary (*granulation*) *stage of a white, fusiform-celled sarcoma of the choroid.* The boundary of the tumor of the same case.

An abundant infiltration of lymphoid bodies (*a*) between the choriocapillaris and Haller's vascular layer

rises at a well-marked boundary (a_1) in the form of a tumor from the normal choroidal tissue.

FIG. 55.

White, fusiform-celled sarcoma. The same case. Embryonic (granulation) cells (*a*) of the preceding figure in a state of transition (*b*) to fusiform cells (*c*).

FIG. 56.

Pigmented and unpigmented granulation-cells in the formative layer of a fusiform-celled sarcoma of the choroid. Same case.

FIG. 57.

White, vascular sarcoma of the choroid. The meridional section of the eyeball exposes the free surface of the tumor (tu), traversed by blood-vessels (va) and dotted with small hemorrhagic spots.

FIG. 58.

White, vascular sarcoma of the choroid. Same case. *Meridional section through the middle of the tumor* (*tu*) *and the optic nerve.*

re. Retina, ruptured and covered by the tumor.

ch. Neighboring choroid.

FIG. 59.

Section through the boundary line of the white, vascular sarcoma (tu). This is situated in the tissue of the choroid.

ch_1. Lamina fusca on its outer,

pi. Pigment layer on its inner surface.

va. Large blood-vessel of the tumor.

ge. Haller's vascular layer between the tumor and optic nerve. Enormous dilatation of the choroidal vessels.

ge_1. Haller's vascular layer between the tumor and the equator of the globe. Vessels normal and collapsed.

re. Retina, normal near the tumor, but thickened as it passes over the latter, and changed into an outer granular (*gr*) and an inner fibrous (*fi*) layer.

Fig. 60.

White, vascular sarcoma of the choroid with rupture of the retina. Same case. Meridional section through the middle of the tumor.

tu. Section of the tumor previous to rupture through the choroid (ch ch_1) and the retina (re).

tu_1. The section of the tumor lying laterally on the retina, and proliferating into the vitreous.

k. Imaginary boundary of the tumor, in order to exhibit its size.

l. Transverse sections of vessels with cell-mantle encircling them.

h. Striped fibrous layer covering the tumor on the surface facing the vitreous.

hae. Hemorrhagic spots in the tumor.

Fig. 61.

Young elements of the tumor at its choroidal boundary.

A. In the fibrous intercellular substance lymphoid

bodies and typical sarcoma-cells (a) are deposited around a capillary.

B, *b*. Pigmented stroma-cells of the choroid.

d. Lymphoid (granulation) cells.

e. Sarcoma-cell, with brilliant nucleolus.

c. Two nuclei in a protoplasma mantle common to both.

FIG. 62.

Blood-vessel in the tumor surrounded by a thick envelope of sarcoma-cells.

aa. Transverse section of the coats of the vessel with circular muscle fibres (*m*).

i. Internal coat.

e. Endothelium, indistinct.

c. External coat, full of lymphoid cells (*l*).

r. Intercellular substance, reticulated by sarcoma-cells falling out. In the lumen of the blood-vessel, blood-globules well preserved.

FIG. 63.

Young elements of vascular sarcoma. Lymphoid bodies (*l*) and larger sarcoma nuclei (*n*) are situated around a capillary (*v*) in a protoplasma common to all; at *c*, two such nuclei surrounded by protoplasma, isolated at *d*, at the edge of the specimen. The nuclei become larger and longer, and at *sp* take the spindle shape. From a–a_1 a row of lymphoid bodies as the continuation of a capillary vessel.

FIG. 64.

Ramification of blood-vessels in vascular sarcoma. The lumen of the extraordinarily numerous vessels is, in part, open (*b*), and can be followed into the larger trunk (which still contains some blood-globules), and, in part, is invisible (*f*). The collapsed walls of the blood-vessels then form a fibrous network which, full of nuclei, encloses the sarcoma-cells, and is apt to be mistaken for areolar carcinoma.

FIG. 65.

Longitudinal section through a branch (*nc*) *of a vessel in vascular sarcoma.* Around the thin vascular tube a thick cylinder of sarcoma-cells has accumulated. It also envelops the branches. Through the cells there wind very fine empty canals (*c*), probably a capillary network.

FIG. 66.

Transverse section of such a blood-vessel, in which we see how numerous the fine terminal canals (*c*) are.

FIG. 67.

Inflammatory fibromatous choroidal sarcoma. Meridional section.

tu. Choroidal tumor.

ei. Abscess.

p. Its dense limiting (pyogenetic) membrane.

k. Conical staphyloma of the sclerotic.

ch. Choroid as matrix of the tumor vegetating into the vitreous.

ch_1. Outer layer of the same enveloping the abscess.

re. Detached retina.

v. Ciliary processes.

Figs. 68 and 69.

Detachment of the ciliary body and neighboring choroid from the sclerotic.

Fig. 68. *Anterior view of the living eye.* The detached portions appear as three grayish-brown lumps (tu) behind the iris, and in the pupillary field. Aphakial eye.

Fig. 69. *Meridional section of the extirpated eye;* both halves still attached to each other.

ir. Iris.

c. c. Ciliary body.

ch. Choroid.

re. Retina, everywhere applied to the choroid, except in one place of limited extent, where it became detached as the eye was laid open.

scl. Thickened sclerotic.

r. r. Annular space filled with serum between sclerotic and choroid (*s. ch*).

Fig. 70.

Diagram to demonstrate the method of determining by means of the ophthalmoscope the thickness of tumors in the fundus of the eye. For explanation, see pp. 104, 105, and 106.

Fig. A.

H Knapp ad nat del

Carlsruhe Chr Fr Müller'sche lith Anstalt

Fig 1 $\frac{4}{1}$

Fig. 2. $\frac{250}{1}$



Fig. 3. $\frac{200}{1}$

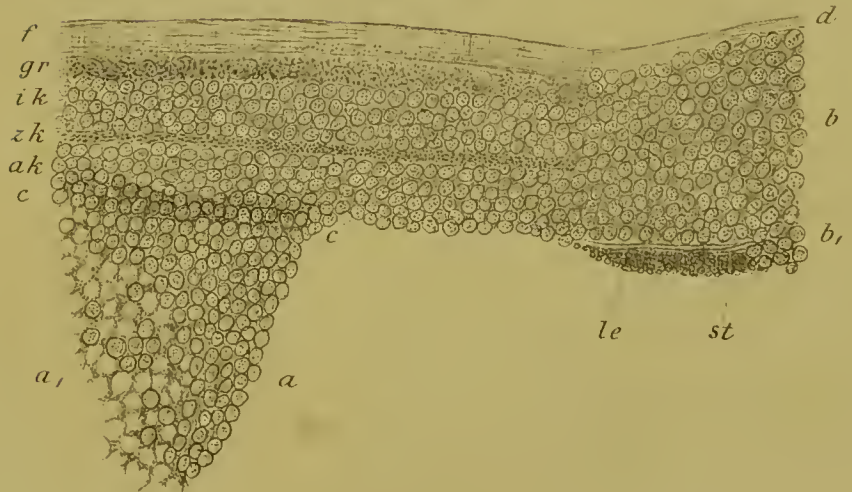

Fig. 4. $\frac{50}{1}$

H Knapp ad nat. del

Carlsruhe. Chr Fr Müller'sche Lith Anst

Fig. 5. $\frac{300}{1}$



Fig. 6. $\frac{300}{1}$

Fig. 7. $\frac{300}{1}$

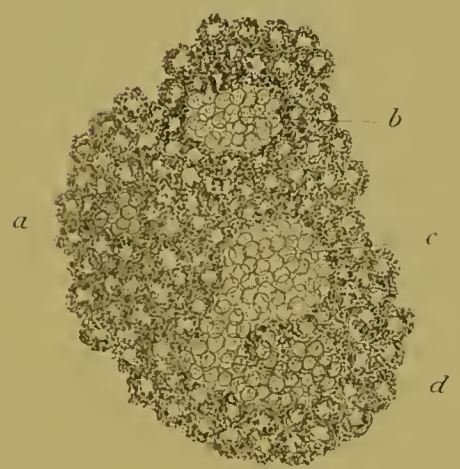

Fig. 9 $\frac{250}{1}$

Fig. 8. $\frac{300}{1}$

H. Knapp ad nat del

Carlsruhe Chr Fr Müller'sche Lith Anst

Fig. 10. Tab. IV.

C P Schmitt ad. nat del.

Carlsruhe. Chr Fr Muller'sche Lith Anst

Tab. V.

Fig. 11.

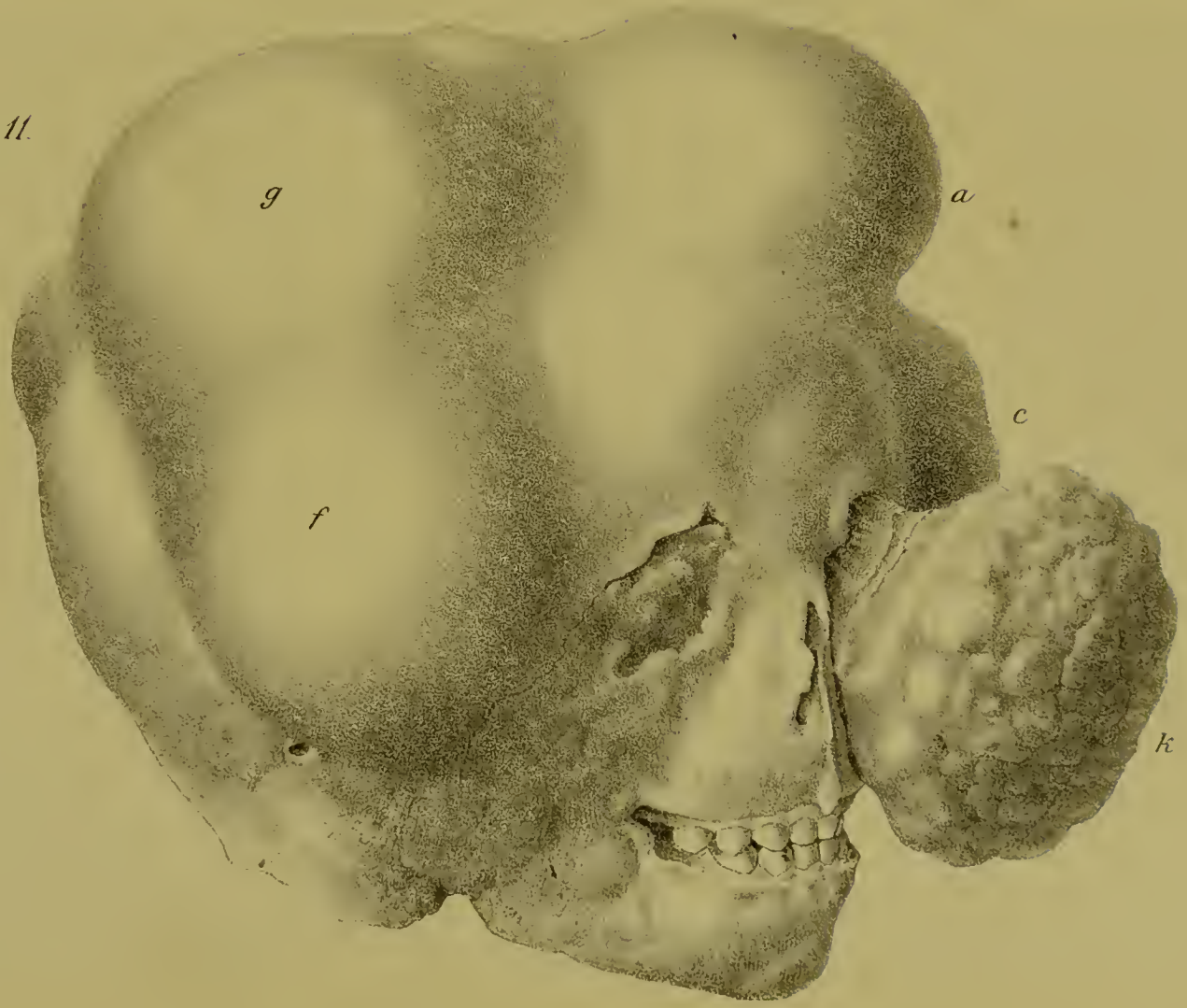

F. Veith ad nat. del.

Fig. 12.

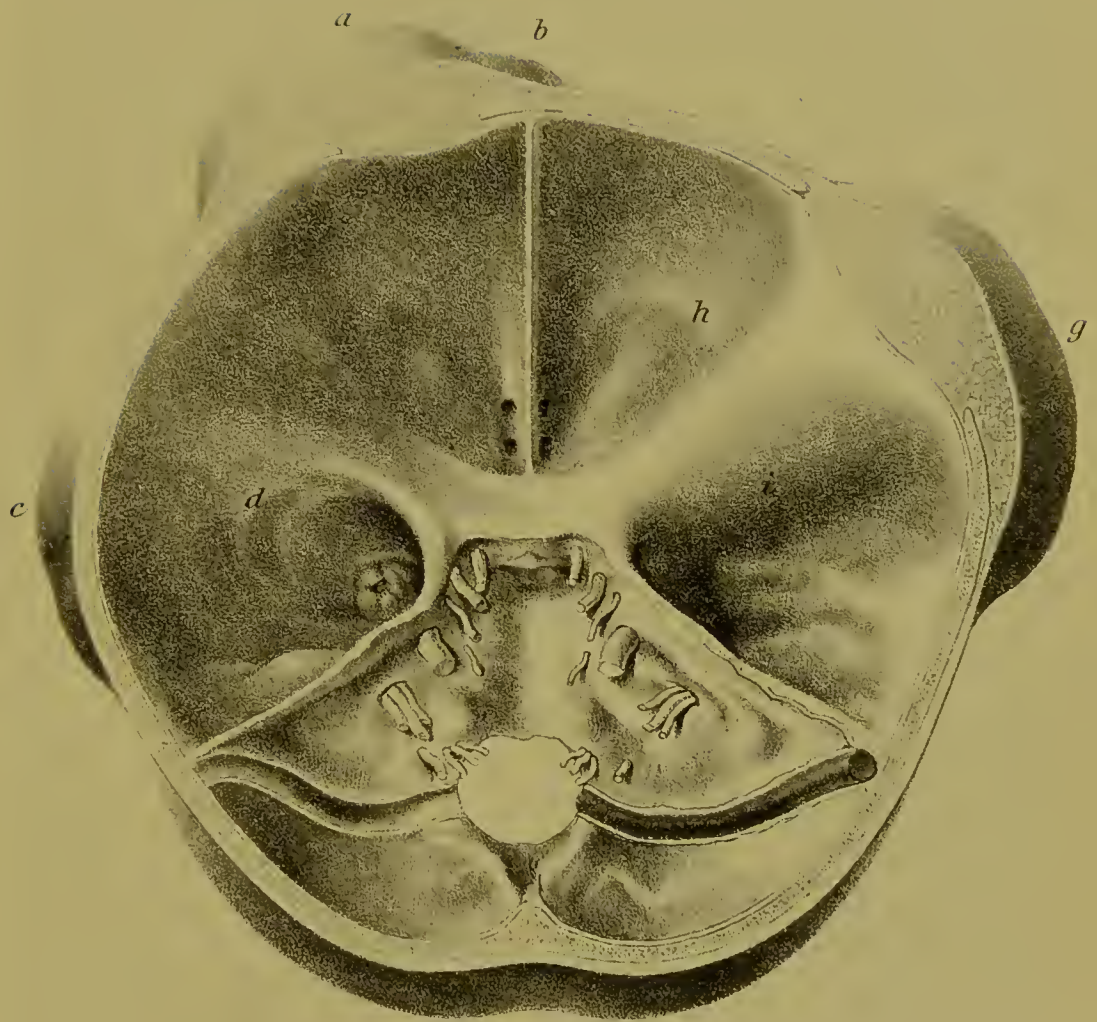

F Veith ad nat del

Carlsruhe. Chr Fr Müller'sche Lith Anst

Fig. 13. $\frac{4}{1}$

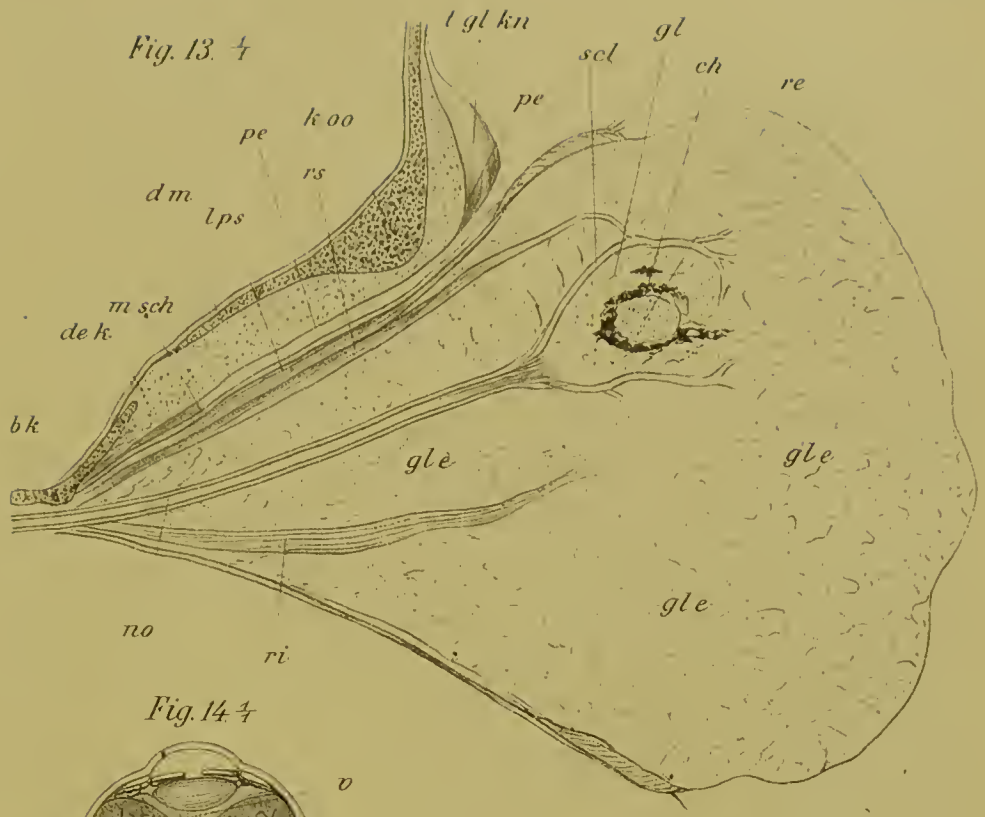

Fig. 14. $\frac{4}{1}$

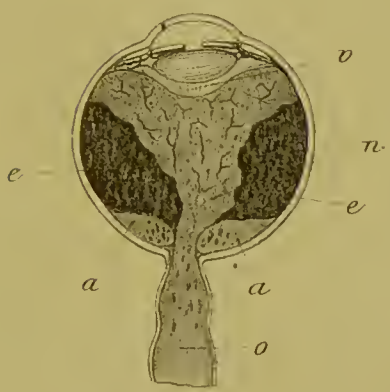

Fig. 15. $\frac{250}{1}$

Fig. 16. $\frac{4}{1}$

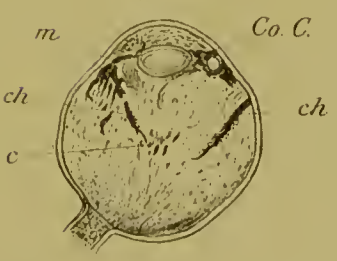

H Knapp ad.nat.del

Carlsruhe. Chr Fr Müller'sche Lith Anst

Fig. 17. $\frac{300}{1}$

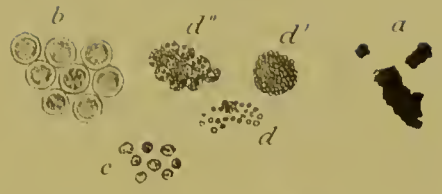

Fig. 18. $\frac{3}{1}$

Fig. 19. $\frac{300}{1}$



Fig. 21. $\frac{250}{1}$

Fig. 20. $\frac{1}{1}$

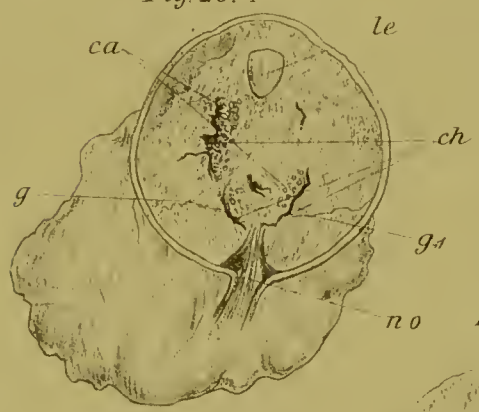

Fig. 22. $\frac{1}{1}$

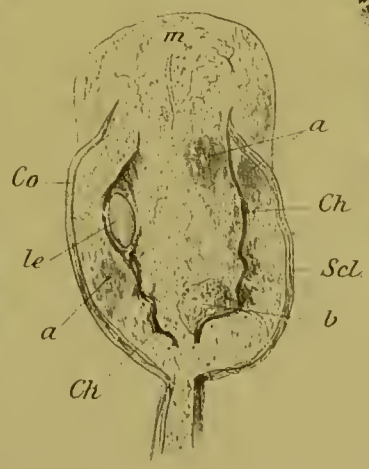

Fig. 23. $\frac{270}{1}$

H. Knapp ad nat del.

Carlsruhe. Chr Fr Müllersche Lith. Anst



H. Knapp ad nat. del

Carlsruhe. Chr. Fr. Müller'sche Lith. Anst.

Fig. 33. 4/1

Fig 35 4/1

Fig. 34 4/1

Fig. 36.

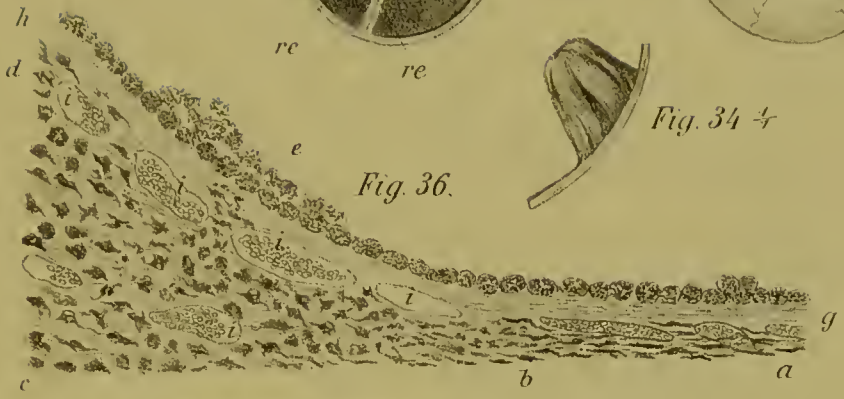

Fig. 37. 30/1

Fig. 38. 50/1



H. Knapp ad. nat. del.

Carlsruhe. Chr. Fr. Müller'sche Lith. Anst.

Fig. 39. $\frac{300}{1}$

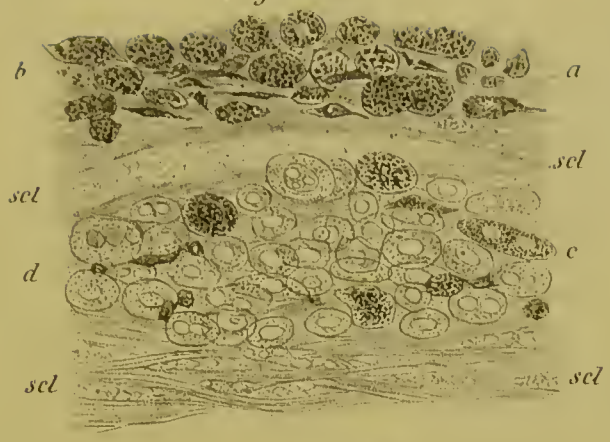

Fig. 40. $\frac{4}{1}$

Fig. 41. $\frac{4}{1}$

Fig. 42. $\frac{300}{1}$

Fig. 44. $\frac{300}{1}$

Fig. 43. $\frac{4}{1}$

Fig. 45. $\frac{4}{1}$

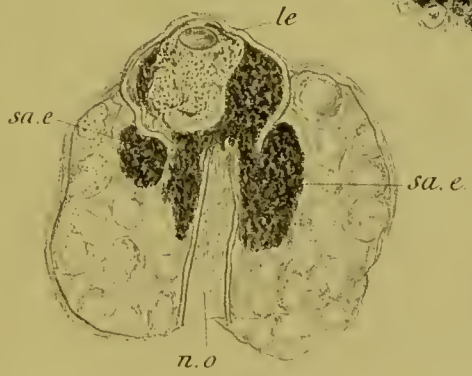

Fig. 46. $\frac{250}{1}$



Fig. 47. $\frac{250}{1}$

Fig. 48. $\frac{250}{1}$

H Knapp ad nat del

Carlsruhe. Chr Fr Müller'sche Lith. Anst.

Fig. 49 $\frac{4}{1}$

Fig. 50. $\frac{4}{1}$

Fig. 51. $\frac{4}{1}$

Fig. 52 $\frac{300}{1}$

Fig. 53. $\frac{300}{1}$

Fig. 54. $\frac{300}{1}$

Fig. 55. $\frac{300}{1}$

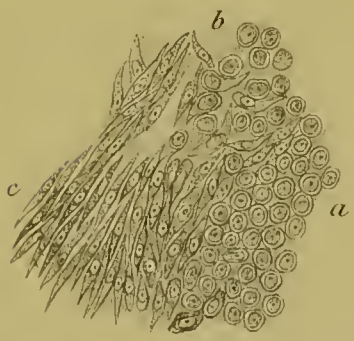

Fig. 56. $\frac{330}{1}$



Fig. 57. $\frac{4}{1}$

H Knapp ad.nat.del.

Carlsruhe. Chr. Fr. Müller'sche Lith. Anst.

Fig. 58. 4

Fig. 59. 20

H. Knapp ad. nat. del

Carlsruhe. Chr. Fr. Müller'sche Lith. Anst.

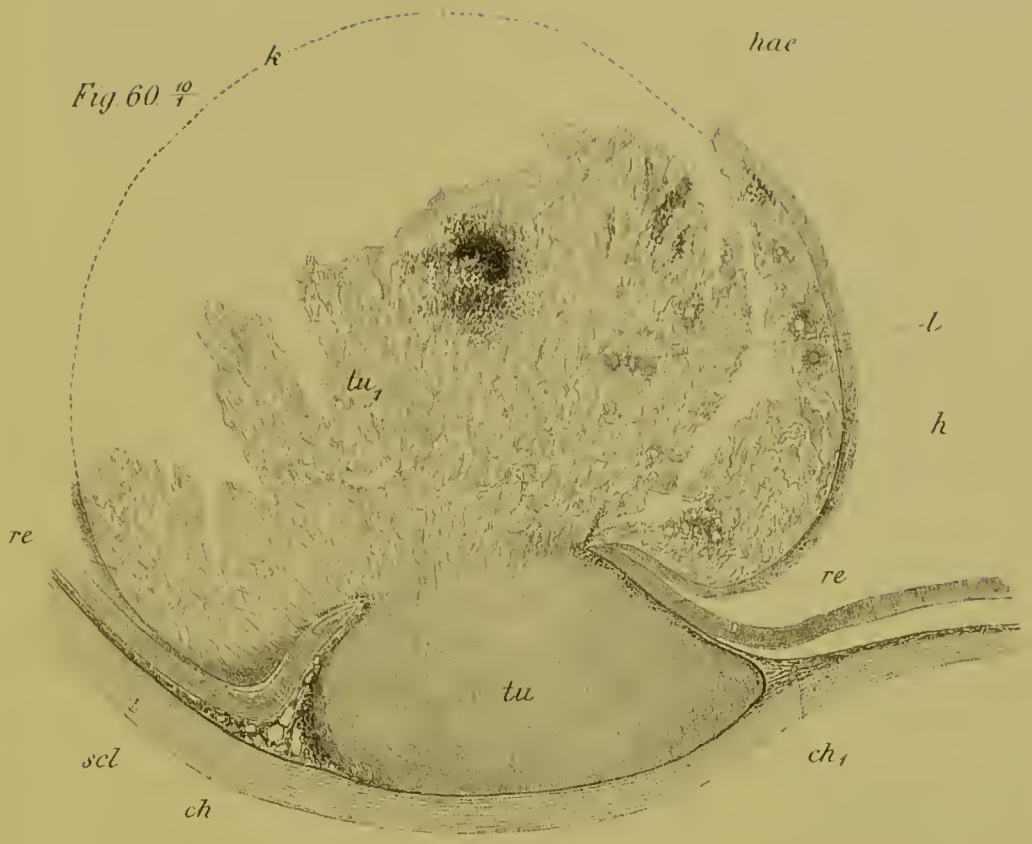

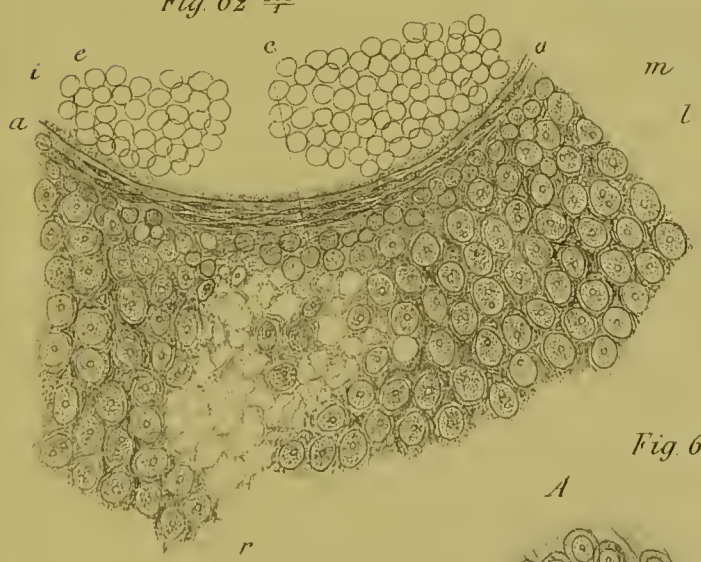

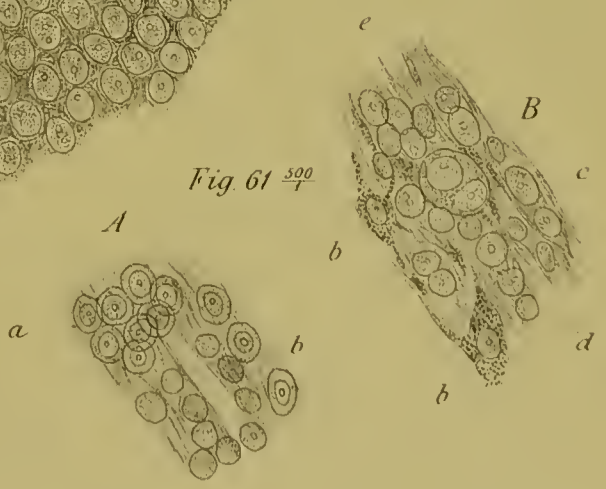

H Knapp ad nat del

Carlsruhe. Chr Fr Müller'sche Lith Anst

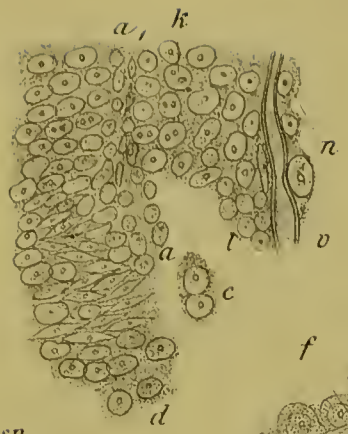

Fig. 63 $\frac{400}{1}$

Fig. 64 $\frac{330}{1}$

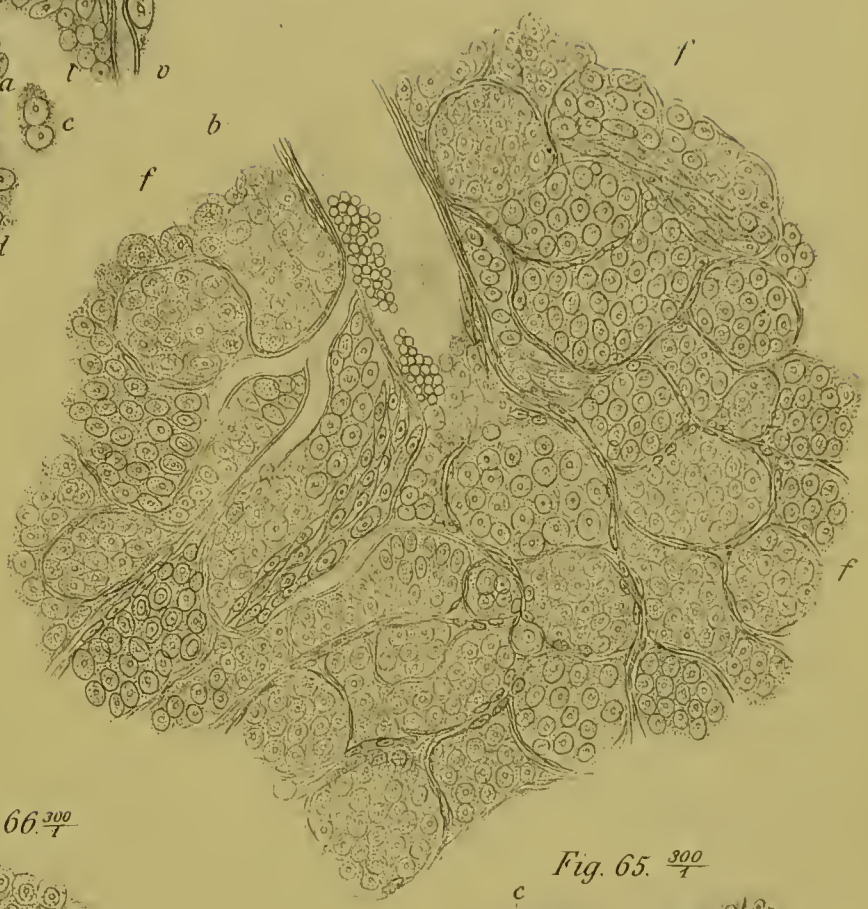

Fig. 66. $\frac{300}{1}$

Fig. 65. $\frac{300}{1}$

H. Knapp ad nat del

Carlsruhe. Chr Fr Müller'sche Lith Anst

Fig. 67. $\frac{4}{1}$

Fig. 68.

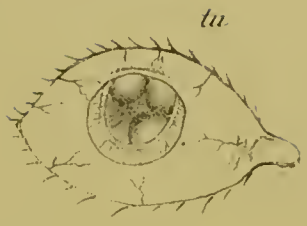

Fig. 69. $\frac{4}{1}$

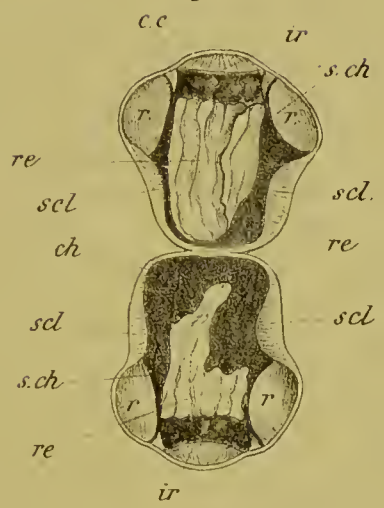

Fig. 70.

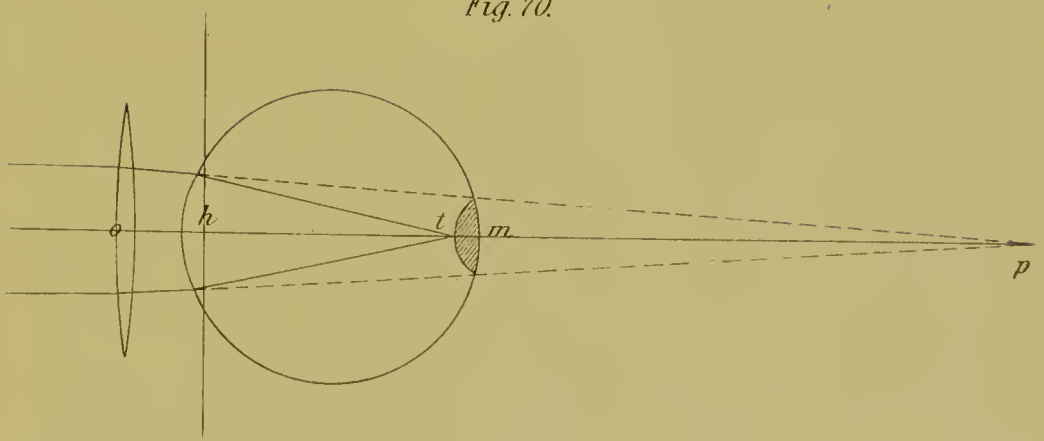

H.Knapp ad.nat del

Carlsruhe Chr Fr Müller'sche Lith Anst